

Hardin Library-University of Iowa

IAUIOW-NUI ILLiad TN: 1370479

ILL Number: 41807695



Borrower: ILUADA-1

Patron: Petrosky, Ron;

Journal Title: Compendium of continuing
education in dentistry (Jamesburg, N.J. : 1995)
ISSN: 1548-8578

Volume: 28 **Issue:** 2
Month/Year: 2007 **Pages:** 92-9; quiz 100-1

Article Author: Shatkin TE;Shatkin
S;Oppenheimer BD;Oppenheimer AJ

Article Title: Mini dental implants for long-term
fixed and removable prost

Imprint:

Call #:

Location:

PDF

Charge
Maxcost: \$15.00

Shipping Address:
American Dental Association
Department of Library Services
211 East Chicago Avenue
Chicago, IL 60611-2637

Fax: 312-440-2774
Phone: 312-440-2653
email: library@ada.org
EMAIL: LIBRARY@ADA.ORG

NOTES:We are a GMR-RL EFTS
PARTICIPANT. GMRRG member for
reciprocal borrowing & lending

Mini Dental Implants for Long-Term Fixed and Removable Prosthetics: A Retrospective Analysis of 2514 Implants Placed Over a Five-Year Period

Abstract

Over the past decade, endosseous implants of increasingly smaller diameters have been introduced into the field of dentistry. Small diameter implants (SDIs) are generally 2.75 mm to 3.3 mm in diameter. They are frequently used in cases of limited alveolar anatomy. Mini dental implants (MDIs) are smaller than their SDI counterparts, with diameters ranging from 1.8 mm to 2.4 mm. They are suitable for long-term use—a task for which the device was approved by the Food and Drug Administration. The following study describes the authors' experience with MDIs under this indication. Over a 5-year period, 2514 MDIs were placed in 531 patients. The mean duration of follow-up was 2.9 years. The implants supported fixed (1278) and removable prostheses (1236), with nearly equal placement in the mandible and maxilla (1256 and 1258, respectively). The overall implant survival was 94.2%. Based on a Cox proportional hazards model, statistically significant predictors of failure include use in removable prostheses (hazard ratio = 4.28), the posterior maxilla (3.37), atrophic bone (3.32), and cigarette smokers (2.28). Implant failures (145) were attributed to mobility with or without suppuration (19% vs 81%, respectively). The mean failure time for these implants was approximately 6.4 months (193 ± 42 days). This temporally correlates with the osseointegration period. A learning curve was established for this procedure, and implant survival improved with placement experience. Based on these results, the authors have devised treatment guidelines for the use of MDIs in long-term fixed and removable prostheses. MDIs are not a panacea; however, proper training enables the general dentist to successfully implement MDIs into clinical practice.

Learning Objectives

After reading this article, the reader should be able to:

- discuss the development of implantology including the introduction of mini dental implants to the field.
- explain the advantages and disadvantages of different types of implants and surgical techniques.
- describe guidelines for the successful placement of mini dental implants by the general dentist.

Since Branemark first related the principle of osseointegration to the field of dentistry,¹ dental implantology has become a rapidly evolving and innovative field.² In 2004, the American Dental Association Council on Scientific Affairs cited dental implants as the “first generation of tissue engineering devices that will affect the

dental profession.”³ Accordingly, a wide variety of implant materials, shapes, sizes, and surface treatments have been devised.⁴ Patients also have become aware of the potential of dental implants; prostheses that function immediately are often desired.⁵

To meet this demand, implants of increasingly smaller diameters have

Todd E Shatkin, DDS
Private Practice, Aesthetic Associates Centre
Buffalo, New York

Samuel Shatkin, DDS, MD
Associate Professor
Department of Surgery
State University of New York at Buffalo
Buffalo, New York

Private Practice, Aesthetic Associates Centre
Buffalo, New York

Benjamin D Oppenheimer, DDS
Private Practice, Aesthetic Associates Centre
Buffalo, New York

Adam J Oppenheimer, MD
Intern
Department of Surgery Division of Plastic
Surgery
University of Michigan
Ann Arbor, Michigan

been devised, and single-stage procedures^{6,7} with immediate functional loading^{8,9} have become available.

Small diameter implants (SDIs) are the preferred treatment modality in cases of limited anatomical geography. These implants range from 2.75 mm to 3.3 mm in width and 8.0 mm to 15 mm in length.¹⁰ Specifically, SDIs are indicated for the replacement of teeth with small cervical diameters and in cases of reduced interradicular bone.¹⁰ They also have been shown to be a viable alternative to bone augmentation when poor alveolar ridge width is encountered¹¹ and in cases of restricted mesiodistal anatomy.¹²

Biomechanical studies support SDI efficacy. Block and colleagues correlated implant dimensions with the pullout force required for extraction.¹³ After 15 weeks of integration, they found that the pullout force correlated strongly with implant length but not diameter. A second study of similar design compared the pullout resistance of SDI and standard implants in cadaveric mandibles.¹⁴ This study failed to detect a statistically significant impact of implant diameter, providing further support for congruency between SDIs and standard implants.

Survival analyses of SDIs have been exceptional, with rates between 88.5% and 96% depending on methodology and survival criteria.^{15,16} In 2 retrospective analyses of 2.9 mm implants, Vigolo and colleagues demonstrated survival rates of 92% and 94.2%, respectively.^{17,18}

Based on this *in vivo* and *in vitro* success, the mini dental implant (MDI) seems a logical successor. Smaller than their SDI counterparts, MDIs have diameters ranging from 1.8 mm to 2.4 mm. MDIs were initially designed for temporary prosthetic stabilization during the healing phase of standard implants.¹⁹ Reproducible success in this indication^{20,21} has led to expanded uses in orthodontic anchorage,^{22,23} for the temporary fixation of transplanted teeth,²⁴ in periodontal therapy,^{25,26} and more recently, for long-term fixed and removable prosthetics.²⁷⁻³⁰ While the Sendax MDI^a was the first MDI to gain approval from the Food and Drug Administration for long-term applications, several other MDI systems are available including Hi-Tec Implants^b, Monorail MTI Transitional Implants^c, and NobelDirect 3.0 implants^d.

The titanium-aluminum-vanadium alloy of the Sendax MDI affords it the increased strength required for these long-term applications. A recent study by Kanie and colleagues compared the biomechanical properties of the mini transitional implant (MTI) with those of the Sendax MDI.³¹ Based on a flexural test (a fixed horizontal load was applied to the implant head), the authors determined that the MDI was 2.3 times stronger than the MTI. They concluded that the MTI is suitable for transitional use accordant with its design, while the MDI should be used if "intensity is a priority."³¹

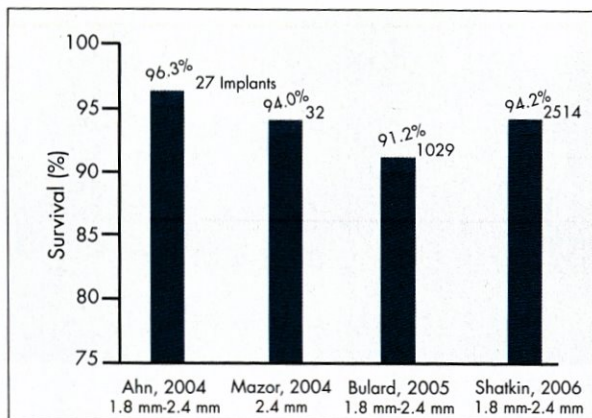


Figure 1—Mini dental implant (MDI) study comparisons.

Clinical analyses of MDIs are relatively scarce in the literature (Figure 1). However, immediate loading of MDIs for long-term lower denture stabilization has been reported.²⁸⁻³⁰ Under this indication, Ahn and colleagues showed that 26 of 27 MDIs were stable at 21 weeks of follow-up.²⁸ A study by Mazor and colleagues represents another retrospective MDI survival analysis.²⁹ They followed 32 Hi-Tec mini implants (2.4 mm in diameter) over a 3-year period. These implants were used for the stabilization of full lower dentures with immediate loading. A survival rate of 94% was reported, with a single implant mobile at 3 months. A multicenter analysis by Bulard and Vance found similar results with MDIs: implant success rates of approximately 91% were noted.³⁰

The authors have previously presented their experience with MDI placement for long-term prosthetic stabilization.^{32,33} Since that time, the authors have continued to place MDIs based on these principles. This article describes a retrospective analysis of 2514 MDIs placed in 531 patients over a 5-year period. Based on the authors' results, they have devised guidelines for the successful placement of MDIs by the general dentist.

Materials and Methods

From January 10, 2000 to July 20, 2005, 2514 implants were placed in 531 patients. All patients received treatment in a private office setting. The primary author was responsible for the placement of 2493 implants, while the tertiary author placed an additional 21 implants.

Inclusion criteria were broad, and most patients were selected for MDI placement based on subjective complaints. These included difficulty wearing a lower or upper denture, concern about denture reliability in social settings, and the desire to feel more confident. Objective indications for MDI placement included denture stabilization on a thin alveolar ridge, a strong gag reflex, a large torus palatinus or mandibularis precluding prosthetic seating, single missing teeth, and partial or complete edentulism.

Exclusion criteria were minimal. Severely atrophic bone and active intraoral infection were the only consis-

^a IMTEC, Ardmore, OK 73403; www.imtec.com

^b Hi-Tec Implants, Herzlia, Israel; www.hitec-implants.com

^c Dentatus, New York, NY 10016; www.dentatus.com

^d Nobel Biocare, Yorba Linda, CA 92887; www.nobelbiocare.com

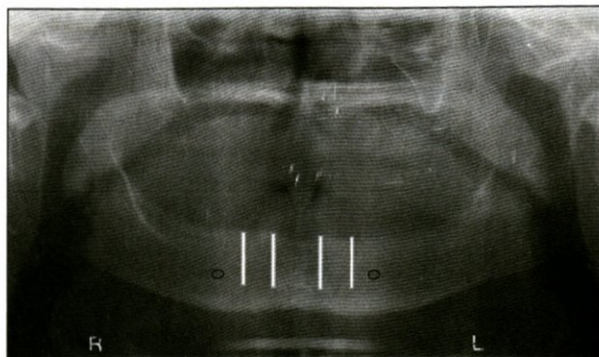


Figure 2—Panoramic x-ray with prospective implant locations and mental foramina marked.

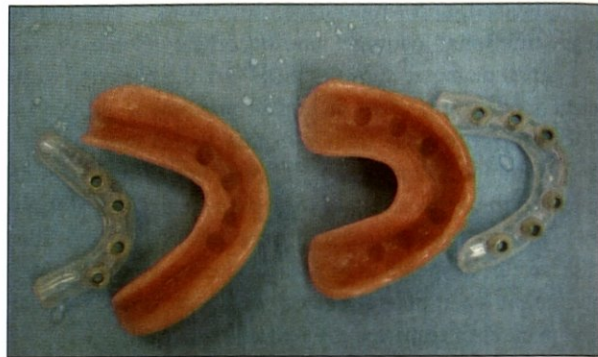


Figure 3—Surgical stents with upper palateless denture and lower denture.

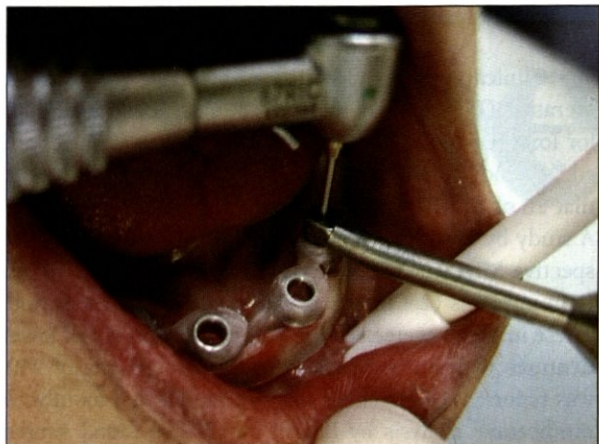


Figure 4—Surgical stent in place with pilot drill guide and surgical handpiece.

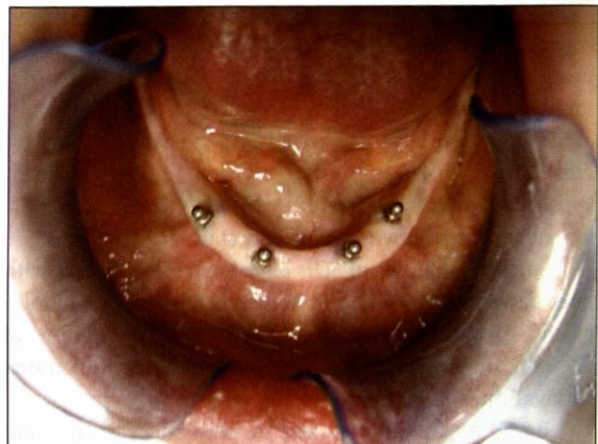

Figure 5—Immediate postoperative view with implants in place.

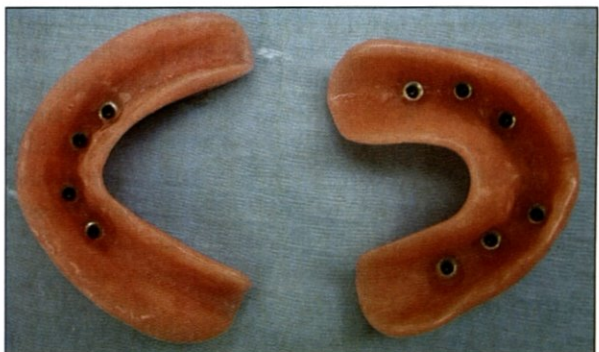


Figure 6—Upper and lower dentures with O-ring keepers in place.

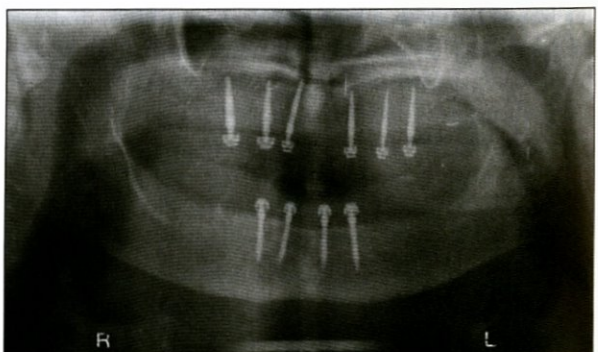


Figure 7—Postoperative panoramic x-ray with upper and lower implants in place.

tent contraindications to MDI placement. Bone characteristics were assessed radiographically in terms of quality (types I through IV) and quantity (divisions A through D).³⁴ Type IV or division D bone was defined as severely atrophic, precluding the placement of MDIs. When type III or division C bone was encountered, MAX^a thread (2.4 mm diameter) implants were used. These patients were assigned the risk factor of atrophic bone.

A panoramic roentgenogram was performed on each patient to assess these bone parameters, locate important anatomical landmarks, and mark placement sites. For example, in mandibular denture stabilization cases, the radiograph was marked between the canine and first bicuspid and lateral incisors anteriorly (Figure 2).

For a detailed description of the procedure used in denture stabilization, please see the noted references^{33,34} and Figures 3 through 7. For fixed prosthetic applications, the primary author developed the Fabricated Implant Restoration and Surgical Technique (F.I.R.S.T.) (Patent: USPTO #7,108,511 B1; September, 2006) as a means to unite MDI placement and crown cementation in a single visit (Figures 8 through 12). A surgical stent and final restoration were fabricated before surgery. Importantly, all implants were placed in a single-stage procedure with immediate functional loading.

Five years and 6 months after the first MDI was placed, a chart review was performed to assess implant survival. This was based on standardized implant success cri-

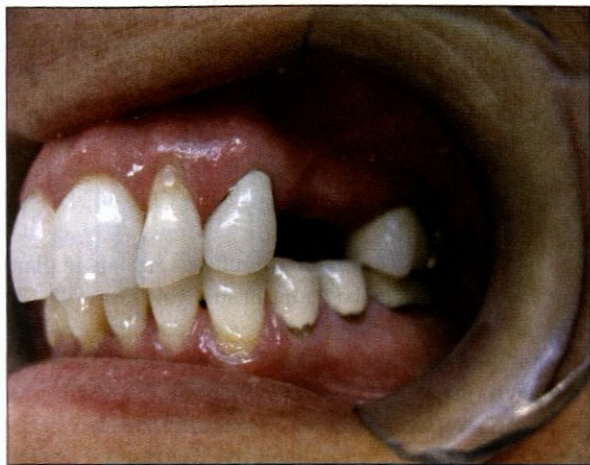

Figure 8—Preoperative view (missing teeth Nos. 12 and 13).

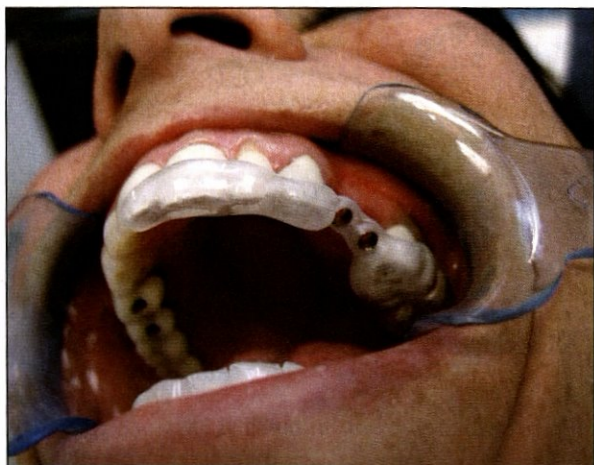


Figure 9—Surgical stent in place.

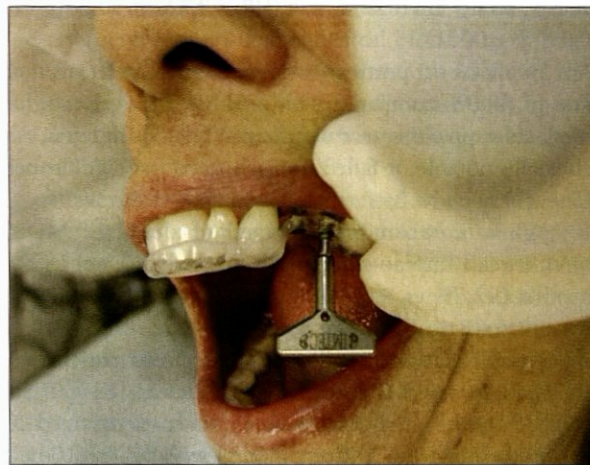


Figure 10—MDI placement using winged thumb-wrench.

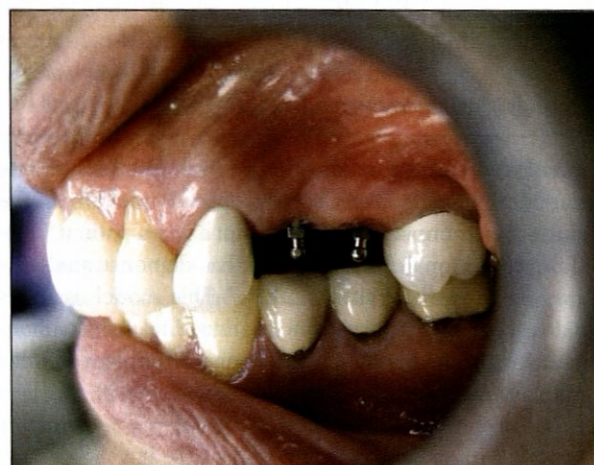

Figure 11—Implants in place.

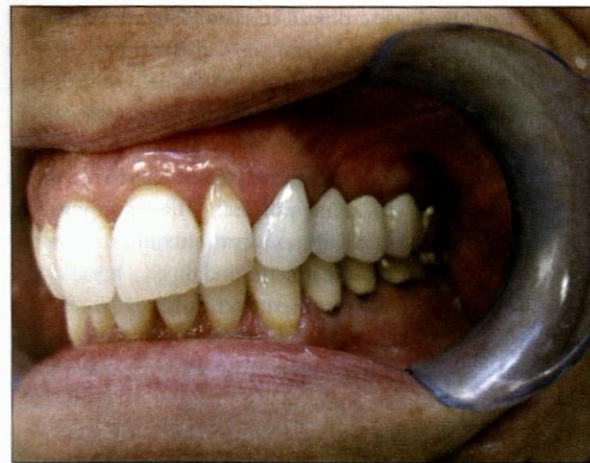

Figure 12—Immediate postoperative view with cemented crowns in place.

teria set forth by Buser and colleagues³⁵: (1) the absence of persistent subjective complaints such as pain, foreign body sensation, or dysesthesia; (2) the absence of recurrent peri-implant infection with suppuration; and (3) the absence of mobility. (The fourth criterion set forth by Buser and colleagues—the absence of a continuous radiolucency around the implant—was not observed in this study.)

Implant mobility was assessed with gentle instrumentation. Removable prostheses allowed for direct assessment of each implant. When mobility of a fixed prosthetic unit was detected, the restoration was removed, and implants were assessed individually. If a fixed prosthesis was stable—and Buser's first 2 criteria were met—it was assumed that all underlying implants were stable.

In addition, patient variables and demographics were obtained from the dental record. These included sex, date of birth, placement date, nature of prosthesis (full or partial upper or lower denture, fixed upper or lower bridge, or single tooth), denture age (new or existing), implant diameter (MAX 2.4 mm or standard 1.8 mm), anatomical location (anterior or posterior, mandibular or maxillary), the presence of bone atrophy (eg, type III or division C bone), smoking status, the date of implant failure (if applicable), and the presence of mobility (with or without suppuration). The date of most recent follow-up was noted, and survival data were censored accordingly. Implants that fractured during placement were recorded but not included in the survival analysis.

Overall implant survival was then determined based on the censored data. The Cox proportional hazards model³⁶ was used to assess the impact of the variables

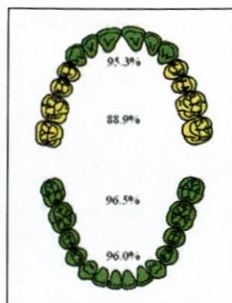


Figure 13—Dental chart with survival percentages based on location.

Table 1—Implant distribution by prosthetic subtype.

Prosthetic Subtype	Percent of Implant Total
Full lower denture	23%
Full upper denture	22%
Single tooth	19%
Fixed lower bridge	16%
Fixed upper bridge	16%
Partial lower denture	3%
Partial upper denture	1%

mentioned earlier on implant survival. While alternate statistical models have been proposed to address the clustering of implant failures within a given patient,³⁷ the Cox proportional hazards model has demonstrated efficacy in implant survival studies.³⁸ This model assumes that each implant placed in an individual has an independent survival risk. The clustering of implant failures in the same patient is therefore deferred.

Results

The mean duration of follow-up was 2.9 implant-years. Of the 2514 implants placed, 145 failures were recorded. This constitutes an overall survival rate of 94.2%. The mean failure time for this series was approximately 6.4 months (193 ± 42 days).

Twenty implants fractured during the placement process. These were not included in the survival analysis, but they comprised approximately 0.8% of the total implants. No in vivo implant fractures were observed.

The implants were placed with similar frequencies in the mandible and maxilla (1256 and 1258, respectively). Forty-eight implants failed in the mandible, and 97 failed in the maxilla.

On further scrutiny of implant location, specific survival trends became apparent. When compared with implants placed in the anterior mandible, posterior maxillary implants were 3.37 times more likely to fail (95% confidence interval [CI] [2.20, 4.99]; $P < .0001$). The schematic dental chart (Figure 13) defines the survival rates based on implant location.

The distribution of implants used for each treatment modality is shown in Table 1. Implant survival based on each modality revealed the following rates (Figure 14). Implants supporting fixed lower bridges fared the best (99.0%), while those supporting full upper dentures fared the worst (83.2%).

Implants supporting fixed prostheses (eg, bridges or single teeth) were considerably more successful than those supporting removable prostheses (eg, full or partial dentures). The survival rates under these indications were 98.3% vs 89.9%, respectively. Compared with implants supporting fixed prostheses, those supporting removable dentures exhibited a hazard ratio (HR) of 4.3 (95% CI [2.30, 4.51]; $P < .0001$).

Smoking status played a significant role in implant survival. Nonsmokers had implant survival rates of 94.7%. The rate among smokers was several percentage points lower at 92.3%. Based on this difference, a HR of 2.28 was calculated (95% CI [1.55, 6.00]; $P < .001$).

Bone atrophy was also a profound predictor of MDI survival. Compared with implants placed into healthy bone, those placed into atrophic bone (eg, type III or division C bone) fared far worse (HR = 3.32; 95% CI [3.17, 9.08]; $P < .0001$).

Implants supporting existing dentures had a survival rate of 88.0% compared with a 91.3% survival rate for implants supporting new dentures. While this difference is clinically notable, it failed to reach statistical significance ($P = .11$).

When compared with standard diameter MDIs, MAX thread implants showed improved survival in the maxilla (92.7% vs 89.2%). Again, this result is clinically but not statistically significant ($P = .09$).

No correlation was discovered between patient age and implant survival (correlation coefficient [r^2] = 0.1; $P = .72$). However, it should be noted that patients aged 20 to 30 years had the greatest success with MDIs (100%), while those aged 90 to 100 fared the worst (83.4%).

Of the 2514 implants placed, 1540 were placed in women, and 974 were placed in men. The survival rates were relatively equal between men and women (93.3% and 94.8%, respectively) and no statistically significant difference based on patient sex was detected ($P = .10$).

One hundred forty-five implant failures were observed. These failures were defined based on the presence of mobility with (19%) or without (81%) supuration. Only 2 complete case failures were encountered where MDIs were aborted as a treatment modality.

A progressive improvement in implant survival was seen with time. The learning curve is sigmoidal in shape and approaches an asymptote toward the end of the study period—steep initially, but progressively flattens throughout the study period (Figure 15).

Discussion

The history of dental implantology is one of paradigm shifts.² In recent years, there has been a movement away from submerged, 2-stage placement without functional loading to single-stage, nonsubmerged procedures with immediate functional loading.³⁹⁻⁴¹ Accordingly, to reduce patient morbidity and convalescence, minimally invasive surgery has become routine.^{7,42}

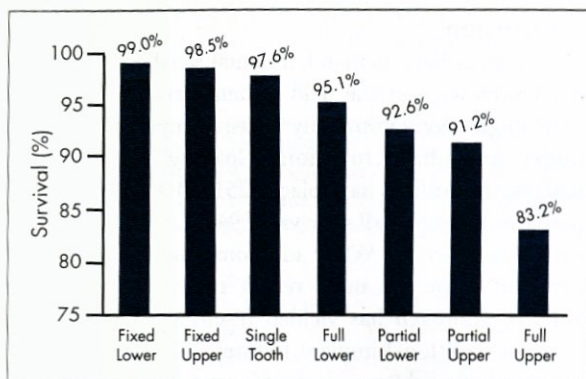


Figure 14—Implant survival based on treatment modality.

MDIs meet these new standards of implant dentistry.⁴³ The authors' reported survival rate of 94.2% is attributable to the gentle handling of tissue—a classical, overarching surgical principle.⁴⁴ Minimally invasive oral surgery preserves peri- and endosteal blood supply, augmenting the osseointegration process. In addition, the flapless approach reduces bleeding, decreases postoperative discomfort, and virtually eliminates the convalescent period.^{45,46}

However, caution must be exercised when new procedures are added to one's armamentarium. As in all surgical procedures, a detailed understanding of the local anatomy is paramount. Rarely, mental nerve neuropraxia may develop, with gradual resolution over time. No cases of permanent paresthesia were observed in this study. With the flapless approach, significant bleeding was rarely, if ever, encountered. Similarly, the authors did not observe clinically significant bone resorption or soft-tissue recession. Maxillary sinus perforation may occur when inappropriate implant lengths are chosen for the maxilla. This should be avoided, but it has little or no clinical consequence. Importantly, the same care and concern that is given to any oral surgery also should be given to MDI placement.

The greatest disadvantage of the MDI is its poor efficiency in immediate extraction sites; the large socket diameter precludes adequate implant-bone interface. Also, a greater number of implants are recommended for MDI restorations.

Prosthetic challenges are encountered with improper implant angulation. Care should be exercised so that the pilot holes are made in parallel fashion. In general, 25 to 30 degrees between implants will still permit adequate prosthetic seating.

Failure is an unavoidable corollary of oral implantology. The authors have minimized failures with a priori risk factor consideration. The major risk factors for MDI failure include the use in removable prostheses (HR = 4.3), the posterior maxilla (3.37), atrophic bone (3.32), and cigarette smokers (2.28) (Table 2).

Implants used to support fixed prostheses had survival rates of 98.3% compared with 89.9% survival in removable prostheses (HR = 4.3; $P < .0001$). As previously

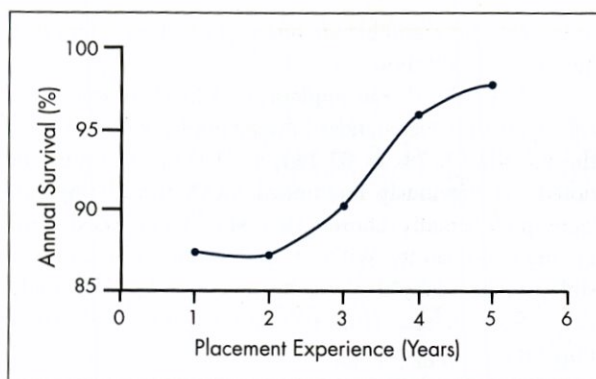


Figure 15—Learning curve.

mentioned, this data is based on the critical assumption that every implant supporting a stable fixed prosthesis is itself stable. Because the endpoint in dental practice is the survival of the prosthesis and not the implant, the authors' assumption has clinical validity. Conversely, this assumption may overestimate implant survival.

Regardless, the survival difference between implants in the fixed and removable prosthetic subgroups merits further discussion as follows: It must first be noted that a greater implant-to-tooth ratio was used in fixed prosthetic stabilization (eg, 10 to 12 implants for a "roundhouse" fixed upper bridge vs 6 implants for a full upper denture). For single tooth replacement, 1 MDI is used for anterior and bicuspid teeth, and 2 MDIs are used for molars. In this context, occlusal and masticatory forces are distributed over an augmented implant interface; the relative strain on any implant is reduced.⁴⁷ Furthermore, the bridgework in these cases acts as a splint, anchoring adjacent implants and reducing micromovement.⁴⁷ In addition, single tooth replacement was more common in the esthetic zone where occlusal forces are minimal. Conversely, for implants supporting removable prostheses, the repeated forces of prosthetic insertion and removal may disrupt the process of osseointegration.

Implants placed in the posterior maxilla (HR = 3.37) displayed a 5-year survival of 88.9%, a considerably lower value in comparison with other anatomical locations (Figure 13). This observation has 2 related etiologies: the thin cortical bone and underlying trabeculation (types II to III) of the posterior maxilla provide a decreased matrix for osseointegration⁴⁸; the occlusal forces on the posterior dentition disrupt osseointegration, resulting in implant mobility. As previously mentioned, implants placed in the esthetic zone are protected from these forces, allowing increased survival anteriorly.⁴⁹ In addition, implants placed

Table 2—Risk factors for MDI failure.

Risk Factor	Hazard Ratio	95% CI	P-value
Removable prostheses	4.30	[2.30, 4.51]	<.0001
Posterior maxilla	3.37	[2.20, 4.99]	<.0001
Atrophic bone	3.32	[3.17, 9.08]	<.0001
Cigarette smoking	2.28	[1.55, 6.00]	<.001

in the anterior mandible are often afforded the support of bicortical stabilization.

While MAX thread implants (2.4 mm) showed clinical superiority over standard thread implants (1.8 mm) in the maxilla (92.7% vs 89.2%), a selection bias must be noted. As previously mentioned, MAX thread implants were preferentially chosen in cases of decreased bone quality and quantity. Without randomization, it is impossible to make definitive conclusions on MAX thread efficacy. Nonetheless, clinical improvements with these implants were apparent.

Bone atrophy is an independent risk factor for implant failure (HR = 3.32; $P < .001$). These results parallel previous work by Jaffin and colleagues who described the excessive loss of traditional implant fixtures in atrophic bone.⁴⁸ It is important for the dentist to use the maximum available MDI length and diameter (eg, MAX thread) when bone quality or quantity is compromised.^{32,33} MDIs are contraindicated when severe bone atrophy is present (eg, type IV and division D bone).^{32,33}

Smoking is a well-known impediment to implant survival,^{50,51} and MDIs are no exception to this rule. Smokers were at a greater risk for implant failure when compared with nonsmokers (HR = 2.28; $P > .001$). An increased incidence of periimplantitis⁵² and delayed intraoral wound healing⁵³ has been reported in patients who smoke. In concert, these factors are responsible for the elevated implant failures in this subpopulation.

Implant survival was not correlated with age ($r^2 = 0.1$; $P = .72$). Similar results were found in a large scale study by the Dental Implants Clinical Research Group,⁵⁴ which further supported the broad patient base suitable for this procedure.

Our results indicate that implants fail in a predictable temporal distribution. When considering all failed implants, the mean failure time was approximately 6.4 months (193 ± 42 days). This temporally correlates with osseointegration, classically defined as 3 to 6 months in the mandible and 6 to 9 months in the maxilla^{55,56}; therefore, 6 months should be considered a landmark of implant stability after which subsequent failure is unlikely.

Technical experience is crucial to any surgical procedure. Progressive improvements in implant survival were observed throughout the study period (Figure 15). However, a potential observer bias should be considered. Because implants placed toward the end of the study have shorter follow-up periods, an inflation of their survival rates could occur. As previously mentioned, the mean failure time in this study was approximately 6 months. Given that the average duration of follow-up was 2.9 years, a more likely explanation for the curve's sigmoid shape is the differential rate of skill acquisition: a slow initial learning phase followed by more rapid technical improvements. With appropriate MDI training and respect for traditional implant theory, the general dentist can successfully introduce MDIs into his or her daily practice.⁵⁷

Conclusion

Patients have demanded dental rehabilitation without morbidity, and the field of dentistry has responded with single-stage, minimally invasive implant placement under immediate functional loading. Under these tenets, the authors have placed 2514 MDIs over a 5-year period with an overall survival of 94.2%. Only 2 case failures were observed. While additional implant failures are expected from the most recent cohort of MDIs, the authors' approach has yielded results comparable with those of traditional implant fixtures. With consideration for prosthetic subtype, implant location, bone characteristics, and smoking status, the general dentist and his or her patients can achieve great success with MDIs.⁵⁸

This article is dedicated to the memory of Dr Charles E English, educator, clinician, and friend.

Acknowledgments

The authors wish to thank Andrew Jakson, director, F.I.R.S.T. Laboratories, LLC, for his ingenuity and expertise in prosthetic fabrication. We also wish to express our sincere appreciation to Atish Patankar, MS, Industrial Engineering, for his compilation and statistical analysis of the data set.

Disclosure

Dr Todd E Shatkin is a consultant and lecturer for IMTEC Corporation. He is also a co-owner of F.I.R.S.T. Laboratories, LLC, and owns the patent rights to the F.I.R.S.T. procedure.

References

1. Branemark PL, Hansson BO, Adell R, et al. Osseointegrated implants in the treatment of the edentulous jaw. Experience from a 10-year period. *Scand J Plast Reconstr Surg Suppl.* 1977;16:1-132.
2. Taylor TD, Agar JR. Twenty years of progress in implant prosthodontics. *J Prosthet Dent.* 2002;88:89-95.
3. ADA Council on Scientific Affairs. Dental endosseous implants: an update. *J Am Dent Assoc.* 2004;135:92-97.
4. Esposito M, Coulthard P, Thomsen P, et al. Interventions for replacing missing teeth: different types of dental implants. *Cochrane Database System Rev.* 2005;Jan 25;(1):CD003815.
5. Fenlon MR, Palmer RM, Palmer P, et al. A prospective study of single stage surgery for implant supported overdentures. *Clin Oral Implants Res.* 2002;13:365-370.
6. Morton D, Martin WC, Ruskin JD. Single-stage Straumann dental implants in the aesthetic zone: considerations and treatment procedures. *J Oral Maxillofac Surg.* 2004;62(9 suppl 2):57-66.
7. Hahn J. Single-stage, immediate loading, and flapless surgery. *J Oral Implantol.* 2000;26:193-198.
8. Degidi M, Piattelli A, Felice P, et al. Immediate functional loading of edentulous maxilla: a 5-year retrospective study of 388 titanium implants. *J Periodontol.* 2005;76:1016-1024.
9. Castellon P, Blatz MB, Block MS, et al. Immediate loading of dental implants in the edentulous mandible. *J Am Dent Assoc.* 2004;135:1543-1549.
10. Davarpanah M, Martinez H, Tecuciana JF, et al. Small-diameter implants: indications and contraindications. *J Esthet Dent.* 2000;12:186-194.

11. Comfort MB, Chu FC, Chai J, et al. A 5-year prospective study on small diameter screw-shaped oral implants. *J Oral Rehabil.* 2005;32:341-345.
12. Zinsli B, Saggerer T, Mericske E, et al. Clinical evaluation of small-diameter ITI implants: a prospective study. *Int J Oral Maxillofac Implants.* 2004;19:92-99.
13. Block MS, Delgado A, Fentent MG. The effect of diameter and length of hydroxylapatite-coated dental implants on ultimate pullout force in dog alveolar bone. *J Oral Maxillofac Surg.* 1990;48:174-178.
14. Kido H, Schulz EE, Kumar A, et al. Implant diameter and bone density: effect on initial stability and pull-out resistance. *J Oral Implantol.* 1997;23:163-169.
15. Saadoun AP, Le Gall MG. An 8-year compilation of clinical results obtained with Steri-Oss endosseous implants. *Compend Contin Educ Dent.* 1996;17:669-687.
16. Lazzara R, Siddiqui AA, Binon P, et al. Retrospective multicenter analysis of 3i endosseous dental implants placed over a five-year period. *Clin Oral Implants Res.* 1996;7:73-83.
17. Vigolo P, Givani A. Clinical evaluation of single-tooth mini-implant restorations: a five-year retrospective study. *J Prosth Dent.* 2000;84:50-54.
18. Vigolo P, Givani A, Majzoub Z, et al. Clinical evaluation of small-diameter implants in single-tooth and multiple-implant restorations: a 7-year retrospective study. *Int J Oral Maxillofac Implants.* 2004;19:703-709.
19. Sendax VI. Mini-implants as adjuncts for transitional prostheses. *Dent Implantol Update.* 1996;7:12-15.
20. el Attar MS, el Shazly D, Osman S, et al. Study of the effect of using mini-transitional implants as temporary abutments in implant overdenture cases. *Implant Dent.* 1999;8:152-158.
21. Petrungraro PS, Windmiller N. Using transitional implants during the healing phase of implant reconstruction. *Gen Dent.* 2001;49:46-51.
22. Kanomi R. Mini-implant for orthodontic anchorage. *J Clin Orthod.* 1997;31:763-767.
23. Fritz U, Diedrich P, Kinzinger G, et al. The anchorage quality of mini-implants towards translatory and extrusive forces. *J Orofac Orthop.* 2003;64:293-304.
24. Nagata M, Nagaoka S. Mini-implant is effective as a transitional fixation anchorage for transplantation of teeth. *Japanese Journal of Conservative Dentistry.* 2002;45:69.
25. Nagata M, Nagaoka S. Preservation of severe periodontitis-affected teeth by the use of transitional mini-implants, special reference to the Periotest measurement. *Journal of the Japanese Society of Periodontology.* 2001;43:104.
26. Nagata M, Nagaoka S. Preservation of the natural teeth and arch integrity by the use of transitional mini-implants. *J Periodontol.* 2000;71:1910.
27. English CE, Bohle G. Diagnostic, procedural, and clinical issues with the Sendax mini dental implant. *Compend Contin Educ Dent.* 2003;24(51):3-25.
28. Ahn MR, An KN, Cho JH, et al. Immediate loading with mini dental implants in the fully edentulous mandible. *Implant Dent.* 2004;13:367-372.
29. Mazor Z, Steigmann M, Leshem R, et al. Mini-implants to reconstruct missing teeth in severe ridge deficiency and small interdental space: a 5-year case series. *Implant Dent.* 2004;13:336-341.
30. Bulard RA, Vance JB. Multi-clinic evaluation using mini-dental implants for long-term denture stabilization: a preliminary biometric evaluation. *Compend Contin Educ Dent.* 2005;26:892-897.
31. Kanie T, Nagata M, Ban S. Comparison of the mechanical properties of 2 prosthetic mini-implants. *Implant Dent.* 2004;13:251-256.
32. Shatkin TE, Shatkin S, Oppenheimer AJ, et al. A simplified approach to implant dentistry with mini dental implants. *Alpha Omegan.* 2003;96:7-15.
33. Shatkin TE, Shatkin S, Oppenheimer A. Mini dental implants for the general dentist. *Compend Contin Educ Dent.* 2003;24(11):S1:26-34.
34. Misch CE. Divisions of available bone in implant dentistry. *Int J Oral Implantol.* 1990;7:9-17.
35. Buser D, Mericske-Stern R, Bernard JP, et al. Long-term evaluation of non-submerged ITI implants. Part I: 8-year life table analysis of a prospective multi-center study with 2359 implants. *Clin Oral Implants Res.* 1997;8:161-172.
36. Cox DR, Oakes D. *Analysis of Survival Data.* Boca Raton, Fla: Chapman & Hall/CRC Press, 1984.
37. Chuang SK, Tian L, Wei LJ, et al. Kaplan-Meier analysis of dental implant survival: a strategy for estimating survival with clustered observations. *J Dent Res.* 2001;80:2016-2020.
38. Vehemente VA, Chuang SK, Daher S, et al. Risk factors affecting dental implant survival. *J Oral Implantol.* 2002;28:74-81.
39. Adell R, Lekholm U, Rockler B, et al. A 15-year study of osseointegrated implants in the treatment of the edentulous jaw. *Int J Oral Surg.* 1981;10:387-416.
40. Buser D, Mericske-Stern R, Dula K, et al. Clinical experience with one-stage, non-submerged dental implants. *Adv Dent Res.* 1999;13:153-161.
41. Hallman M. A prospective study of treatment of severely resorbed maxillae with narrow nonsubmerged implants: results after 1 year of loading. *Int J Oral Maxillofac Implants.* 2001;16:731-736.
42. Zadeh HH, Daftary F. Minimally invasive surgery: an alternative approach for periodontal and implant reconstruction. *J Calif Dent Assoc.* 2004;32:1022-1030.
43. Bulard RA. Mini implants. Part I. A solution for loose dentures. *J Okla Dent Assoc.* 2002;93:42-46.
44. MacCallum WG. *William Stewart Halsted: Surgeon.* Baltimore, Md: The Johns Hopkins Press; 1930.
45. Gibney JW. Minimally invasive implant surgery. *J Oral Implantol.* 2001;27:73-76.
46. Campelo LD, Camara JR. Flapless implant surgery: a 10-year clinical retrospective analysis. *Int J Oral Maxillofac Implants.* 2002;17:271-276.
47. Weiss CM, Weiss A. *Principles and Practice of Implant Dentistry.* St Louis, Mo: Mosby Inc; 2001.
48. Jaffin RA, Berman CL. The excessive loss of Branemark fixtures in type IV bone: a 5-year analysis. *J Periodontol.* 1991;62:2-4.
49. Polizzi G, Fabbro S, Furri M, et al. Clinical application of narrow Branemark system implants for single-tooth restorations. *Int J Oral Maxillofac Implants.* 1999;14:496-503.
50. De Bruyn H, Collaert B. The effect of smoking on early implant failure. *Clin Oral Implants Res.* 1994;5:260-264.
51. Bain CA, Moy PK. The association between the failure of dental implants and cigarette smoking. *Int J Oral Maxillofac Implants.* 1993;8:609-615.
52. Klinge B, Hultin M, Berglundh T. Peri-implantitis. *Dent Clin North Am.* 2005;49:661-676, vii-viii.
53. Jones JK, Triplett RG. The relationship of cigarette smoking to impaired intraoral wound healing: a review of evidence and implications for patient care. *J Oral Maxillofac Surg.* 1992;50:237-239.
54. Ochi S, Morris HF, Winkler S. Patient demographics and implant survival at uncovering: Dental Implant Clinical Research Group Interim Report No. 6. *Implant Dent.* 1994;3:247-251.
55. Jemt I, Lekholm U, Adell R. Osseointegrated implants in the treatment of partially edentulous patients: a preliminary study of 876 consecutively placed fixtures. *Int J Oral Maxillofac Implants.* 1989;4:211-217.
56. Branemark PI, Zarb GA, Albrektsson T. *Tissue-Integrated Prostheses: Osseointegration in Clinical Dentistry.* Chicago, Ill: Quintessence; 1985.
57. Bulard RA. Mini dental implants: enhancing patient satisfaction and practice income. *Dent Today.* 2001;20:82-85.
58. Shatkin T, Shatkin S, Oppenheimer B, et al. Maximize your profits with minis. *Dent Econ.* 2004;94:150-154.

Quiz 3

1. Small diameter implants (SDIs) are the preferred treatment modality in cases of:
 - a. limited anatomical geography.
 - b. apprehensive dental patients.
 - c. severely resorbed ridge.
 - d. immediate placement in maxillary tuberosities.
2. Mini dental implants (MDIs) have diameters ranging from:
 - a. 1.8 mm to 2.4 mm.
 - b. 2.75 mm to 3.3 mm.
 - c. 3.45 mm to 5.0 mm.
 - d. 6.0 mm to 8.0 mm.
3. In this study, most patients were selected for MDI placement based on:
 - a. smoking history.
 - b. diabetes history.
 - c. objective predetermined criteria.
 - d. subjective complaints.
4. Type IV or division D bone was defined as:
 - a. robust.
 - b. wide but short ridge.
 - c. wide and tall ridge.
 - d. severely atrophic.
5. Standardized implant success criteria set forth by Buser and colleagues include the absence of:
 - a. persistent subjective complaints.
 - b. recurrent periimplant infection with suppuration.
 - c. mobility.
 - d. all of the above
6. The mean failure time for this series was approximately:
 - a. 2.2 weeks.
 - b. 2.7 months.
 - c. 6.4 months.
 - d. 11.3 months.
7. Compared with implants supporting fixed prostheses, those supporting removable dentures exhibited a hazard ratio of:
 - a. 0.073
 - b. 2.28
 - c. 4.3
 - d. 9.5
8. The authors' reported survival rate of 94.2% is attributable to the:
 - a. rigid inclusion/exclusion criteria.
 - b. gentle handling of tissue.
 - c. meticulous surgical technique.
 - d. extensive presurgical planning.
9. The greatest disadvantage of the MDI is:
 - a. its poor efficacy in immediate extraction sites.
 - b. its cost.
 - c. the technical skill required in placement.
 - d. the technical skill required in restoration placement.
10. What should be considered a landmark of implant stability after which subsequent failure is unlikely?
 - a. 1 week
 - b. 1 month
 - c. 6 months
 - d. 1 to 2 years

Please see tester form on page 101.

This article provides 1 hour of CE credit from Ascend Dental Media, in association with the University of Southern California School of Dentistry and the University of Pennsylvania School of Dental Medicine, representatives of which have reviewed the articles in this issue for acceptance. Record your answers on the enclosed answer sheet or submit them on a separate sheet of paper. You may also phone your answers in to (888) 596-4605 or fax them to (703) 404-1801. Be sure to include your name, address, telephone number, and last 4 digits of your Social Security number.

