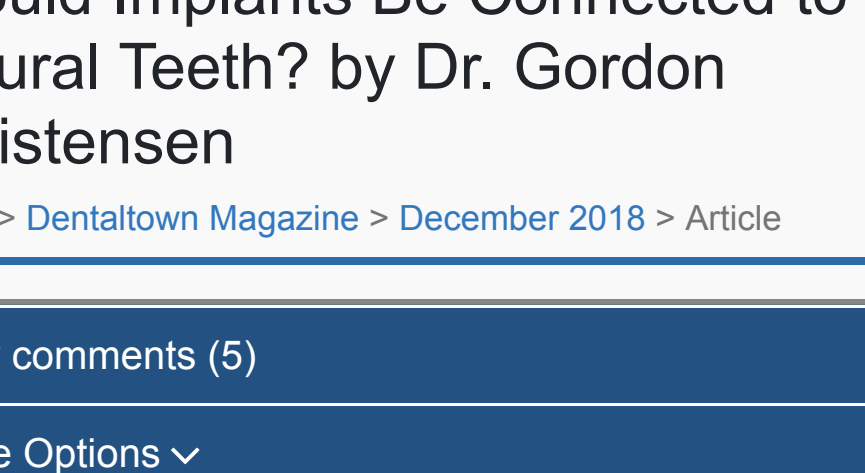



Should Implants Be Connected to Natural Teeth? by Dr. Gordon Christensen

Home > Dentaltown Magazine > December 2018 > Article

view comments (5)

More Options

Tweet Share Save

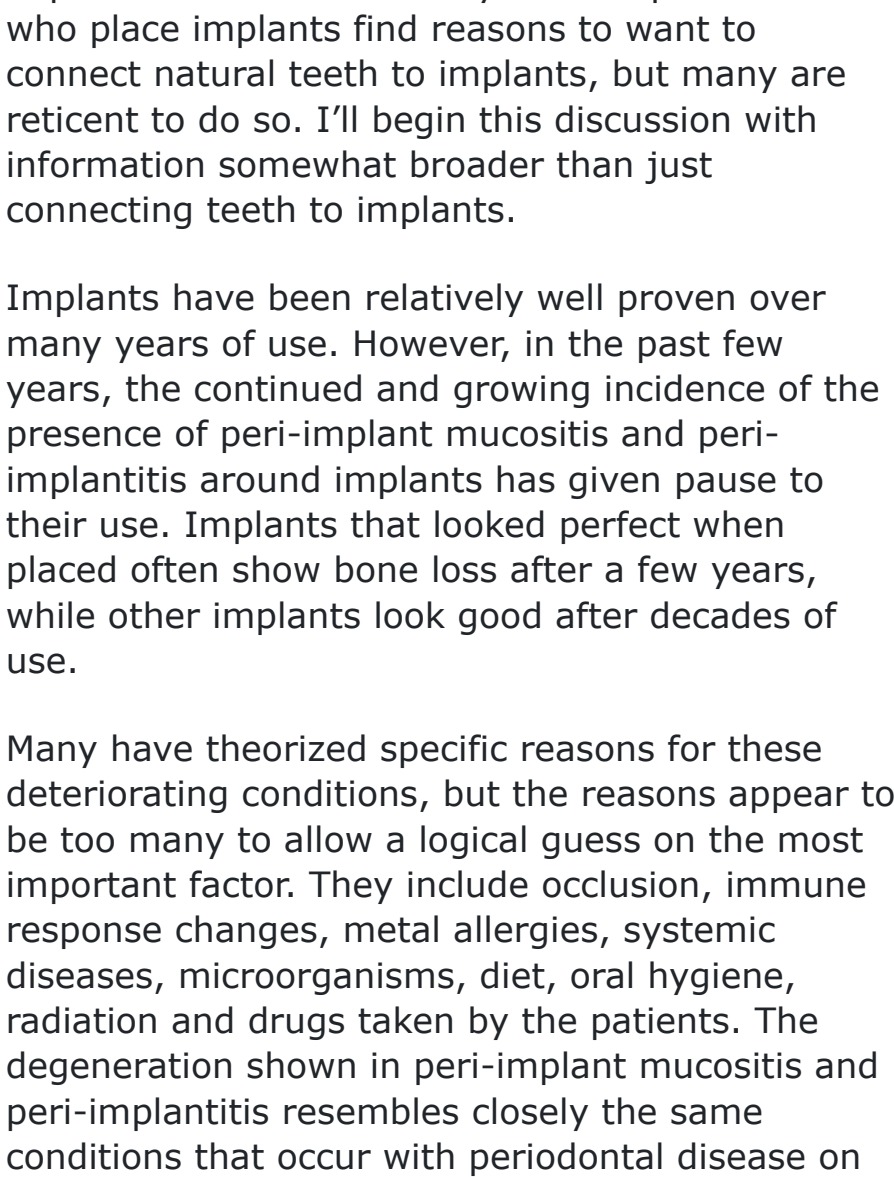


Fig. 1

by Gordon J. Christensen, DDS, MSD, PhD

Both you and I find occasions when patients have clinical situations where it seems logical and feasible to attach implants to natural teeth. However, you've heard from some specialists that this concept is not successful and should not be attempted. What is the current state of the art about this procedure?

I've been placing and restoring root-form dental implants for more than 30 years. All practitioners who place implants find reasons to want to connect natural teeth to implants, but many are reticent to do so. I'll begin this discussion with information somewhat broader than just connecting teeth to implants.

Implants have been relatively well proven over many years of use. However, in the past few years, the continued and growing incidence of the presence of peri-implant mucositis and peri-implantitis around implants has given pause to their use. Implants that looked perfect when placed often show bone loss after a few years, while other implants look good after decades of use.

Many have theorized specific reasons for these deteriorating conditions, but the reasons appear to be too many to allow a logical guess on the most important factor. They include occlusion, immune response changes, metal allergies, systemic diseases, microorganisms, diet, oral hygiene, radiation and drugs taken by the patients. The degeneration shown in peri-implant mucositis and peri-implantitis resembles closely the same conditions that occur with periodontal disease on natural teeth. The subject needs continued research to understand the problem. So, what does the rising trend of implant deterioration have to do with the title of this article?

Study of periodontal disease has been ongoing for many decades, and the profession knows how to prevent and treat periodontal disease around natural teeth. The idea that implants are equal to or even better than natural teeth is now under question. My strong conclusion after years of observing thousands of dental implants in service is: There is nothing like a natural tooth. Keep them if at all possible.

When you can accomplish conventional operative dentistry and fixed and removable prosthodontics, don't consider these procedures to be a second-tier level of treatment. In many cases, they should be the primary choice, because we know well the proven longevity of these types of treatment.

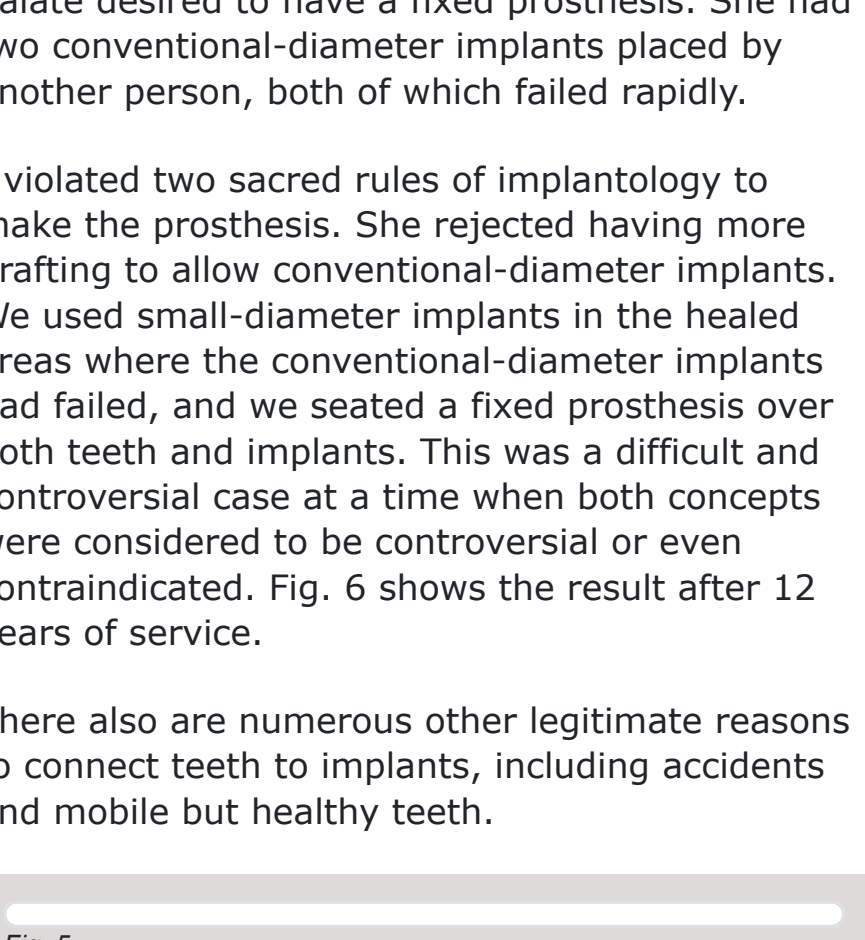


Fig. 2

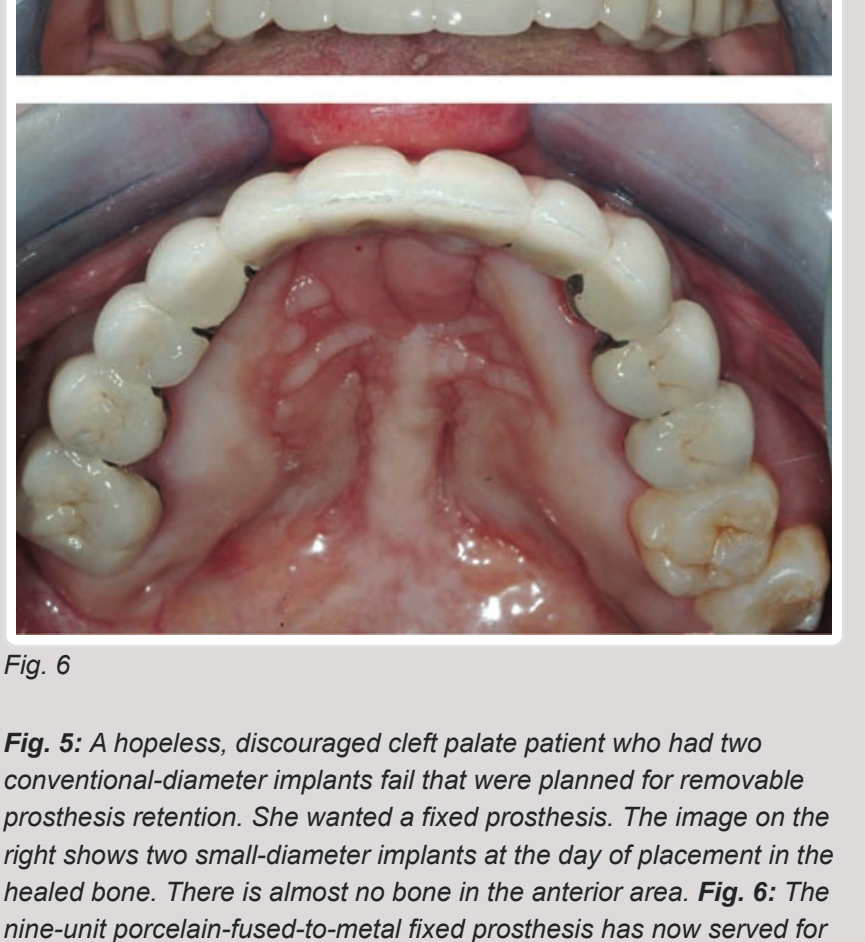


Fig. 3

Fig. 1: Patient with failed hemisected molar previously grafted in the second-molar area. Patient was not interested in extensive and expensive repair and wanted the most conservative plan. Connecting one implant to the strong premolar was the accepted treatment plan, after explaining the potential challenges of the tooth-to-implant technique to the patient. The radiograph on the right is 12 years after the prosthesis was placed. The porcelain-fused-to-metal fixed prosthesis on the maxillary arch has now served more than 30 years. Don't throw conventional dental treatment away yet! **Fig. 2:** Patient with adequate bone quality and quantity in the second-molar area, and somewhat questionable quality in the first-molar area. The decision was made to connect the two implants to the vital premolar tooth. That treatment was accomplished many years ago. Today, I would not place abutments on the implants, as in the photo, but rather would connect the splinted crowns to the implants by screwing through the crowns into the implants. **Fig. 3:** The radiograph on the left is at placement of the fixed prosthesis in 2004. The radiograph on the right is the same patient as described in Fig. 2 after 14 years.

When should connecting a natural tooth to an implant be considered?

Financial considerations. Implants are expensive. The fee for an implant, potential grafting, an abutment and a crown amounts to thousands of dollars. Often, patients cannot afford such treatment. Minimizing the number of implants is an option, but it may require connecting the implant to a natural tooth.

Fig. 1 shows a potential need for attachment of a natural tooth to an implant. At the time of treatment, the patient was retired and somewhat debilitated, and had dental treatment fail in his mouth. He did not want to have additional, extensive and expensive dental treatment.

Inadequate quantity or quality of bone. Grafting bone is a common procedure, but it's not done by many general dentists. Each year, more general dentists are placing implants, and I encourage them to learn how to do grafting after extractions on a routine basis. Grafting requires time for maturation, and is expensive for patients and dentists. There are times when a simple connection of a natural tooth to an implant eliminates the extra procedures and costs explained above.

Figs. 2 and 3 show a patient who had adequate bone density in the posterior right mandibular area with less bone density in the first-molar area. Rather than place an implant in that area, the two implants were connected to a stable, vital tooth. The photo in Fig. 3 was taken 14 years after treatment.

Need for more support for a cemented fixed prosthesis. There are times when there is not enough bone for an implant without grafting, as shown in Fig. 4. In this case, we solved the dilemma by connecting the remaining natural tooth to an implant.

There are many times when there are not enough natural teeth to support a fixed prosthesis. Figs. 5 and 6 show such a case: This person with a cleft palate desired to have a fixed prosthesis. She had two conventional-diameter implants placed by another person, both of which failed rapidly.

I violated two sacred rules of implantology to make the prosthesis. She rejected having more grafting to allow conventional-diameter implants. We used small-diameter implants in the healed areas where the conventional-diameter implants had failed, and we seated a fixed prosthesis over both teeth and implants. This was a difficult and controversial case at a time when both concepts were considered to be controversial or even contraindicated. Fig. 6 shows the result after 12 years of service.

There also are numerous other legitimate reasons to connect teeth to implants, including accidents and mobile but healthy teeth.

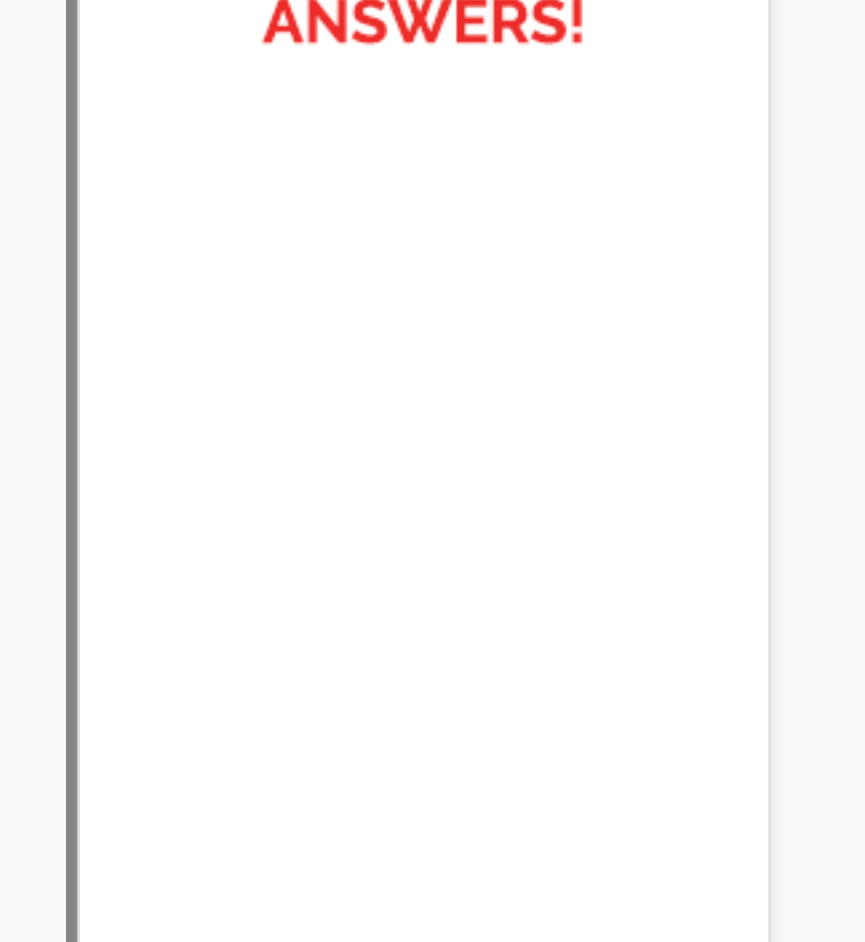


Fig. 5

Fig. 6

Fig. 5: A hopeless, discouraged cleft palate patient who had two conventional-diameter implants fail that were planned for removable prosthesis retention. She wanted a fixed prosthesis. The image on the right shows two small-diameter implants at the day of placement in the healed bone. There is almost no bone in the anterior area. **Fig. 6:** The nine-unit porcelain-fused-to-metal fixed prosthesis has now served for 12 years supported and retained by both teeth and implants. She has been a very faithful patient with her oral hygiene and has avoided chewing hard foods in the anterior portion of her mouth.

Technique for connecting teeth to implants

Contrary to popular belief, when accomplished properly, teeth can be connected to implants. After many years of placing implants, I will fully admit this is not my preferred technique; however, it solves commonly occurring treatment planning challenges, a few of which have been identified in this article.

What is the proper technique?

Select only strong, healthy teeth. Connecting implants to mobile teeth is highly questionable. The teeth should be solidly in bone and have enough remaining tooth structure or build-ups to ensure acceptable retention of the abutment crown.

Use porcelain-fused-to-metal. I recommend waiting until zirconia has had a few more years of clinical use and the restoration strength can be trusted. Too many zirconia crowns are currently coming off in service. Unfortunately, there are numerous formulations of zirconia, some of which are not strong and have minimal or no transformation toughening to reduce subsequent failure. Most dentists are not aware of the differences in the highly promoted types of zirconia. Only the original Gidewell BruxZir has had adequate research to validate it. Others are currently in clinical research and they look promising.

Tooth preparations and implant abutments must be very retentive. Separate abutments for the implants can be avoided if the implants are perpendicular to the occlusal plane. A screw alone can then connect the crown to the implant, as in Fig. 4 (page 42). If that's not possible, make the implant abutment very parallel to the tooth preparation. If the abutment crown comes loose from the tooth, the tooth will intrude into the bone rapidly. I learned this 20 years ago with several failed cases.

Scratch and roughen the axial walls of the tooth preparation and the implant abutment, if using a separate abutment. This will provide a "luting" effect and interdigitation of the cement into the tooth prep and the abutment.

Use resin cement. Resin cement such as 3M RelyX Unicem 2, Kerr Maxcem Elite Chroma, Ivoclar Vivadent Multilink Automix and Kuraray Panavia offer strength. You need strength!

Avoid use of provisional cements. The connection between the implant and the tooth must be rigid, or the tooth will fail by intrusion when the cement fails on the tooth abutment.

Adjust occlusion carefully. Traumatic occlusion can break the cement bond and cause overall failure.

Summary

The false assumption that implants should not be attached to natural teeth has permeated the profession for several years. It is now obvious from both clinical observation and controlled research that this procedure, done correctly, is viable.

This article includes suggestions for when this procedure is desirable, describes an acceptable technique, and shows examples of several long-term, successful cases.

Author Bio

Gordon J. Christensen, DDS, MSD, PhD, is a practicing prosthodontist in Provo, Utah, and an adjunct professor at the School of Dentistry at the University of Utah. He is a diplomate of the American Board of Prosthodontists, and the CEO of Practical Clinical Courses and the Clinicians Report Foundation. Information: pccidental.com

Tweet Share Save

view comments (5)

view article pdf

more by this author (25)

follow

Dentaltown Magazine

March 2019

Read Current Issue

Subscribe / Renew

Sponsors

Get Started

The perfect radio show for Dentists looking for ANSWERS!

Townie® Poll

Have you spent more than \$15,000 on new clinical technology in your practice in the past three years?

Yes

No

Vote Results