

FLAPLESS DENTAL IMPLANT PLACEMENT

Dennis Flanagan, DDS

Flapless dental implant placement is possible in selected patients but limited to those sites with adequate or augmentable attached gingiva and available bone volume and density. Inadequate attached gingiva, available bone, and bone density may be augmented by pre-, intra-, or postoperative procedures. Bone ridge contour can be approximated by using a described fast set polyvinyl siloxane site evaluation technique. Assuming adequate length and height, a bone width of 5 mm is usually acceptable for standard diameter implants (3.5–4.2 mm). However, implant placement in sites with parabolic shaped ridges may need to be placed deeper to avoid vertical bone loss and implant thread exposure. Inadequate bone volume, less than 5 mm of bone width, may be developed by ridge expansion (split ridge) techniques. With ridge expansion, complications may arise such as malposition and labyrinthine concussion. Malposition may be corrected intraoperatively or grafted for a later implant placement. Labyrinthine concussion is usually of short duration but may be treated with head maneuvers. Sites with 2 mm or less width of available bone may not be treated flaplessly and may be more appropriately treated with extracortical augmentation grafting.

Key Words: dental implant, flapless surgery, bone expansion, site evaluation, bone deformation

INTRODUCTION

When dental implants are placed by raising a surgical mucoperiosteal flap, there is an associated slight bone loss at the site. Scarring and other complications are of concern. In the esthetic zone these may lead to an unsatisfactory outcome.^{1,2} Placing implants by using a flapless or envelope incision may eliminate some of these concerns. However, the true quality and quantity of bone underlying the mucogingival covering cannot be directly observed.³ Plane film radiographs can depict some information about the bone site but there is no 3-dimensional information as to actual bone contour or quality. Computerized tomogram radiographic (CT) scans depict bone contour and density (Hounsfield units) but these may be expensive and impractical for single or small sites.⁴

Flapless implant placement involves recognition by the surgeon of the pitfalls and caveats of the

technique. The topography of the underlying available bone is key information in the decision for a flapless procedure. An appropriate site requires 5 mm of facial-lingual width and 7 mm of mesiodistal length. These dimensions allow a standard-sized diameter (3.5–4.2 mm) root form screw type or press fit implant to be placed with adequate bone housing and implant-dental spacing. The vertical platform position should be 2 to 4 mm apical to the adjacent proximal cemento-enamel junction.⁵

Very small diameter (1.8 mm, mini) implants may be placed flaplessly but a denser quality of bone may be necessary for implant stability as well as an adequate zone of attached gingiva for protection of the implant epithelial coronal attachment.

Sites that are narrow in length can be obviously seen and corrected by orthodontic movement or extraction of imposing teeth. However, a narrow bone ridge width may be obscured. A thick epithelium and submucosa may hide a narrow atrophic ridge, a poorly healed extraction site, or even a nonexistent bone ridge. The implant surgeon must be circumspect. The flapless approach may be less traumatic and time consuming, have fewer complications and faster soft tissue healing, and be restoratively appropriate when compared to an open flap approach.

Dennis Flanagan, DDS, is a diplomate in ABO/ID, ICOI, ABGD and a fellow of AAID. Address correspondence to Dr Flanagan at 1671 West Main St, Willimantic, Conn 06226 (e-mail: dffdds@charter.net).

PATIENT SELECTION

Some authors believe that there are no absolute contraindications for dental implant treatment.^{6,7} Most dental implant patients are classified in the American Society of Anesthesiologists (ASA) class I, II, and some in III. These patients are healthy or have medically controlled mild diseases. Smokers and patients with interleukin (IL)-1 cytokine (IL-1 genotype polymorphism) expression may be at higher risk of implant failure to osseointegrate.⁸ However, there is recent evidence that IL-2 (T-330G) and IL-6 (G-174C) genes are not associated with early implant failure so that these single polymorphisms are not a genetic risk factor.⁹ Patients with a history of vertigo may need surgical caution for an osteotome procedure.¹⁰ Patient expectations should be discussed. The patient needs to understand and accept the procedures, proposed outcome, and the possibility of complications. The patient should be appropriate for implant surgical and prosthetic procedures.

SITE SELECTION

Important proximate anatomical structures may need to be avoided or surgically repositioned when considering an appropriate site. An antrum lining may need elevation and bone grafting when there is bone less than 10 mm between the antrum and ridge crest. The implant may be placed flaplessly, concomitantly, with adequate stability. These sites may be pre- or intraoperatively augmented via flapless crestal osteotome or flapped lateral approach bone grafting technique.

The length and width of the site should be adequate to accommodate an appropriately sized implant. The bone height should be adequate to contain the implant or be readily augmented and have a margin of safety from anatomical structures such as a neurovascular bundle. In addition to adequate height and length the flapless approach requires a site that has certain other attributes. The attached gingiva should be at least 4 mm from the proposed free gingival margin to the mucogingival junction. However, a site lacking adequate attached gingiva may be augmented intra- or postoperatively. The bone should be of adequate density to support initial implant immobility. Assuming adequate length and height, three classifications of bone sites are suggested: Class 1 bone, with bone crest width greater than 5 mm, can accept an implant with little or no alteration or development; Class 2 bone, with bone crest width 2 to 5 mm, would need site development in the form of a flapless ridge expansion (split ridge) or extra-

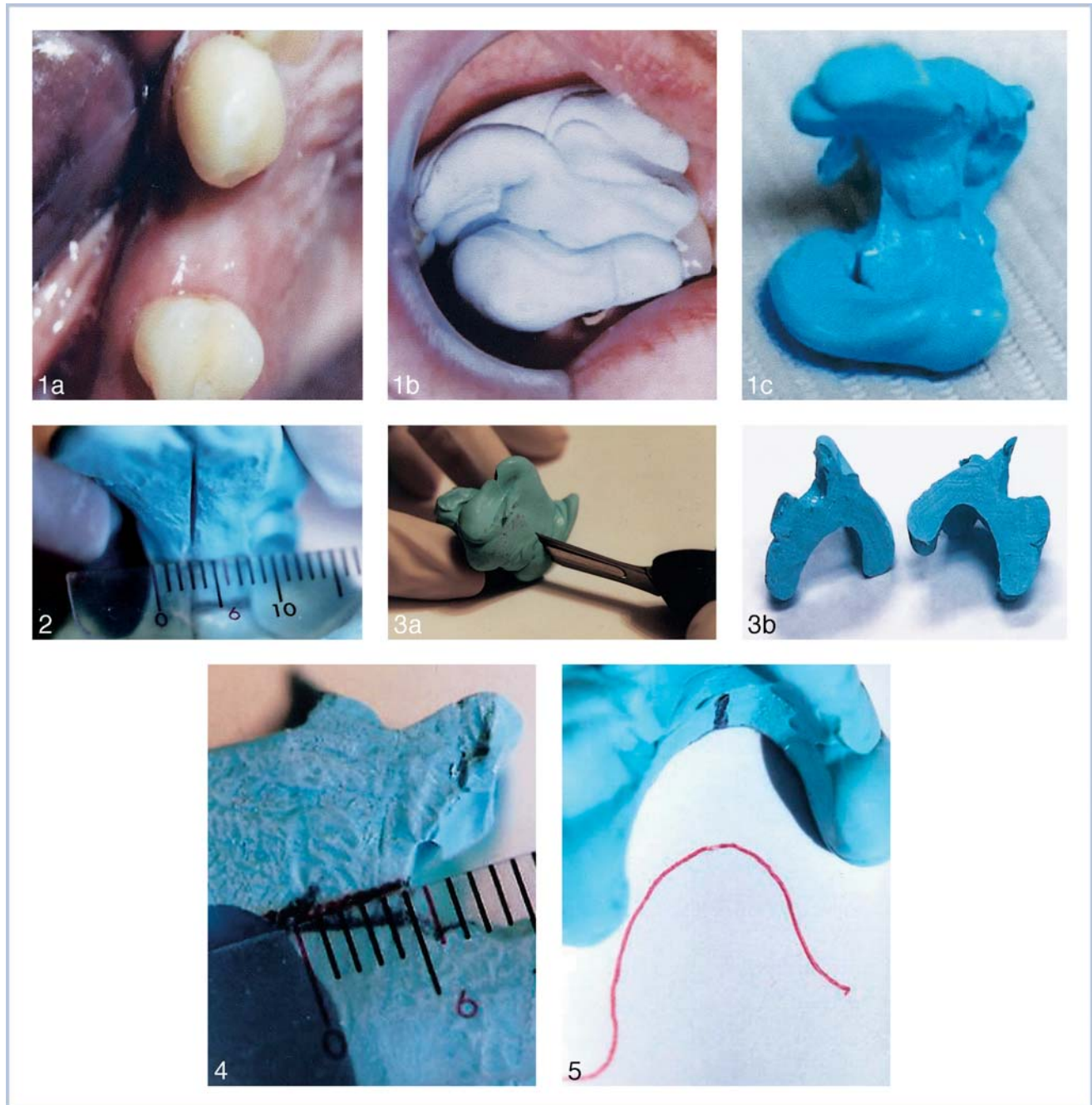
cortical augmentation and thus not flapless; Class 3 bone, with bone crest width less than 2 mm, would probably not be appropriate for a flapless procedure without site development by extracortical ridge augmentation, such as particulate or block grafting. Sites with lengths less than 7 mm may force the surgeon to make an envelope incision that includes the adjacent gingival papilla. This may induce scarring that may compromise the esthetic papillary result. Any hopeless or poor prognosis teeth (bone loss greater than 50%) may be extracted before implant placement to prevent midtreatment plan changes in implant distribution or prosthetic design.

Adjacent periodontal gingival architecture may influence implant positioning. Thick or thin gingival architecture may need to be considered in implant positioning. Sites with thin architecture may be more sensitive to implant positioning in that there may be no leeway for error or range of positioning.

Opposing occlusion should be examined and an occlusal scheme determined that is appropriate for the final restoration. It is understood that teeth intrude under occlusal forces more than osseointegrated implants. This discrepancy needs to be considered so that the supporting implant or implants do not bear the full occlusal load. Occlusal force has been recorded greater than 1000 N.¹¹ It may be that if an implant does indeed bear an occlusal force as much as 1000 N, it may luxate and may produce microhemorrhage, fibrosis, and implant failure.¹² Parafunctional conditions may need to be taken into account or avoided in development of the occlusal scheme. Interocclusal spacing should be adequate and may influence the choice of a screw versus a cement-retained prosthesis. Access for oral hygiene should be included in the prosthetic design.

SITE EVALUATION TECHNIQUE

A technique by Flanagan¹³ to reveal the underlying bone contour is briefly described as follows. First a fast set polyvinyl siloxane (Blu-Mousse, Parkell, Farmingdale, NY) is used to make a dual arch impression of the site (Figure 1). The impression mass is removed and the site length is measured (Figure 2). The impression mass is then bisected faciolingually with a laboratory Bard-Parker knife to give two arch forms of the proposed site (Figure 3). The gingival interocclusal space is measured and will be added to the gingival thickness to give the bone opposing dentition distance (which should be at least 5 mm to allow a cemented type restoration) (Figure 4). The arch form is then traced on paper (in the patient's record), which is in fact, the gingival contour



FIGURES 1–5. FIGURE 1. A dual arch impression is made with a fast set polyvinyl siloxane material to yield an impression mass. FIGURE 2. The site length is measured. FIGURE 3. The impression mass is bisected faciolingually to reveal the arch of the gingival contour. FIGURE 4. The gingival interocclusal dimension is measured. FIGURE 5. The gingival arch form is traced.

of the site (Figure 5). Then, bone sounding is done to find the overlying gingival thickness (Figure 6). These measurements are noted and recorded as points on the tracing (Figure 7). So, each recorded measurement is noted as a point under the arch tracing. The points are then connected to give another form which is an approximation of the underlying bone contour (Figure

7). The faciolingual bone dimension can now be measured on the tracing to give the surgeon information as to appropriate implant sizing diameter. A too-large diameter implant or too thin of a ridge may produce a dehiscence (Figure 8). The 5-mm level is the depth to which the implant should be placed to avoid subsequent exposure of the implant threads due to

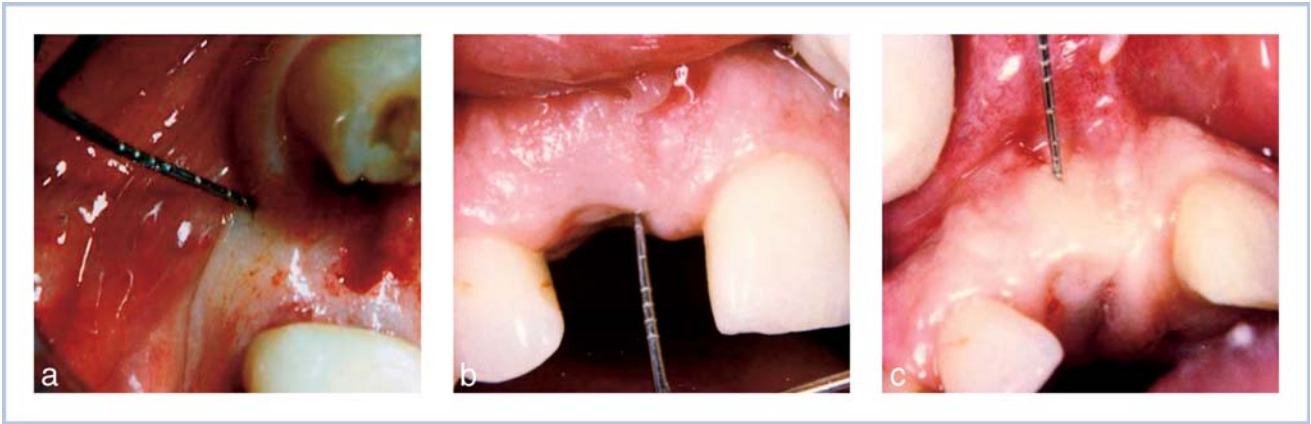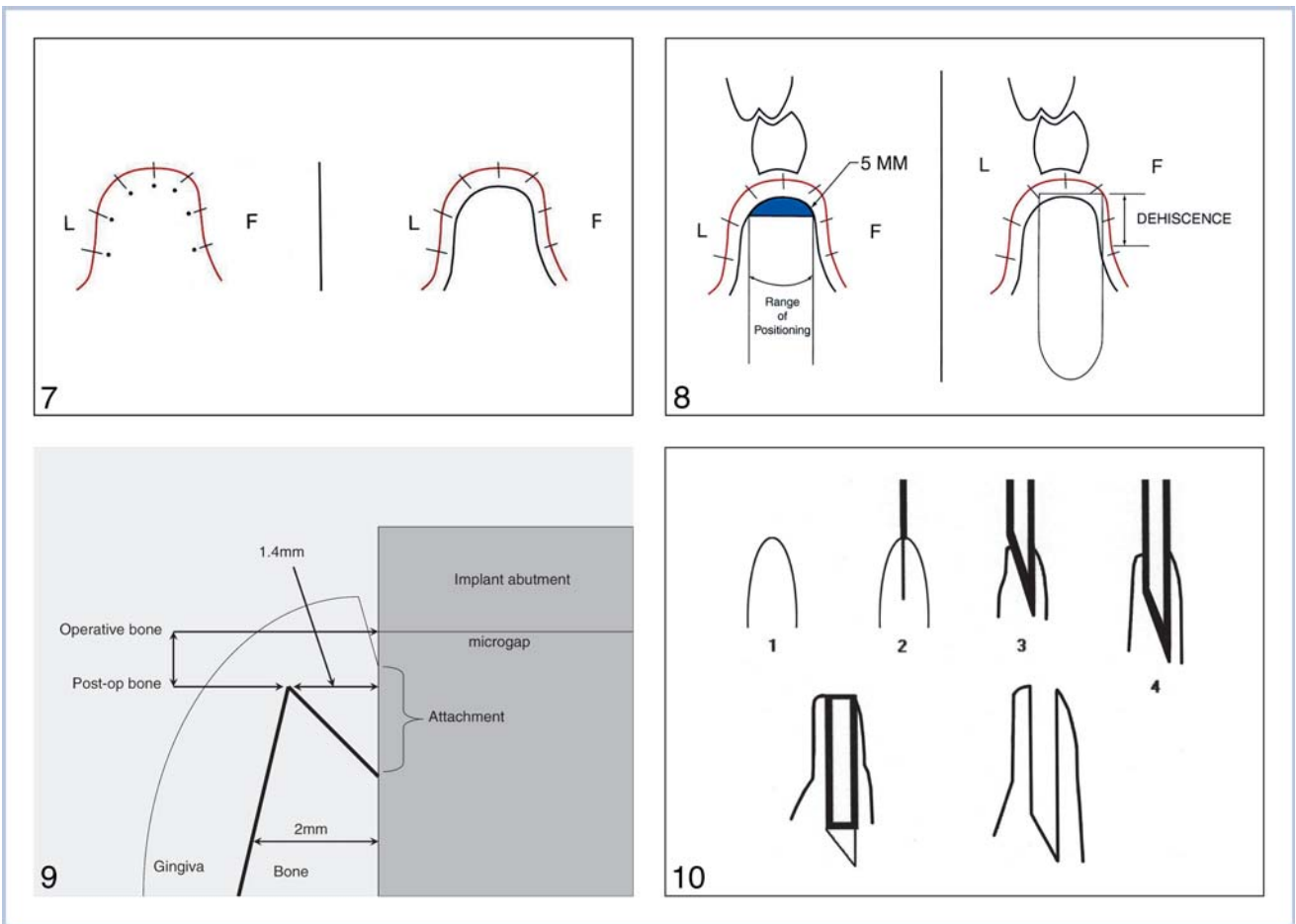


FIGURE 6. Bone sounding is done to measure the site overlying gingival thickness.

resorption of thin bone (Figure 9). A 1.4-mm osseous gap may be produced from resorption of thin bone.¹⁴

Implant companies have transparencies that depict their array of available implants. The transparency can

be placed over the tracing to ascertain which implant size is most appropriate for the bone site. Dehiscences, fenestrations, and a range of positions can be predicted and planned for in the treatment (Figure 8). Osteoto-



FIGURES 7–10. FIGURE 7. The gingival thicknesses are noted as points under the traced gingival arch and the dots connected to demonstrate an approximation of the underlying bone contour. FIGURE 8. A 5-mm width is measured on the drawing and a sizing transparency available from implant companies is placed over the drawing to approximate implant size and fit in the available volume. FIGURE 9. Postoperative loss of thin bone to a gap of 1.4 mm can expose the implant threads. FIGURE 10. An overview of the flapless ridge expansion technique using osteotomes.

TABLE 1

Various bone densities may require differing implant installation techniques and site development. This assumes adequate height and length of the implant bone site

	Bone Type I	Bone Type II	Bone Type III	Bone Type IV
Class 1 >5 mm	Flapless or punch incision	Flapless or punch incision	Flapless or punch incision	Flapless or punch incision and osteotome compression or grafting
Class 2 2–5 mm	Ridge expansion and/or bone flap	Ridge expansion	Ridge expansion	Ridge expansion and osteotome compression or grafting
Class 3 <2 mm	Extracortical augmentation	Extracortical augmentation	Extracortical augmentation	Extracortical augmentation

mies can be avoided that produce thin facial and/or lingual cortices that may resorb and expose the implant threads.

Sites that accept multiple implant placements may have computerized tomography (SimPlant, Columbia Scientific, Columbia, Md) to reveal bone dimensions and quality (Hounsfield units) that can facilitate and expedite the operative procedure. A diagnostic wax-up of the proposed final restoration may be important for a successful outcome.

SURGICAL GUIDE

Even in small sites, especially in the esthetic zone or in access-difficult sites, a surgical guide can be important for proper implant placement for an esthetic and functional restoration. In the esthetic zone an implant that is as little as 0.5 mm askew may result in a compromised outcome. A simple vacuum-formed guide may insure appropriate implant positioning.

SITE BONE WIDTHS 5 MM OR GREATER

These sites with 5 mm of faciolingual bone width or greater usually require little or no site development (Table 1). A small envelope incision or tissue punch can be made to expose the bone for the osteotomy. The appropriate drills are used to create an osteotomy that accepts the appropriate implant. Primary closure is not required for osseointegration to occur. However, initial implant immobility is required. An insertion torque of 35 to 45 Ncm is desirable.

Even with adequate bone at the crest there may be a facial undercut of bone that can produce an implant fenestration, which may be augmented intraoperatively. The undercut may be demonstrated by the aforementioned bone sounding tracing technique. Additionally, during the osteotomy, by placing the thumb and forefinger on the facial and lingual cortices the surgeon may be able to sense the spinning drill that may indicate a cortical fenestration or dehiscence. Adequate attached gingiva may be required for

a successful long-term restorative outcome. At least 4 mm of preoperative attached gingiva is needed to support the percutaneous implant, to help prevent a coronal peri-implantitis that may lead to an implant failure. Gingival augmentation can be accomplished by free gingival, pedicle, or acellular dermal grafting. Inadequate bone density may be addressed by compressing bone of the osteotomy with osteotomes for better implant stability. Press fit implants may enjoy an advantage in osteotome-compressed less dense bone sites. Alternatively, these sites may be grafted to increase bone quantity for later site condensation and implant placement.

When placing implants into ridges that appear to be 5 mm near the crest, it may be important to place the implant deeper than the perceived bone crest. This caveat should be heeded in parabolic shaped ridges. The site evaluation technique as previously described can reveal such a ridge contour (Figure 9). An implant placed in a parabolic site will be encased in very thin bone at the collar. This thin bone is very susceptible to resorption which may expose the implant threads. Bone resorption may cause a circumferential 1.4-mm gap at the implant collar and subsequent vertical bone loss thus exposing the implant threads.

SITES 2 TO 5 MM OF BONE WIDTH

Ridge expansion or split ridge techniques can be employed to increase the available bone in sites less than 5 mm in width.^{15,16} Sites 4 to 5 mm in width can be treated as deemed appropriate by the surgeon. The ridge is surgically split, separated, and then apically drilled to accept an implant. The split produces two cortices that provide facial and lingual bone walls that are conducive for bone repair and osteogenesis in the created gap. These walls contain viable osteocytes with a blood supply. Ridge expansion should only be attempted by experienced implant surgeons.

The crest of the ridge is found by first making the envelope incision and then undermining the facial and lingual edges with the tip of the scalpel (#15) to sense the crest in the "mind's eye" of the surgeon (Figure 10).

Once the bone crest has been ascertained, the crest is scored with the scalpel. The scalpel is then carefully and gently malleted into the crest, taking care to keep the blade between the cortices. The blade is taken to the hilt. The blade is removed by moving it mesiodistally only. Moving the blade faciolingually will likely cause it to fracture. If fracture does occur, the remaining blade fragment can be removed with a mosquito hemostat or Steiglitz forceps, failing that, cortical bone may be removed with a very small bur (#330 SS White) to access a purchase. Next, a small channel former (Sun Coast, St Petersburg, Fla) or DF osteotome (D. Flanagan, Willimantic, Conn) is placed in the slot created by the scalpel blade and gently and carefully malleted into the bone to enlarge the slot and deform the facial cortical bone toward the facial (Figure 11).¹⁷ This deformation should be made in the crest portion of the bone. It does not need to progress into the deeper areas of the bone. Only the coronal of the narrow ridge needs to be split and deflected to the facial. The site is now ready for the conventional implant drilling sequence and implant installation (Figures 12–14). Thin facial and lingual cortices may result in thinner ridges. The selected implant may need to be set deeper than usual to compensate for any resorption of thin bone that may occur (Figure 9). Less dense bone may require grafting and subsequent implant placement.

This technique is better suited for bone densities of the type D-II, -III, and -IV (Misch). Type D-I (Misch) bone density may preclude a flapless ridge expansion. The trauma induced during a ridge expansion of this very dense bone, especially in difficult access and posterior locations may result in bone damage or excessive patient trauma. Site development may be necessary here. Patients may require sedation for this procedure.¹⁸

Ridge expansion takes advantage of the sacrificial bonds peculiar to the collagen polymer that comprises the organic portion of bone. The collagen polymer has atomic bonds that are located within and between the main collagen chain that break under force but allow the main backbone of the polymer to remain intact.^{19,20} This quality gives bone toughness under deformation. This ability to withstand some deformation without complete fracture (greenstick fracture) allows the ridge expansion technique. In the flapless technique, the periosteum is intact and thus contains the bone and provides a blood supply for healing. Interestingly, the periosteal blood supply to the mandible is more important in the anterior while the osseous supply from the inferior alveolar artery is more important distal to the mental foramen. Additionally, the palatal and lingual

cortices are generally thicker and more resistant to deformation than the facial cortices thus providing bracing for the facial cortical deformation (Richard Metzler, PhD, written communication, September 24, 2005).

SITES OF 2 MM OR LESS BONE WIDTH

Theoretically, a 2-mm-wide bone width can be expanded to accept an implant. However, this thin bone may be subject to postoperative resorption at the crest that can compromise the restoration and the implant. Ridge expansion of a 2-mm-wide ridge can be difficult at best because it is usually comprised of only cortical bone. Theoretically, a narrow site may be split and expanded but practically these sites are difficult to treat with the presently available instrumentation. These narrow sites can be dense cortical bone that do not section easily. These thin bone sites may be best extracortically augmented with a flap procedure.

FLAPLESS RIDGE EXPANSION FOR MULTIPLE IMPLANT PLACEMENTS

The same principles apply to single placement as to multiple placements (Figure 15). However, issues of morbidity and esthetics may arise.^{14,21} An interimplant space of 3 mm should be considered for bone blood supply and to minimize crest resorption. The larger operative site may expose the hard and soft tissue to more trauma and bacterial invasion. Controlling and managing the hard and soft tissue may be more difficult. Implant positioning may be difficult to control and the surgeon must be diligent. Additionally, bone graft material may be needed to fill gaps larger than 1.5 mm between implants.

The problem of lip support may need to be addressed with long span sites. Traumatic bone loss or resorption over time may eliminate osseous volume that maintains the lips in the facial contour. This may need to be replaced in the prosthetic design.

Very small diameter (1.8-mm) implants may be placed flaplessly. These implants may be used in more dense bone and in tandem for prosthetic support (Figures 16 and 17).

COMPLICATIONS

Infection is unusual and may be controlled by use of antibiotics and local debridement or implant removal.

Malposition of the implant may not be compatible with a successful prosthetic outcome. Steps should be

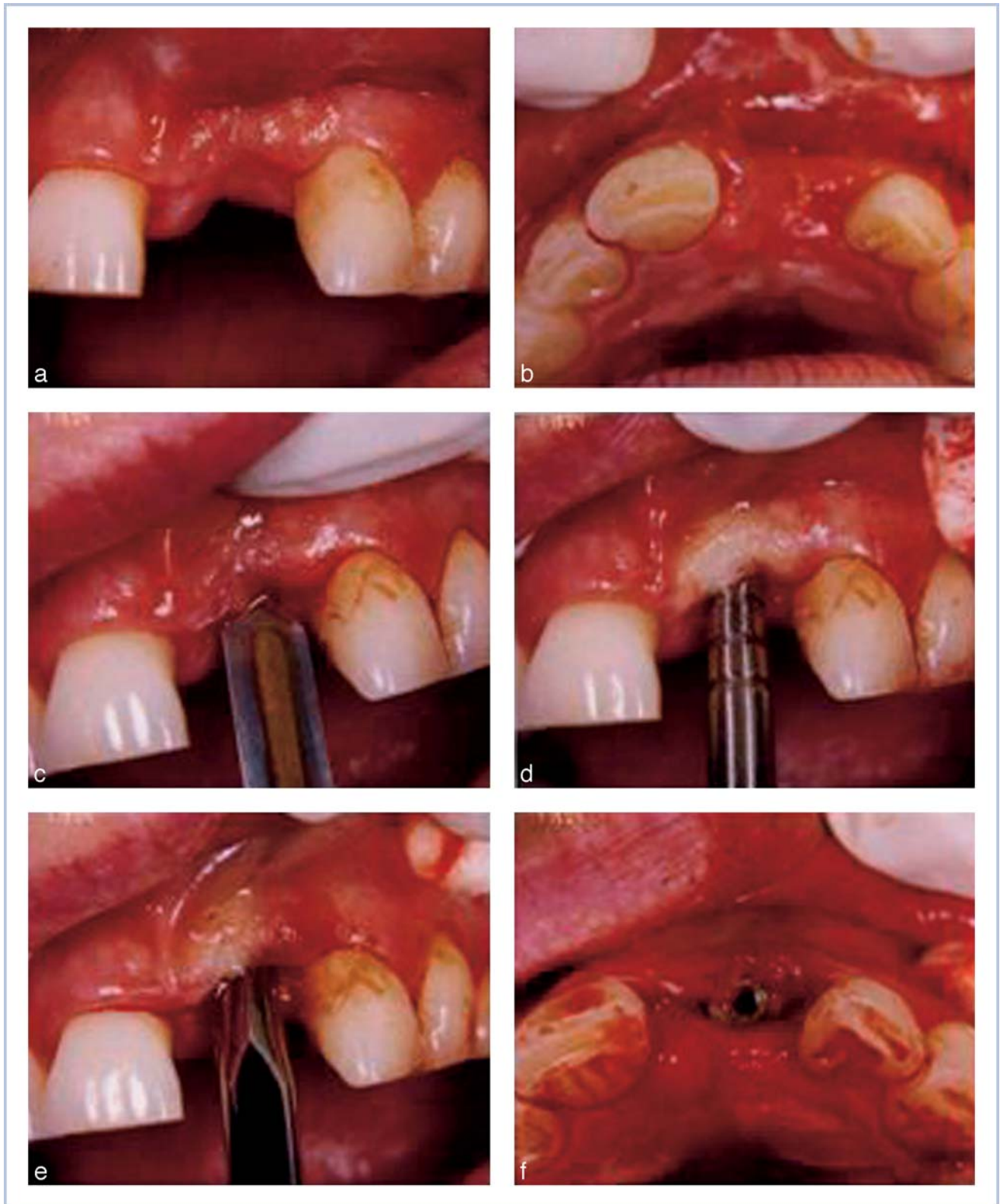
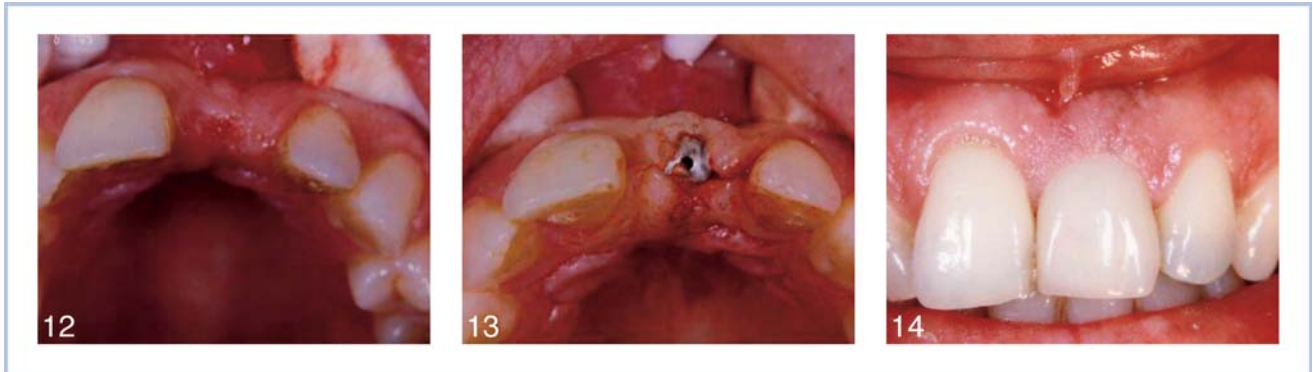

FIGURE 11. Flapless ridge expansion is accomplished by gradually splitting and separating the cortices with a scalpel, a channel former, or osteotome.

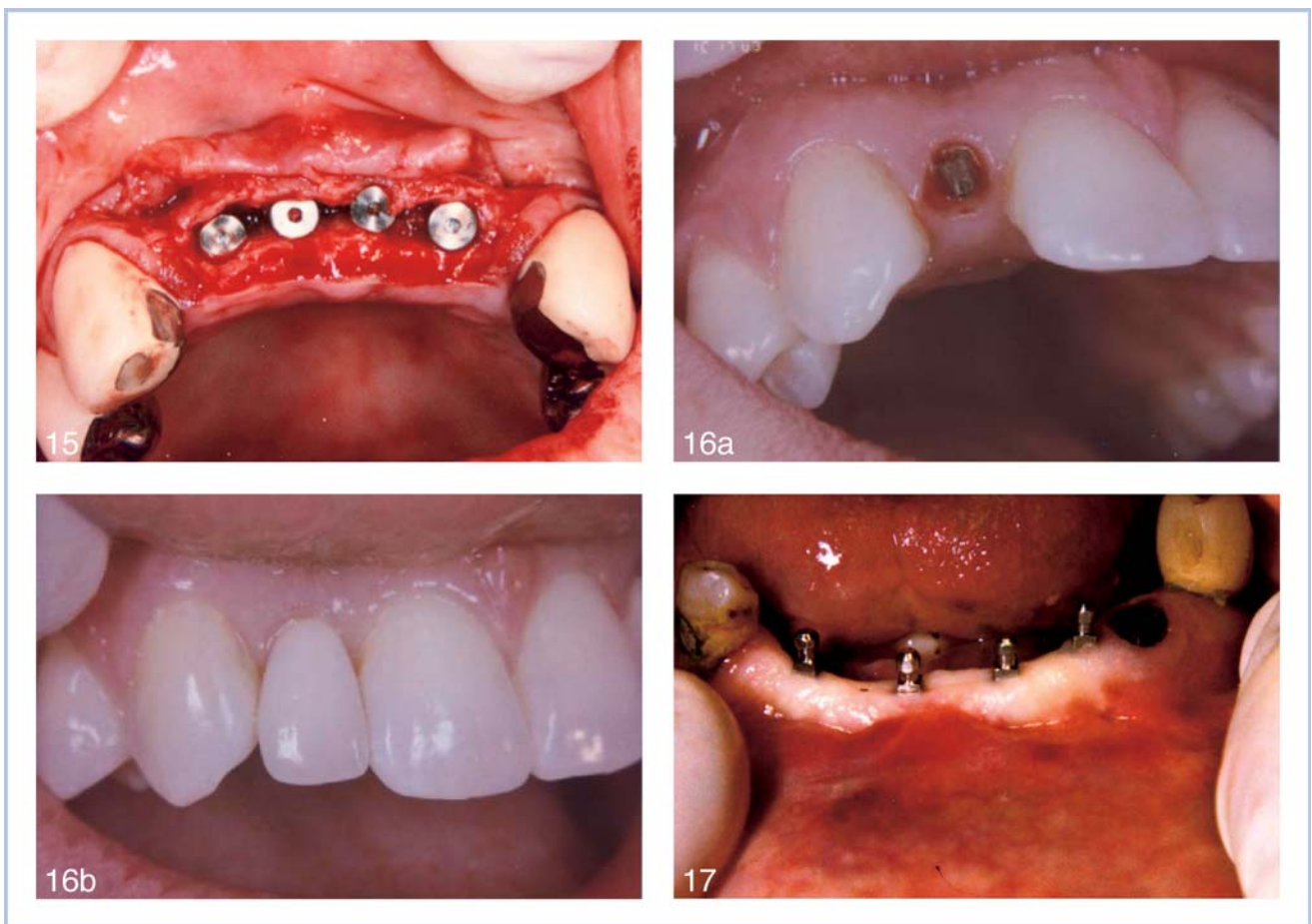

FIGURES 12–14. FIGURE 12. #9 atrophic site. FIGURE 13. #9 site expanded with implant in place. FIGURE 14. #9 crown in place.

taken to insure appropriate implant placement for a functional and esthetic result. Intraoperative repositioning of the scalpel, osteotome, or implant may be easier during surgery than later dealing with the result.

Alternatively, if the malposition is too great, grafting, healing, and a later re-entry may be appropriate.

Benign positional vertigo may occur in patients subjected to osteotome ridge expansion.¹⁰ The force



FIGURES 15–17. FIGURE 15. A flap is raised to demonstrate the split ridge for a multiple implant replacement. FIGURE 16. Very small diameter (mini) implants may be placed flaplessly. FIGURE 17. Very small diameter (mini) implants may be placed flaplessly in multiples.

of the surgical mallet may induce a dislodgement of labyrinthine otoliths producing a feeling of vertigo in the patient during head-turning movements. This condition is usually self limiting or may be treated by head maneuvers to reposition the otoliths.

CONCLUSIONS

Patient and site selection are primary concerns for flapless implant surgery. There is a technique available using a fast set polyvinyl siloxane material for revealing the approximate contour of the underlying bone of a proposed implant site. Assuming appropriate length and height of a proposed implant site, the suggested criteria for flapless implant placement are an appropriate patient, adequate or expandable bone width (ridge expansion, split ridge), adequate or augmentable attached gingiva, and adequate or condensable bone density for implant immobility (osteotome compression).

These criteria may be necessary for a successful flapless approach. A flapless approach can be less traumatic and time consuming, have fewer complications and faster soft tissue healing, and be esthetically and restoratively appropriate. The armamentarium for flapless implant placement can include osteotomes in sites where the bone width is less than 5 mm or in sites where there is less bone density. Careful directing of the scalpels and osteotomes should be observed to prevent malposition of the implant. Surgical guides are very useful for implant positioning. There are proposed three classes of sites based on assumed adequate length and height: Class 1, ridge width of 5 mm or more; Class 2, ridge width of 2 to 5 mm; and Class 3, ridge width of 2 mm or less. Optimal sites have at least 5 mm of bone width and adequate length and height, bone density, and attached gingiva. Implants may need to be placed slightly deeper in sites with parabolic shaped ridges to avoid crestal bone loss and subsequent implant thread exposure. Sites that are 2 to 5 mm wide that have less dense bone and/or inadequate attached gingiva that may be correctable or augmented can be considered for flapless implant placement. Bone widths of 2 mm or less may not be appropriate for a flapless approach and require open flap augmentation or site development. Single and multiple sites can be treated flaplessly. Infection is unusual but may be controlled with antibiotic coverage, debridement, or implant removal. Labyrinthine concussion can be a postoperative complication of osteotome use.

REFERENCES

1. Sclar A. The importance of site preservation. In: Sclar A, ed. *Soft Tissue and Esthetic Considerations in Implant Therapy*. Chicago, Ill: Quintessence Publishing Co; 2003:76–79.
2. Tarnow DP, Eskow RN. Preservation of implant esthetics: soft tissue and restorative considerations. *J Esthet Dent*. 1996;8:12–19.
3. Kraut RA. Selecting the precise implant site. *J Am Dent Assoc*. 1991;122:59–60.
4. Verstreken K, Van Cleynenbreugel J, Marchal G, Naert I, Suetens P, Van Steenberghe D. Computer assisted planning of oral implant surgery: a three dimensional approach. *Int J Oral Maxillofac Implants*. 1996;11:806–810.
5. Stanford CM. Application of oral implants to the general dental practice. *JADA*. 2005;136:1092–1100.
6. Moy PK, Medina D, Vivek S, Aghaloo TL. Dental implant failure and associated risk factors. *J Oral Maxillofac Implants*. 2005;20:569–577.
7. Misch CE, ed. *Contemporary Implant Dentistry*. 2nd ed. St Louis, Mo: CV Mosby; 1999:33–237.
8. Gruica B, Wang H-Y, Lang N, Buser D. Impact of IL-1 genotype and smoking status on the prognosis of osseointegrated implants. *Clin Oral Implants Res*. 2004;15:393–400.
9. Campos MI, Godoy dos Santos MC, Trevilatto PC. Interleukin-2 and interleukin-6 gene promoter polymorphisms and early failure of dental implants. *Implant Dent*. 2005;14:391–396.
10. Flanagan DF. Labyrinthine concussion and positional vertigo after osteotome site preparation. *Implant Dent*. 2004;13:129–132.
11. Cosme DC, Baldisserotto SM, Canabarro SA, Shinkai RS. Bruxism and voluntary bite force in young dentate adults. *Int J Prosthodont*. 2005;18:328–332.
12. Szmukler-Moncler S, Salama H, Reingewirtz Y, Dubrulle JH. Timing of loading and effect of micromotion on bone-dental implant interface: review of experimental literature. *J Biomed Mater Res*. 1998;43:192–203.
13. Flanagan DF. A method for estimating preoperative bone volume for implant surgery. *J Oral Implantol*. 2000;26:262–266.
14. Tarnow DP, Cho SC, Wallace SS. The effect of interimplant distance on the height of interimplant bone crest. *J Periodontol*. 2000;71:546–549.
15. Summers RB. The osteotome technique: part 2—the ridge expansion osteotomy (REO) procedure. *Comp Contin Edu Dent*. 1994;XV:422–434.
16. Borgner RA, Kirkos LT, Gougloff R, Cullen MT, Delk PL. Computerized tomography scan interpretation of a bone expansion technique. *J Oral Implantol*. 1999;25:102–108.
17. Flanagan DF. Cortical bone spreader osteotome and method for dental implant placement. *J Oral Implantol*. 28:296–296.
18. Flanagan DF. Oral triazolam sedation in implant dentistry. *J Oral Implantol*. 2004;30:93–97.
19. Vashishth D, Tanner KE, Bonfield W. Contribution, development and morphology of microcracking in cortical bone during crack propagation. *J Biomech*. 2000;33:1169–1174.
20. Thompson JB, Kindt JH, Drake B, Hansma HG, Morse DE, Hansma PK. Bone indentation recovery time correlates with bond reforming time. *Nature*. 2001;414:773–776.
21. Tarnow D, Elian N, Fletcher P, et al. Vertical distance from the crest of bone to the height of the interproximal papilla between adjacent implants. *J Periodontol*. 2003;74:1785–1788.