



Todd E. Shatkin, DDS

Alysa Brooke Sadkin

Jared Shatkin

A Mini Dental Implant Alternative to All-on-Four

INTRODUCTION

Aesthetic dentistry has evolved throughout the past few decades, specifically in the field of implantology. Patients are preferring endosseous procedures to traditional dentures and other removable prostheses to increase stability and comfort, and to decrease pain.¹ Conventional implants require several procedures involving multiple appointments and upwards of a year until completion; although some newer techniques promote a faster completion time. The "All-on-4" technique is an immediate conventional implant procedure in which 4 large-diameter implants (2 in the anterior and 2 in the posterior) are inserted at a 45° angle to take advantage of the available bone and to reduce the need for bone augmentation and/or sinus lift.²

According to Nobel Biocare's All-on-4 treatment concept manual, a minimum of 5.0 mm in bone width and 8.0 mm in bone height is necessary to begin the procedure.³ (All-On-4 is a registered patent owned by Nobel Biocare developed together with Paulo Malo, DDS, PhD, at the MALO CLINIC.) Though the All-on-4 technique claims to eliminate the need for bone augmentations and sinus lifts, these procedures cannot always be eliminated if the bone quantity does not meet the requirements due to the large diameter of a conventional implant.^{1-2,4} While the All-on-4 technique offers acceptable support with 4 implants, the endosseous procedure is still invasive and time consuming compared to the immediate and early loading procedures used with mini dental implants. The All-on-4 often requires a minimum of 4 to 6 months before the final restoration is fully completed.⁴ In addition, if one of the 4 implants fails to integrate or fails following placement of the restoration, the entire restorative procedure must be restarted, additional surgery performed, and the restoration remade. Considering the average fee for All-on-4 is in the range of \$30,000 to \$40,000 per dental arch, this technique is not affordable for most dental patients.

Technique Using Mini Dental Implants Recently Introduced
Immediate and early loading endosseous procedures with mini dental implants are more desirable to patients in many instances because of the speed of completion, an affordable fee, and it is a less invasive procedure with reduced postoperative discomfort.⁴ The small size of the mini dental implants (available in several lengths and diameters) eliminates the need for bone augmentation and/or sinus lifts. This is because the mini dental implant can be angled into available bone rather than augmenting the bone.⁴ The Shatkin Fabricated Implant Restoration and Surgical Technique (F.I.R.S.T.) (patent USPTO

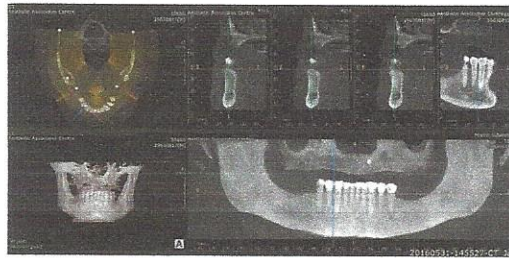


Figure 1. CBCT scan from consult.

No. 7,108,511 B, September 2006; developed by Todd E. Shatkin, DDS) provides for mini dental implant(s) to be placed and restoration(s) cemented in one patient visit.⁵ The most recent innovation, FIX on SIX (FIX on SIX is a registered trademark owned by Shatkin F.I.R.S.T., developed by Todd E. Shatkin, DDS) offers a combination of the Shatkin F.I.R.S.T. technique using 6 to 8 (or 10) mini dental implants with a 12-unit fixed detachable zirconia full-arch restoration with o-ring implant housings. The restoration is only removed at recall cleanings as the dentist is able to snap off the FIX on SIX restoration. The hygienist will then completely clean the implants, the restoration, and the surrounding tissue and easily reinsert the restoration without patient discomfort. This FIX on SIX procedure is completed in a fraction of the patient's and the dentist's time as required by the All-on-4 technique. The success rates of the immediate loading mini dental implant endosseous procedures are competitive with the All-on-4 technique. If one of the mini dental implants were to fail with a FIX on SIX restoration, the failed mini implant can be easily replaced with a new mini implant and o-ring housing placed in the same or different location. In addition, the FIX on SIX restorations are considerably more affordable than the All-on-4 with approximately a 50% to 66% savings. Consequently, the FIX on SIX restorations are more desirable to the patient due to their affordability, greater comfort, reduced treatment time, and the less invasive nature of the procedure.

Fixed partial dentures are commonly supported by mini dental implants to provide a natural, aesthetic appearance for the patient. In recent years, zirconium dioxide (zirconia) frameworks have been used in dentistry for fixed restorations.⁶ The introduction of zirconia has allowed the fabrication of metal-free prostheses via CAD/CAM technology. The result is improved aesthetics with increased success and reliability.⁷ There is also

continued on page 88

A Mini Dental Implant Alternative...

continued from page 86

evidence that there is less plaque accumulation on zirconia, helping to prevent postoperative gingival problems.⁸ The architecture of these zirconia-based prosthetics enables superior strength and chewing resistance on the posterior teeth relative to other ceramics.^{5,9} Due to its favorable chemical composition and mechanical properties, clinicians have been eager to use zirconia in implant-supported restorations after its continued success in tooth-supported restorations.¹⁰

The following case study (Figures 1 to 15) presents a clinical report of mini dental implants with the FIX on SIX technique. The use of 6 to 8 (or 10) mini dental implants allows for the functional and aesthetically pleasing zirconia fixed prosthesis to be supported. Using CBCT technology, a zirconia prosthetic restoration was created and fixed over Shatkin F.I.R.S.T. mini dental implants (by Intra-Lock) using o-ring housings processed into the zirconia framework.

CASE REPORT

A 56-year-old male patient with an upper denture presented for a consult on May 13, 2016. He had come in after seeing the Shatkin F.I.R.S.T. television marketing campaign. At the consult, our new patient had a CT scan (using our Shatkin F.I.R.S.T. CBCT machine for pre-op and post-op scans) (Figure 1), treatment plan, and impressions taken for a FIX on SIX detachable-removable bridge (Figure 2). To minimize the discomfort and to eliminate the existing issues with his old denture, a zirconia bridge was prescribed and designed to fit on the mini dental implants that would be placed. Zirconia was chosen as the fabrication material due to its strength and durability and resistance to plaque. A treatment plan for placing 10 Mini Drive-Locks (MDL [Intra-Lock]) in the maxillary arch using the Shatkin F.I.R.S.T. technique for mini dental implant placement was chosen. He was asked to return in 2 weeks for his procedure and placement of a temporary bridge.

About one month later, the patient returned, signed the consent form, and treatment was begun. A local anesthetic (2 carpules of Septocaine with epinephrine [Septodont]) was administered. A CT guided stent from Shatkin F.I.R.S.T. Lab was used in this case. The position of the 10 implants

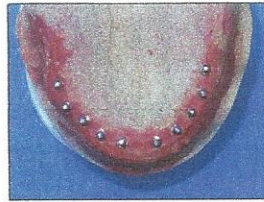

Figure 2. Dental model made using the impression taken at the consult appointment.

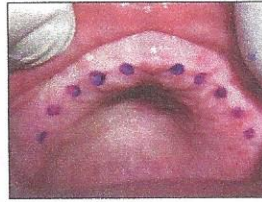


Figure 3. The tissue was marked using a Thompson marking pen through the surgical guide stent to get a visual for placement of the mini implants.

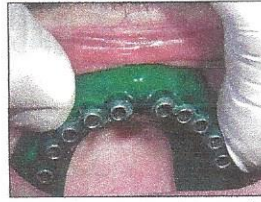

Figure 4. Holding the CT guided stent still in preparation of placing mini implants.

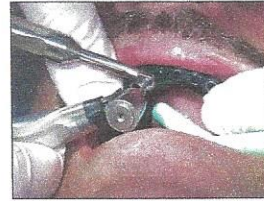

Figure 5. Using the Shatkin F.I.R.S.T. Pilot Drill Guide and 20:1 MDL Contra Angle Driver to make Pilot hole.

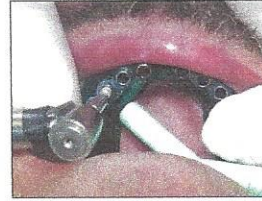

Figure 6. Placing mini dental implant through the CT guided stent with 20:1 handpiece.

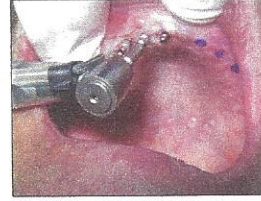

Figure 7. Fully seating the mini dental implant after removing the surgical guide stent.

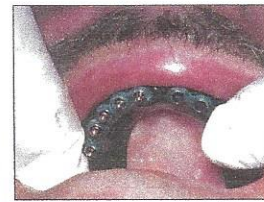

Figure 8. After placing the first 5 mini dental implants, the clinician checks for proper alignment.

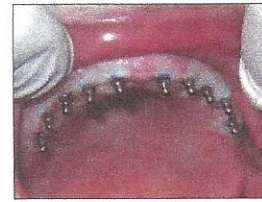

Figure 9. The 10 mini dental implants were placed in the maxilla. Notice the bottom of the square is level with the gingiva, and the ball and square are above tissue.

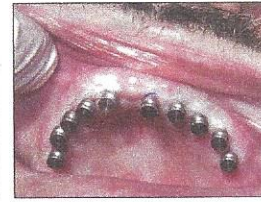

Figure 10. Placing all 10 micro metal housings on the mini dental implants.

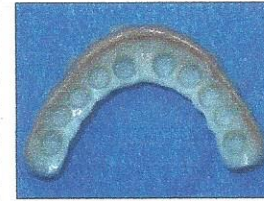

Figure 11. Final restoration before placement of o-rings.

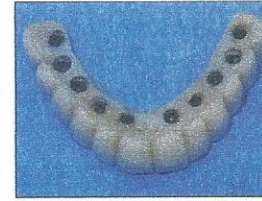

Figure 12. Fixed on 10 final restorations with o-rings placed in restoration.

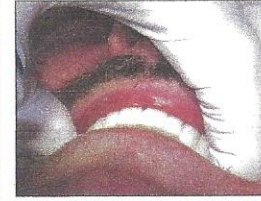

Figure 13. Verification of final zirconia restoration fit.

was marked using a Thompson marking pen and the CT guided stent (Figure 3). Nine Intra-Lock mini dental implants were used on the upper maxillary arch, size 25 mm/15 mm at Nos. 3 to 6 and 9 to 13; and one 25 mm/11 mm for No. 8. The CT-guided stent was used throughout the procedure (Figure 4), removing it between final placement of each implant, using the patented F.I.R.S.T. technique. When

finished placing all 10 implants using the Shatkin F.I.R.S.T. procedure, the housings were placed, and A1 Luxa-temp (DMG America) was used to create the temporary bridge. The patient liked the temporary. Impressions were taken and sent to the Shatkin F.I.R.S.T. Lab (Figures 5 to 8). Two prescriptions (penicillin 500 mg, Norco 5/325) were sent to the patient's pharmacy, and an appointment for 2 weeks was made

for the delivery of the permanent FIX on SIX detachable-removable bridge.

Two weeks later, the patient returned, and the temporary was removed. The FIX on SIX detachable-removable roundhouse restoration was then placed (Figures 9 to 12). The FIX on SIX restoration had good aesthetics, and the patient was happy (Figure 13 to 15). The patient was given a Shatkin Water Flosser

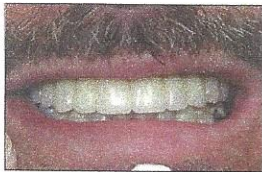


Figure 14. The aesthetics and bite were both checked in the final restoration.

and a Sonicare (Philips Oral Healthcare) toothbrush. These are provided as a part of the treatment to our mini implant patients for optimal home care. These have been very successful hygiene tools to keep the soft tissues healthy and clean between checkups, when the FIX on SIX is removed.

CLOSING COMMENTS

This article presents an alternative to All-on-4 that is less expensive, less invasive and painful, and demonstrates faster results while utilizing zirconia, a strong and biocompatible dental material. FIX on SIX is a beautiful zirconia restoration that can be removed by the clinician while providing the patients with the feel and aesthetics of a fixed prosthesis. Creating a fixed prosthesis that is able to withstand the occlusal forces applied, while providing cosmetic appeal and patient satisfaction, is an enduring task for all dentists.¹¹ Today in dentistry, zirconia has traditionally been used in fixed partial dentures as tooth-supported restorations.^{9,10} With most cases that use zirconia as a fixed restoration, high success rates have been recorded, mostly higher than 95%.⁹ Zirconia's ability to increase the durability of a prosthesis by up to 30% to 40% has made it a good candidate for use in fixed-hybrid cases.¹¹ The use of CT technology increases zirconia's stability in conjunction with decreasing failure rates of these restorations, due to the industrial processing.

In this case study, the patient was dissatisfied with his upper denture because of cracks in the acrylic along the palate, and the dentures were not comfortable to wear, and food would trap under them. By designing a fixed zirconia bridge (FIX on SIX) instead of acrylic dentures or a hybrid acrylic fixed bridge, the patient will no longer have these negative experiences. The use of zirconia instead of acrylic increases durability of the prosthesis while also offering the comfort of fixed restoration and healthier surrounding gingival tissues. ➔

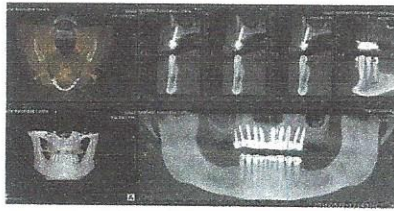


Figure 15. Final CBCT and panoramic radiograph.

References

- Babbush CA, Kutsko GT, Brokloff J. The All-on-Four immediate function treatment concept with NobelActive implants: a retrospective study. *J Oral Implantol*. 2011;37:437-445.
- Jensen OT, Adams MW, Cottam JR, et al. The All-on-4 shelf: maxilla. *J Oral Maxillofac Surg*. 2010;68:2520-2527.
- All-on-4 treatment concept [procedures manual]. Klöten, Sweden: Nobel Biocare Services; 2011.
- Shatkin TE, Petrotto CA. Mini dental implants: a retrospective analysis of 5640 implants placed over a 12-year period. *Compend Contin Educ Dent*. 2012;33(3, special issue):29.
- Larsson C, Vult von Steyern P, Sunzel B, et al. All-ceramic two- to five-unit implant-supported reconstructions. A randomized, prospective clinical trial. *Swed Dent J*. 2006;30:45-53.
- Glauser R, Sailer I, Wohlwend A, et al. Experimental zirconia abutments for implant-supported single-tooth restorations in esthetically demanding regions: 4-year results of a prospective clinical study. *Int J Prosthodont*. 2004;17:285-290.
- Gargari M, Gloria F, Napoli E, et al. Zirconia: cementation of prosthetic restorations. Literature review. *Oral Implantol (Rome)*. 2010;3:25-29.
- Rimondini L, Cerroni L, Carrasi A, et al. Bacterial colonization of zirconia ceramic surfaces: an in vitro and in vivo study. *Int J Oral Maxillofac Implants*. 2002;17:793-798.
- Kornine F, Blatz MB, Matsumura H. Current status of zirconia-based fixed restorations. *J Oral Sci*. 2010;52:531-539.
- Guess PC, Att W, Strub JR. Zirconia in fixed implant prosthodontics. *Clin Implant Dent Relat Res*. 2012;14:633-645.
- Cobb GW Jr, Metcalf AM, Parsell D, et al. An alternate treatment method for a fixed-detachable hybrid prosthesis: a clinical report. *J Prosthet Dent*. 2003;89:239-243.

Dr. Shatkin is a graduate of the University of the Pacific School of Dentistry. He is the president emeritus of the International Academy of Mini Dental Implants and the owner of Shatkin F.I.R.S.T., a mini dental implant specialty laboratory. He practices full-time in Amherst, NY, a suburb of Buffalo. He holds memberships in the ADA, AGD, New York State Dental Society, Eighth District Dental Society, Erie County Dental Society, Metropolitan Dental Study Club, International College of Oral Implantologists, Greater New York Dental Implant Study Group, and American Academy of Cosmetic Dentistry. During last 12 years, he has placed more than 15,000 mini dental implants, utilizing them for denture stabilizations, single and multiple tooth replacements, and for full-arch reconstructions, with a success rate of 95%. Due to his positive experiences using mini dental implants, he developed the patented Fabricated Implant Restoration and Surgical Technique (F.I.R.S.T.). This technique features a mini dental implant with a lab-fabricated, finished single-tooth replacement in one visit, usually accomplished in less than 30 minutes; the same results in less than an hour for 3 to 5 units, and less than 2 hours for a full-

arch restoration, all with minimal or no patient discomfort, affordable fees, and the opportunity for a dentist to significantly build the practice's earning with minimal startup costs. His implant articles have been published in many dental publications, such as *Compendium of Continuing Education in Dentistry*, *Dental Eco-*

nomics, and *DentalTown*. He lectures internationally on mini implants. He can be reached at (716) 839-1700 or via email at the address tshatkin@gmail.com.

Disclosure: Dr. Shatkin is the owner of Shatkin F.I.R.S.T. and developer and patent owner of technologies presented in this article.

Ms. Sadkin graduated from Hobart and William Smith Colleges with a bachelor of science in biochemistry. She is currently a second year dental student at the University of Pittsburgh School of Dentistry. She can be reached via email at abs91@pitt.edu.

Disclosure: Ms. Sadkin reports no disclosures.

Mr. Shatkin is a fourth year pre-dental student at State University of New York at Buffalo. He is majoring in history with a minor in chemistry and plans to attend dental school in the fall. He can be reached via email at the following address: hatk01@mail.buffstate.edu.

Disclosure: Mr. Shatkin reports no disclosures.

FREE Download for All Devices!

Dentistry Today's eBooks feature clinical cases that are of importance to all dental specialties. In addition, the latest products, procedures, and technology are highlighted to keep you and your practice up to date.

DTO eBooks
dentistrytoday.com/ebooks