Are narrow implants a reliable solution?

Can narrow implants be used in the posterior maxillary and mandibular regions to replace premolars and molars? Can the use of narrow implants eliminate the need for grafting in certain circumstances? Drs. Patrick Palacci and Giulia Mancardi examine the literature to answer these questions and more to determine exactly where small-diameter dental implants can be used and whether they are a predictable treatment option.

Feb 8th, 2019

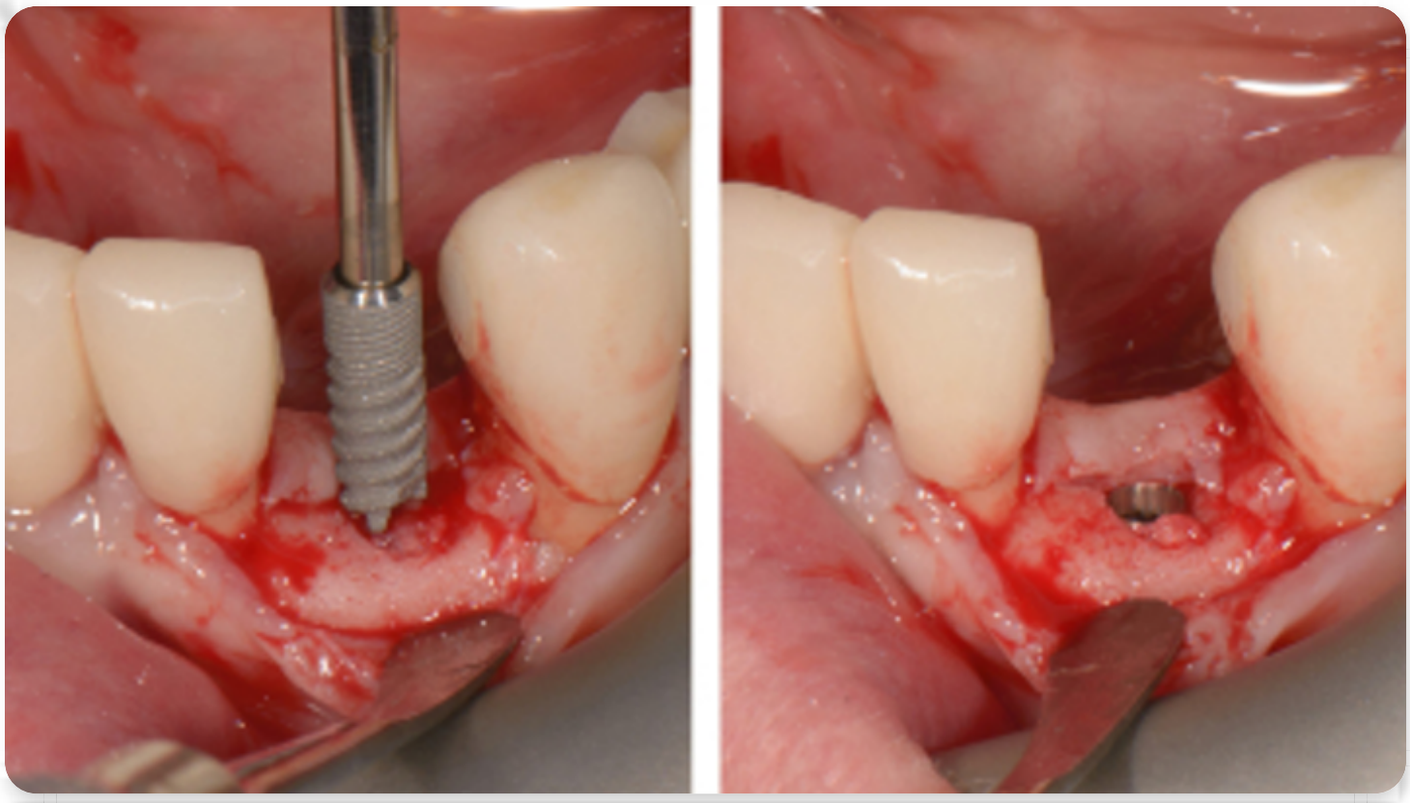

Can narrow implants be used in the posterior maxillary and mandibular regions to replace premolars and molars? Can the use of narrow implants eliminate the need for grafting in certain circumstances? Drs. Patrick Palacci and Giulia Mancardi examine the literature to answer these questions and more

to determine exactly where small-diameter dental implants can be used and whether they are a predictable treatment option.

NARROW IMPLANTS (from 3.5 mm in diameter and less) have been designed for treatment of the anterior maxillary and mandibular regions mainly for the replacement of lower incisors, but not for the replacement of premolars and molars. Concerning these teeth, wider implants are indicated. (1)

At the beginning of the 1990s, due to their mechanical properties, 5 mm diameter implants were considered the ideal implants for the replacement of premolars. A study published in the late 1990s disproved this belief, reporting higher failure rates (18%) for 5 mm diameter implants compared to

3.75 mm and 4 mm wide implants, which yielded 5% and 3% failure rates respectively. (2) Similarly, other authors observed a higher survival rate using 3.75 mm diameter implants rather than adopting wider diameter ones. (3)

Moreover, long-term results show more marginal bone loss around wide-diameter implants than around 3.75 mm or 4 mm diameter implants. (4)

Then, one should ask the following question: do we need more bone and less titanium, or less bone and more titanium? Some authors concluded that narrow implants (2.75 mm to 3.25 mm diameter) could be successfully used as a minimally invasive alternative to horizontal bone augmentation in posterior mandibles for up to one year of function. (5) The logical evidences in such cases would be more bone to promote osseointegration.

In 1998, I started to place narrow implants not only in the anterior areas, but also in posterior maxillary and mandibular regions in order to replace premolars and molars. I began to treat partially edentulous patients with a high success rate.

Following this concept, I extended the indications to fully edentulous patients, having in mind:
• simplification of the surgical procedures • reduced grafting procedures • reduced morbidity and first complications • reduced postsurgical problems

I immediately found an increasing number of cases to be treated in this way. From 1998 to 2008, I placed 824 narrow implants, with a success rate of 98.5%. From 2009 to 2016, I placed 4,266 narrow implants, multiplying the number of narrow implants by nearly six. During these years, in my clinical experience, I found:

• a high success rate • a very stable marginal bone level • one implant fracture

In the presence of narrow ridges, the use of narrow implants may avoid grafting procedures in certain circumstances. Narrow implants can be used in the posterior maxilla with or without sinus elevation, in the posterior mandibula in the presence of horizontal bone loss, and in areas with thin ridges.

Placement of a narrow implant in the anterior maxillary region. This is the primary indication for a narrow implant.

Placement of narrow implants. In a full-arch restoration in the presence of alveolae and thin ridges, narrow implants allow the placement of more biomaterial in the alveolae for ridge preservation. Bone grafting will be avoided in the presence of the ridges.Postsurgical x-ray. Eight narrow implants placed with immediate loading and a temporary bridge in place.

Literature review

When narrow implants were placed in both posterior jaws and the values for marginal bone resorption at one, five, and 10 years were measured, they were within the accepted standard success criteria for dental implants. Regarding the implant failures, the majority occurred in the first six months of function, following the pattern for standard-diameter implants. (6) A recent systematic review reports average survival rates of mini-implants (1.8 mm to 2.9 mm diameter) and narrow implants (3 mm to 3.5 mm diameter) as 98% and 98% respectively, while the average success rates were 93% and 96% respectively. The average peri-implant bone loss after 12, 24, and 36 months was 0.89 mm, 1.18 mm, and 1.02 mm for mini-implants and 0.18 mm, 0.12 mm, and -0.32 mm for narrow implants. Both mini-implants and narrow implants showed adequate clinical behavior as overdenture retainers and clinical outcomes similar to standard implants. The narrow implants also showed a higher survival rate for the studies with higher follow-up time, and they present a better long-term predictability than the mini-implants when conventional loading is applied. (4) Another review concludes that survival rates reported for narrow implants are analogous to those reported for standard-width implants. These survival rates did not appear to differ between studies that used flapless and flap-reflection techniques. The failure rate appeared to be higher in shorter than in longer ones in the studies in which the length of the failed implants was reported. Narrow implants could be considered for use with fixed restorations and mandibular overdentures, since their success rate appears to be comparable to that of regular-diameter implants. (7) Some authors state that using small-diameter implants is a treatment option as predictable as using standard-diameter implants. They summarize their findings as follows: (8)

•**The medium-term prognosis of narrow implants** is comparable to that of standard-diameter implants followed up in the present study. Therefore, the high reliability of small-diameter implants is confirmed. • **Standard- and narrow-implant prognoses** were influenced by peri-implant bone infection more than biomechanical factors, such as implant overloading. • **Peri-implant bone resorption** was not significantly influenced by different implant diameters (3.3 mm and 4.1 mm). • **Bone quality** seems to be an important prognosis factor both for standard- and small-diameter implants; spongy bone (type 4) may increase implant failures. • **Survival of standard and narrow implants** does not seem to be affected by implant location.

Conclusion

Narrow implants can be used in almost every area, except the posterior maxilla/mandibula with a limited bone height. The use of narrow implants is a safe and reliable technique with no problems in relation to function and esthetics.

References

1. Davarpanah M, Martinez H, Tecucianu JF, Celletti R, Lazzara R. Small-diameter implants: indications and contraindications.*J Esthet Dent*. 2000;12(4):186-194.

2. Ivanoff CJ, Gröndahl K, Sennerby L, Bergström C, Lekholm U. Influence of variations in implant diameters: a 3- to 5-year retrospective clinical report.*Int J Oral Maxillofac Implants*. 1999;14(2):173-180.

3. Shin SW, Bryant SR, Zarb GA. A

retrospective study on the treatment outcome of wide-bodied implants.*Int J Prosthodont*. 2004;17(1):52-58.

4. Marcello-Machado RM, Faot F, Schuster AJ, Nascimento GG, Del Bel Cury AA. Mini-implants and narrow diameter implants as mandibular overdenture retainers: A systematic review and meta-analysis of clinical and radiographic outcomes.*J Oral Rehabil*. 2018;45(2):161-183. doi:10.1111/joor.12585.

5. Grandi T, Svezia L, Grandi G. Narrow implants (2.75 and 3.25 mm diameter) supporting a fixed splinted prostheses in posterior regions of mandible: one-year results from a prospective cohort study.*Int J Implant Dent*. 2017;3(1):43. doi:10.1186/s40729-017-0102-6.

6. Maló P, de Araújo Nobre M. Implants (3.3

mm diameter) for the rehabilitation of edentulous posterior regions: a retrospective clinical study with up to 11 years of follow-up.*Clin Implant Dent Relat Res*. 2011;13(2):95-103. doi:10.1111/j.1708-8208.2009.00188.x.

7. Sohrabi K, Mushantat A, Esfandiari S, Feine J. How successful are small-diameter implants? A literature review.*Clin Oral Implants Res*. 2012;23(5):515-525. doi:10.1111/j.1600-0501.2011.02410.x.

8. Romeo E, Lops D, Amorfini L, Chiapasco M, Ghisolfi M, Vogel G. Clinical and radiographic evaluation of small-diameter (3.3-mm) implants followed for 1-7 years: a longitudinal study.*Clin Oral Implants Res*. 2006;17(2):139-148. doi:10.1111/j.1600-0501.2005.01191.x.

Author's note: Dental professionals can hear

Dr. Palacci's full presentation, "Narrow Implants: A Reliable Solution?" by attending the Academy of Osseointegration's 2019 Annual Meeting, "Current Factors in Clinical Excellence," which will be held March 13–16, 2019, at the Walter E. Washington Convention Center in downtown Washington, DC. Dr. Palacci will present his topic during the AO's plenary morning session on Saturday, March 16, 2019. For all meeting details, including online registration, go to ao2019.osseo.org/.

Patrick Palacci, DDS, obtained his DDS degree in 1975 at Aix-Marseille University, in Marseille, France. He continued his postgraduate education in periodontology at Boston University from 1977 to 1981. In 1982,

he was appointed as a visiting professor at Boston University. Dr. Palacci is a private practitioner and the head of the Brånemark Osseointegration Center in Marseille. He is the author of numerous scientific articles and textbooks related to esthetic and implant dentistry and soft-tissue management. He now conducts a number of courses in his private clinic and is an invited speaker to scientific meetings around the world.**Giulia Mancardi, PhD,** obtained her

PhD in materials chemistry in June 2018 at University College London in the United Kingdom. She holds a master's degree in advanced chemical methods from the University of Torino in Italy and has six years of experience in biomaterials for bone regeneration. Dr. Mancardi is the author of four publications in international peer-reviewed journals and has presented her research at several congresses.

RELATED CONTENT

Restorative Dentistry

Highlights from the 35th annual American Academy of Cosmetic Dentistry scientific meeting in

May 1st, 2019

Clinical Tips

Fractured dental implant screw

complications: 3 methods for screw retrieval

Scott Froum, DDS Apr 4th, 2019

Surgical Techniques

A review of available periodontal surgical techniques for pocket elimination

Apr 4th, 2019

Clinical Tips

Dental pain: Predicting postoperative pain prior to the procedure

Scott Froum, DDS Mar 6th, 2019

Clinical Tips

Do root canals cause cancer?

Feb 8th, 2019

MORE IN SURGICAL TECHNIQUES

Surgical Techniques

To splint or not to splint adjacent implants: A 10-year retrospective analysis

Jan 10th, 2019

Periodontal Complications

Maxillary sinus grafting: Prevention and management of complications

Dec 13th, 2018

Clinical Tips

Saving teeth: Changing the hopeless prognosis with new technology

Scott Froum, DDS

Oct 9th, 2018

Clinical Tips

Saving T-I-M-E with short dental implants

Scott Froum, DDS

Jul 10th, 2018

Practice Management

Saving your sanity while saving teeth: 3 ways to make dental insurance approval easier for periodontal therapy

Jul 9th, 2018

Surgical Techniques

Saving teeth with periodontal-endodontic therapy

Jun 5th, 2018

Clinical Tips

Replacement dental implants: 3 clinical methods to increase survival rates after initial implant failure

Scott Froum, DDS

Jun 5th, 2018

Clinical Tips

Functional crown lengthening around bleeding crown and veneer restorations

Scott Froum, DDS

Mar 5th, 2018

Surgical Techniques

Surgical solutions to implant soft-tissue deficiencies in the esthetic zone

Feb 6th, 2018

Clinical Tips

The perils of do-it-yourself dentistry: A case study

Feb 6th, 2018

Load More Content

© 2019 Endeavor Business Media, LLC. All rights reserved.