

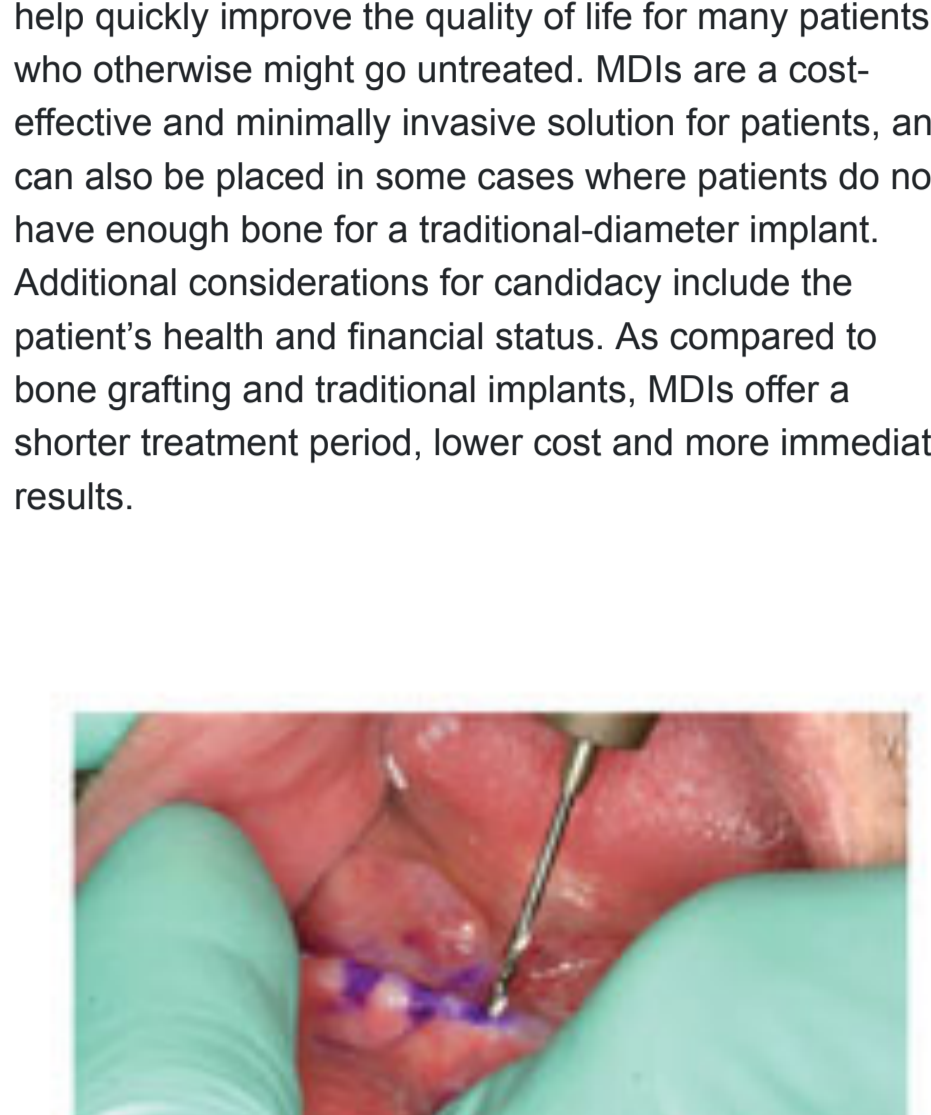
Simple Denture Stabilization with MDI Mini Dental Implants Dr. Benjamin D. Oppenheimer, DDS

Home > Dentaltown Magazine > August 2012 > Article

view comments (1)

More Options

Share 0 Tweet Share Save 0



More and more dentists are discovering that mini dental implants can be an effective and affordable way to help their edentulous patients. After eight years of experience placing mini dental implants (MDIs), I have repeatedly seen firsthand how this minimally invasive procedure can help quickly improve the quality of life for many patients, who otherwise might go untreated. MDIs are a cost-effective and minimally invasive solution for patients, and can also be placed in some cases where patients do not have enough bone for a traditional-diameter implant. Additional considerations for candidacy include the patient's health and financial status. As compared to bone grafting and traditional implants, MDIs offer a shorter treatment period, lower cost and more immediate results.

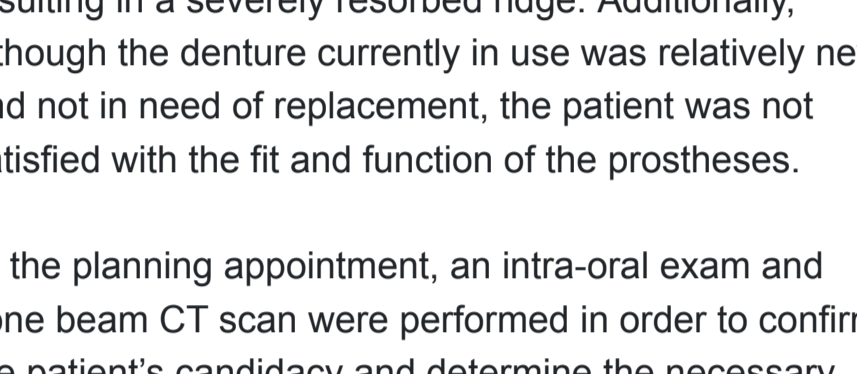


Fig 1: A pilot hole being drilled

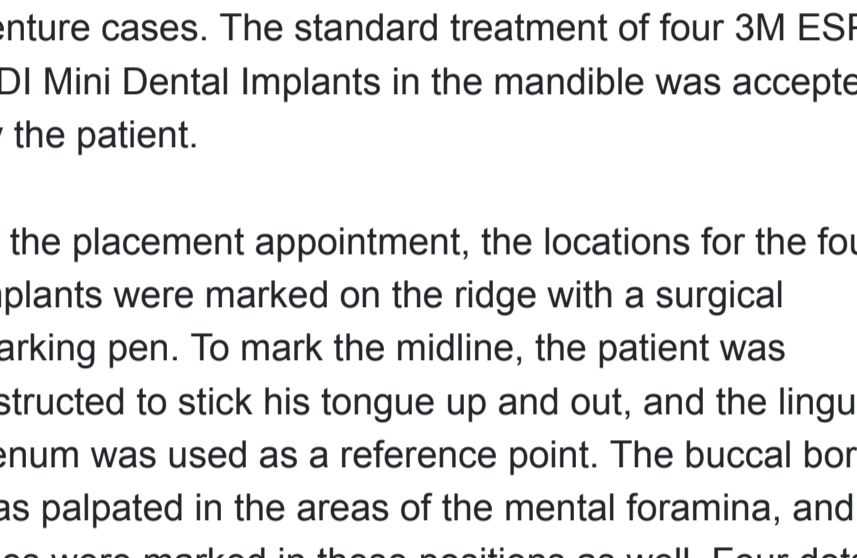


Fig 2: The four implants immediately following placement.

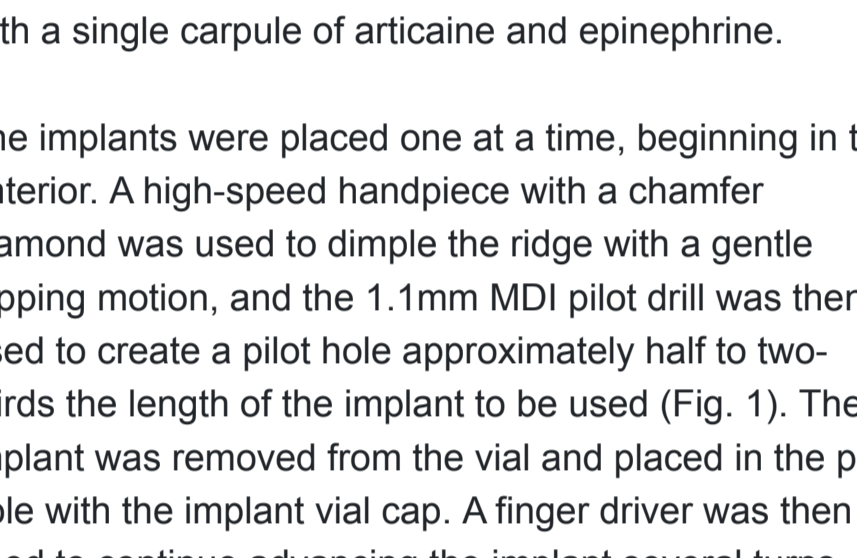


Fig 3: Pick-up material being applied to the metal housings.

Case Presentation

The patient in this case was an ideal candidate for denture stabilization with MDIs, as he had been wearing a mandibular denture for approximately 20 years, resulting in a severely resorbed ridge. Additionally, although the denture currently in use was relatively new and not in need of replacement, the patient was not satisfied with the fit and function of the prostheses.

At the planning appointment, an intra-oral exam and cone beam CT scan were performed in order to confirm the patient's candidacy and determine the necessary length and diameter of the implants to be used. If access to a CBCT is limited, an Orthopantomogram is typically sufficient to confidently plan most MDI mandibular denture cases. The standard treatment of four 3M ESPE MDI Mini Dental Implants in the mandible was accepted by the patient.

At the placement appointment, the locations for the four implants were marked on the ridge with a surgical marking pen. To mark the midline, the patient was instructed to stick his tongue up and out, and the lingual frenum was used as a reference point. The buccal border was palpated in the areas of the mental foramina, and lines were marked in these positions as well. Four dots were then marked in total, two on each side of the midline to indicate the implant sites and two dots 6mm anterior to the foramina. The area was then anesthetized with a single carpule of articaine and epinephrine.

The implants were placed one at a time, beginning in the anterior. A high-speed handpiece with a chamfer diamond was used to dimple the ridge with a gentle tapping motion, and the 1.1mm MDI pilot drill was then used to create a pilot hole approximately half to two-thirds the length of the implant to be used (Fig. 1). The implant was removed from the vial and placed in the pilot hole with the implant vial cap. A finger driver was then used to continue advancing the implant several turns. A winged thumb wrench and ratchet wrench were utilized for the final positioning to achieve 35Ncm of torque. After the first implant was placed, it was used as a paralleling point to establish the adjacent next implant angulation. This procedure was then repeated until all four implants were fully seated in their final position (Fig. 2).


As previously mentioned, in this case the patient's existing denture would be retrofitted with housings for use over the implants. Bite registration material was applied to the intaglio surface of the denture, and it was then placed in the mouth as the patient gently bit down with the upper denture in place. The lower denture was relieved in the areas of the implant heads. Blockout shims were cut and placed on the implants and metal housings were placed on each implant over the shims. Secure hard pick-up material was applied to the underside of the denture and onto the metal housings in the patient's mouth (Fig. 3). The denture was seated in the mouth and the patient was instructed to apply normal bite pressure for seven minutes. Following this, the denture was removed with the housings cured into place. The blockout shims were disposed of and the anterior border of the denture was trimmed to ensure patient comfort. Finally, an acrylic sealing agent was applied to the denture. The denture was seated back in the mouth and the patient was instructed to keep it in place for 48 hours.

Conclusion

This case is an ideal example of how MDIs can be placed quickly and immediately loaded, providing a nearly instantaneous increase in a patient's quality of life. With a thorough planning appointment, and by following the proper protocol, dentists can provide patients with an immediate denture stabilization solution that eliminates the strict bone requirements and lengthy recovery time sometimes associated with surgical dental implant procedures.

Author's Bio

Benjamin D. Oppenheimer, DDS, is a graduate of the State University of New York at Buffalo School of Dental Medicine where he was acknowledged for Academic Excellence and won the International Congress of Oral Implantologists Award. He is currently a fellow of the ICOI and general member of the AAID. Dr. Ben is a lead industry speaker for progressive companies such as 3M ESPE, Dynamic Dental Instruction and Global Dental Sciences. He has previously lectured for IMTEC Corporation and Evolution Dental – an industry leading small diameter implant restorative lab. His knowledge of implant hardware, equipment, bone grafting materials and techniques, CBCT, digital implant planning and minimally invasive implant dentistry have opened new opportunities for hundreds of dentists across the nation and continue to interest corporations worldwide. Dr. Oppenheimer has authored many scientific articles that have contributed to the knowledge base and confidence of dentists worldwide. He has also helped thousands of dental implant patients in his private practice near Buffalo, New York, where he focuses on implant dentistry.



Share 0 Tweet Share Save 0

view comments (1)

view article pdf

follow

Dentaltown Magazine

June 2019

Read Current Issue

Subscribe / Renew

Sponsors

CLASSIC PRACTICE RESOURCES

Let Sandy Pardue SUPERCHARGE your front office team!

Register Now!

Where you can learn about **Dental Office Design**

Keynote Speaker: **Dr. Gordon J. Christensen**

REGISTER TODAY! >

Townie® Poll

Do you rent or own your office space?

Own

Rent

Vote Results