PMC Alt No PDF

Journal of Indian Society of Periodontology

Wolters Kluwer -- Medknow Publications

Narrow diameter implant in posterior region

Jumshad B. Mohamed, Md. Nazish Alam, [...], and S. C. Chandrasekaran

Additional article information

Abstract

Dental implants placement can sometimes be limited due to physical conditions, wherein the horizontal space is limited by adjacent teeth and roots or situations in which there is narrow alveolar ridge, By using a narrow diameter implant (NDI), the need for bone augmentation can be avoided. In situations where there is limited horizontal space, a NDI may be the only option to replace a missing tooth.

Keywords: Immediate restoration without loading, narrow diameter implant, posterior edentulous

INTRODUCTION

The choice of implant diameter depends on the type of edentulism, the volume of the residual bone, the amount of space available for the prosthetic reconstruction, the emergence profile, and the type of occlusion.[1] Narrow diameter implants (NDIs; diameter <3.75 mm) have specific clinical indications, e.g., where there is reduced interradicular bone or a thin alveolar crest, and for the replacement of teeth with a small cervical diameter.[1]

Partially edentulous region in the posterior mandible is a very common finding. Replacement if delayed has a severe effect on the rehabilitation because of the situation following removal of posterior mandibular tooth, mesial drift of the teeth adjacent to edentulous area, which compromises the space for placement of a standard diameter implant.

NDIs supporting single tooth replacements have shown favorable clinical results in the long-term perspective.[1–9] Small diameter implants have been indicated in the incisor region for the maxilla and mandible primarily; their usage should be considered in select posterior regions. The use of NDI in these regions was always controversial due to the expectation that posterior teeth region are considered as load-bearing regions and due to high load the dental implant would fail. NDIs have been available in clinical practice since the 1990s, but only a few studies have analyzed their clinical outcome.[10–14] The identification of factors for the long-term survival rate; total implants still in place at the end of the follow-up and success rate; good clinical, radiologic, and aesthetic outcome is the main goal of the recent literature.[15] Immediate loading means placing the final or provisional prosthetic restoration immediately or within 48 hours of the surgical procedure. It is referred to appropriately as immediate loading when the prosthetic restoration is in occlusal contact; otherwise, it is known as immediate restoration without loading (IRWL).[16] This paper presents a case report of narrow diameter two-piece implant* placed in a compromised mandibular posterior edentulous site with IRWL.

CASE REPORT

A 23-year-old female patient reported to the Department of Periodontics and Oral Implantology with a chief complaint of missing tooth no. 46 [Figure 1] for about 5 to 6 years. On clinical evaluation, it was found that the edentulous space in relation to tooth no. 46 was compromised due to drifting of the adjacent teeth and was measured to be about 7 mm at the cervical level and at the contact area the space was reduced [Figure 2]. The buccolingual width preoperative was 7 mm and the inter-occlusal distance was measured to be 6 mm. The patient was suggested orthodontic correction of drifted adjacent teeth to achieve space for placement of standard implant. The patient was unwilling for orthodontic intervention because of prolonged treatment duration. After discussing the pros and cons of the NDIs in the posterior region, the patient gave the consent for the same. Following thorough clinical [Figure 1] and radiographic [Figure 2] evaluation, it was decided to place a narrow diameter two-piece implant* of size 3.0 × 13 mm.

Figure 1

Partially edentulous region in relation to 46

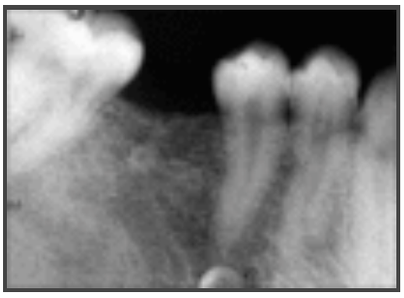

Figure 2

Intraoral periapical radiograph in relation to 46

Following standard preparation protocol for implant surgery, local infiltration anesthesia lignocaine (1:80 000) was administered. Using a scalpel no. 15, a crestal incision was given and the full thickness flap was raised using a periosteal elevator. Osteotomy was started using the pilot drill of diameter 2.0 mm to a depth of 13 mm and parallelism was checked using a paralleling pin. The osteotomy was subsequently enlarged to 2.5 mm. A narrow diameter two-piece dental implant* of size 3.0 × 13 mm was placed with good primary stability achieving a torque value of 45 Ncm [Figure 3]. Abutment was placed and trimmed to receive temporary restoration [Figure 4]. IRWL[16] protocol was followed with no occlusal contact in centric occlusion and eccentric movements [Figures 5 and 6]. A 0.2% chlorhexidine mouth rinse was prescribed two/three times daily for two weeks following surgery; antibiotics and anti-inflammatory drugs were prescribed for 5 days.

Figure 3

Implant torqued to 45 NCm

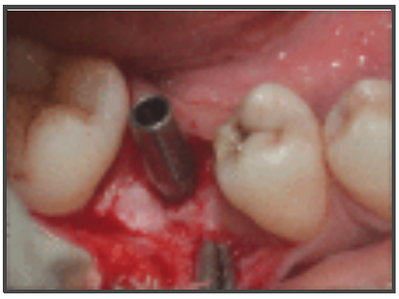

Figure 4

Abutment placed

Figure 5

Immediate restoration without loading

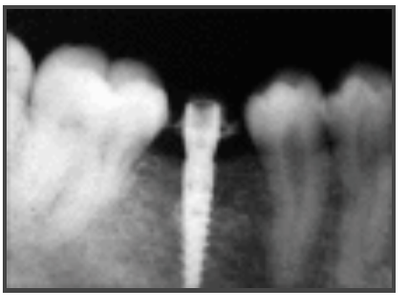

Figure 6

Radiograph after immediate loading

After uneventful healing of 3 months, the patient was evaluated clinically and radiologically. Soft tissue demonstrated satisfactory healing and intraoral periapical radiograph suggested no marginal bone loss after 3 months of healing process.

The temporary crown with abutment was removed and closed-tray transfer coping was placed and a radiograph was taken for analyzing the fit of the coping to the dental implant*. A 1-mm shoulder narrow diameter abutment was transferred to the laboratory for milling and fabrication of metal coping prior to final prosthesis. The abutment and coping was tried in to check for marginal fit. Final porcelain-fused metal crown was placed [Figure 7] with good emergence profile and radiograph revealed good marginal fit of the restoration [Figure 8].

Figure 7

Final prosthesis – Clinical photograph

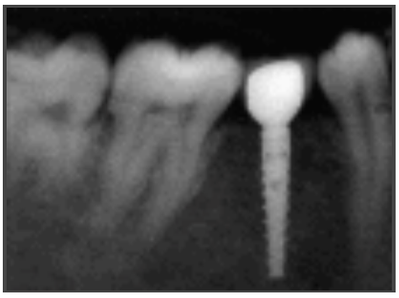

Figure 8

Final prosthesis – Radiograph

The patient was reviewed subsequently after 6 months clinically and radiographically [Figure 9] with no bone loss. At one year, clinical evaluation revealed good soft tissue health and excellent emergence profile [Figure 10]; radiographic examination showed no marginal bone loss [Figure 11].

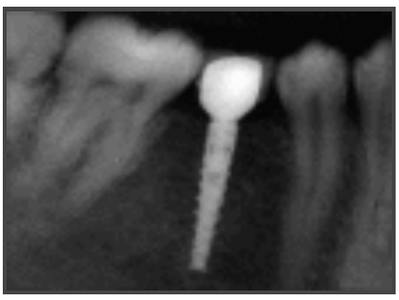

Figure 9

Six months review - Radiograph

Figure 10

One-year clinical photograph

Figure 11

One-year radiograph

DISCUSSION

Several studies evaluating the clinical outcome of narrow implants placed in different indications are available.[1–9] Narrow implants supporting single tooth replacements have shown favorable clinical results in the long-term perspective. NDIs have also been used to support full arch reconstructions, and satisfactory results have been shown for fixed bridges and over dentures in the mandible and in the maxilla. In general, no difference in the clinical outcome between standard diameter implants and narrow implants has been observed. In an extensive review, Renouard and Nisand[17] suggested that the survival rates for narrow implants are comparable with that of standard diameter implants when used in appropriate indications. They also reported that no relationship was found between marginal bone loss and implant diameter. Bone quality, a host-related factor, is believed to be the strongest predictor of outcome in immediate loading. Misch reported that most immediately loaded implants are placed in anatomical sites with bone quality of D1 or D2.[18] Zinsli *et al*. evaluated 2-part ITI implants (full-body screws 3.3 mm in diameter; Straumann) in a prospective clinical study. One hundred forty-nine partially or completely edentulous patients received a total of

298 implants over a 10-year period. After a standard healing period (3 to 6 months), the implants were restored with fixed restorations such as single crowns, fixed partial or complete prostheses, or over-dentures. Complete prostheses or over-dentures in the edentulous jaw were the predominant types of restoration. The cumulative 5-year implant survival rate was 98.7%; after 6 years, it was 96.6%. The authors concluded that the success of 3.3-mm ITI implants appears to be predictable if clinical guidelines are followed and appropriate prosthetic restorations are provided. However, the authors suggested that fatigue fracture may occur after a long period of function. [19] Although short-term outcomes of NDIs are quite promising, studies on long-term survival rate of these implants are few in number. Further

research is needed to elucidate the controversy surrounding the long-term survival of NDIs.

CONCLUSION

Nowadays, there is increased patient acceptance and popularity of implant supported prosthesis along with the demand for aesthetics. It is for the clinician to use his expertise and discretion to clearly distinguish the situation where implants can be placed and restored successfully to the ever increasing patient expectations. The case report presented in this paper revealed good soft tissue aesthetics and excellent emergence profile under the given circumstance of compromised space.

Footnotes

Source of Support: Nil

Conflict of Interest: None declared.

*TOUREG – NP™

Article information

J Indian Soc Periodontol. 2012 Oct-Dec; 16(4): 610–613.

doi: 10.4103/0972-124X.106932

PMCID: PMC3590737

PMID: 23492972

Jumshad B. Mohamed, Md. Nazish Alam, Arif Salman, and S. C. Chandrasekaran

Department of Periodontics and Implantology, Sree Balaji Dental College and Hospital, Chennai, Tamil Nadu, India

Address for correspondence: Dr. Md. Nazish Alam,

Sree Balaji Dental College, Narayanapuram, Chennai – 600 100, Tamil Nadu, India. E-mail: dr.naz.ish.alam@gmail.com

Received 2011 Aug 18; Accepted 2012 Aug 9.

Copyright : © Journal of Indian Society of Periodontology This is an open-access article distributed under the terms of the Creative Commons Attribution-Noncommercial-Share Alike 3.0 Unported, which permits unrestricted use, distribution, and reproduction in any medium, provided the original work is properly cited.

Articles from Journal of Indian Society of Periodontology are provided here courtesy of **Wolters Kluwer -- Medknow Publications**

REFERENCES

1. Degidi M, Piattelli A, Carinci F. Clinical Outcome of Narrow Diameter Implants: A Retrospective Study of 510 Implants. J Periodontol. 2008;79:49–54. [PubMed] [Google Scholar]

2. Andersen E, Saxegaard E, Knutsen BM, Haanaes HR. A prospective clinical study evaluating the safety and effectiveness of narrow-diameter threaded implants in the anterior region of the maxilla. Int J Oral Maxillofac Implants. 2001;16:217–24. [PubMed] [Google Scholar]

3. Cordaro L, Torsello F, Mirisola Di Torresanto V, Rossini C. Retrospective evaluation of mandibular incisor replacement with narrow neck implants. Clin Oral Implants Res. 2006;17:730–5. [PubMed] [Google Scholar]

4. Mericske-Stern R, Grutter L, Rosch R, Mericske

E. Clinical evaluation and prosthetic complications of single tooth replacements by non-submerged implants. Clin Oral Implants Res. 2001;12:309–18. [PubMed] [Google Scholar]

5. Polizzi G, Fabbro S, Furri M, Herrmann I, Squarzoni S. Clinical application of narrow Branemark System implants for single-tooth restorations. Int J Oral Maxillofac Implants. 1999;14:496–503. [PubMed] [Google Scholar]

6. Vigolo P, Givani A. Clinical evaluation of single-tooth mini-implant restorations: a five-year retrospective study. J Prosthet Dent. 2000;84:50–4. [PubMed] [Google Scholar]

7. Zarone F, Sorrentino R, Vaccaro F, Russo S. Prosthetic treatment of maxillary lateral incisor agenesis with osseointegrated implants: A 24-39-

month prospective clinical study. Clin Oral Implants Res. 2006;17:94–101. [PubMed] [Google Scholar]

8. Romeo E, Lops D, Amorfini L, Chiapasco M, Ghisolfi M, Vogel G. Clinical and radiographic evaluation of small-diameter (3.3-mm) implants followed for 1-7 years: A longitudinal study. Clin Oral Implants Res. 2006;17:139–48. [PubMed] [Google Scholar]

9. Vigolo P, Givani A, Majzoub Z, Cordioli G. Clinical evaluation of small-diameter implants in single-tooth and multiple-implant restorations: A 7-year retrospective study. Int J Oral Maxillofac Implants. 2004;19:703–9. [PubMed] [Google Scholar]

10. Vigolo P, Givani A. Clinical evaluation of

single-tooth mini-implant restorations: A five-year retrospective study. J Prosthet Dent. 2000;84:50–4. [PubMed] [Google Scholar]

11. Davarpanah M, Martinez H, Tecucianu JF, Celletti R, Lazzara R. Small-diameter implants: Indications and contraindications. J Esthet Dent. 2000;12:186–94. [PubMed] [Google Scholar]

12. Zinsli B, Sagesser T, Mericske E, Mericske-Stern R. Clinical evaluation of small-diameter ITI implants: Aprospective study. Int J Oral Maxillofac Implants. 2004;19:92–9. [PubMed] [Google Scholar]

13. Vigolo P, Givani A, Majzoub Z, Cordioli G. Clinical prospective study. Int J Oral Maxillofac Implants. 2004;19:92–9. [Google Scholar]

14. Comfort MB, Chu FC, Chai J, Wat PY, Chow TW. A 5-year prospective study on small diameter screwshaped oral implants. J Oral Rehabil. 2005;32:341–5. [PubMed] [Google Scholar]

15. Misch CE. Bone density: A key determinant for clinical success. In: Misch CE, editor. Contemporary Implant Dentistry. Chicago: Mosby; 1999. pp. 109–18. [Google Scholar]

16. Degidi M, Piattelli A, Carinci F. Clinical outcome of narrow diameter implants: A retrospective study of 510 implants. J Periodontol. 2008;79:49–54. [PubMed] [Google Scholar]

17. Renouard F, Nisand D. Impact of implant length and diameter on survival rates. Clin Oral Implants Res. 2006;17(Suppl 2):35–51. [PubMed] [Google Scholar]

18. Misch CE. Non-functional immediate teeth in partially edentulous patients: A pilot study of 10 consecutive cases using the Maestro Dental Implant System. Compendium. 1998;19:25–36. [Google Scholar]

19. Zinsli B, Sägesser T, Mericske E, Mericske-Stern R. Clinical evaluation of small-diameter ITI implants: A prospective study. Int J Oral Maxillofac Implants. 2004;19:92–9. [PubMed] [Google Scholar]