


Ask Dr. Christensen

 dentaleconomics.com/articles/print/volume-97/issue-1/departments/ask-dr-christensen/ask-dr-christensen.html

In this monthly feature, Dr. Gordon Christensen addresses the most frequently asked questions from Dental Economics® readers. If you would like to submit a question to Dr. Christensen, please send an e-mail to info@pccdental.com.

Q I am interested in small-diameter implants because I have been told that they can be loaded immediately after placement. Is that correct?

A Many patients have inadequate bone present for standard diameter implants and will not accept grafting procedures. A viable alternative, the small diameter implant, is continuing to receive wider use and acceptance.

Small-diameter implants (SDIs), “mini” implants, or narrow-body implants are usually described as being less than 3 mm in diameter. Most of them being used today are about 1.8 to 2.4 mm in diameter. These small-diameter implants have been used for many years as provisional support for prostheses, while standard 4 mm-diameter implants were integrating into the bone. Since the late 1990s, many dentists have been using them for long-term support of both fixed and removable prostheses. IMTEC Corporation received FDA approval for long-term use of its mini implant in 1999. Several companies are now promoting small-diameter implants for long-term use. If adequate bone is present, many of the mini implants can be placed without making a flap. However, in some situations, a flap procedure must be accomplished to allow vision of the bone morphology and adequate placement of the implant.

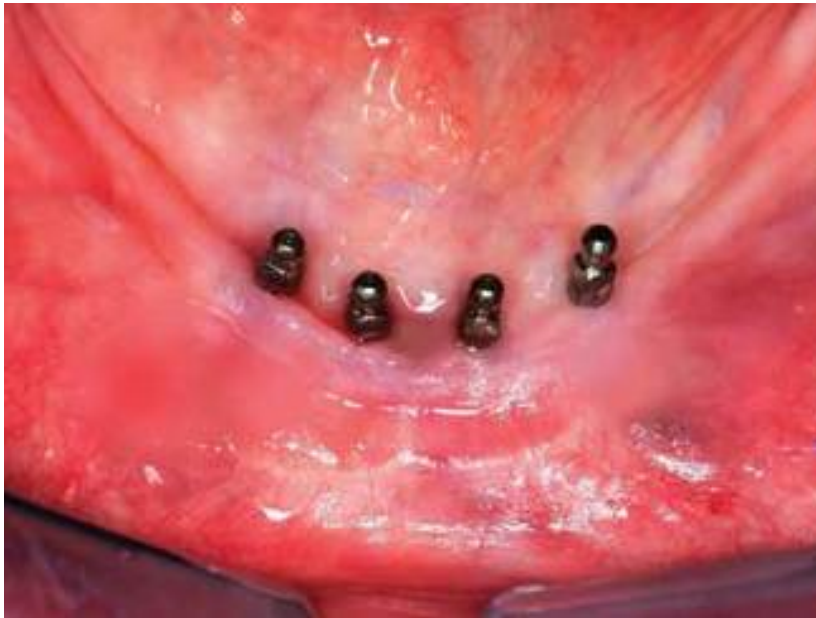

Figure 1 -- Four small-diameter implants (1.8 mm in diameter and 13 mm in length).

[Click here to enlarge image](#)

Yes, these small-diameter implants can be loaded as soon as they are placed. Unlike conventional-diameter, root-form implants that are nearly 4 mm in diameter and require a hole nearly the size of the implant for insertion, the current generation of small-diameter implants are much like a screw for a hardwood board. A small, narrow-diameter osteotomy is made in the bone about one-third to one-half the anticipated depth of the mini implant, and the small-diameter implant is screwed into the bone. The bone is expanded and widened by the implant as it cuts its way deeper than the original osteotomy site. The result is a very stable small implant immediately on placement.

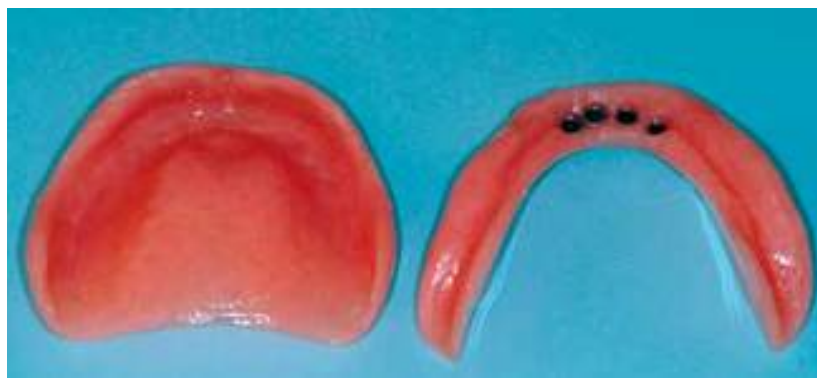

Figure 2 -- Patient's original dentures, released to contain housings for support and retention of lower denture.

[Click here to enlarge image](#)

Clinical success continues to be acknowledged with immediately loaded, small-diameter implants, and research is generally positive concerning this concept.

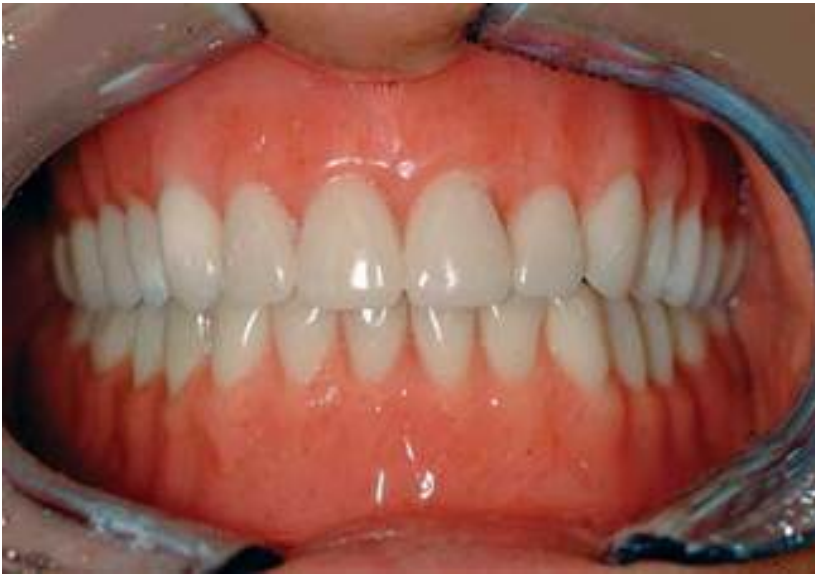

Figure 3 -- Dentures seated in the mouth, a few hours after implant replacement.
[Click here to enlarge image](#)

One of our newest videos, #V2317 "Mini Implants For Your Practice," shows placing and restoring small-diameter implants for removable and fixed prostheses. Implementation of this concept into your practice will expand prosthodontic services for your patients. For more information, contact Practical Clinical Courses at (800) 223-6569, or visit www.pccdental.com.

Q I have been told that implants should not be attached with fixed bridges to natural teeth. However, I have made several bridges, attaching natural teeth to implants, without any problems. Should implants be connected to natural teeth?

A The answer to your question is both "yes" and "no." There is very little research that has been accomplished on this important subject. I will provide my own conclusions for you, based on hundreds of implant-supported fixed prostheses I have accomplished personally.

There is no question that making a fixed prosthesis and cementing it with provisional cement to an implant and a natural tooth is asking for trouble. I learned this as I had some very expensive failures about 15 years ago. Provisional cement is weak and often breaks loose, allowing the natural tooth to intrude into the bone. I have observed natural teeth intrude up to one-half inch after breaking loose from the abutment crown. This intrusion requires only a few months and usually requires removal of the affected tooth and a new, more extensive restoration.

Another technique has also given me significant trouble. Early in the history of root-form implants, some clinicians suggested placing precision attachments or keyways between teeth and implants. This sounded like a logical concept. Again, I have had natural teeth intrude up to

one half inch when keyways were placed between implants and natural teeth. The only solution to such a problem is usually extraction of the natural tooth.

There are situations where natural teeth and implants need to be connected because of inadequate bone in potential pontic areas, or to avoid placing more implants for financial reasons.

The following technique is successful if carried out exactly as outlined below. For our example, I will assume that one natural tooth is being connected to one implant, with one missing tooth being replaced with a pontic:

- ***Make a full-crown tooth preparation on the abutment tooth. The preparation should be parallel and as long from the occlusal to the gingival area as possible.***
- ***Place an appropriate abutment on the implant. The abutment should be as parallel as possible with the abutment tooth.***
- ***Make the fixed prosthesis.***
- ***On the cementation appointment, make relatively deep rotary-diamond scratches on the tooth preparation.***
- ***Make sure that the abutment is securely attached to the implant.***
- ***Cement the fixed prosthesis with strong bonded-resin cement.***
- ***Adjust occlusion carefully, placing heavy occlusal forces on the articulation marking ribbon or paper, and reducing the marked areas to allow equal load on the implant and tooth-supported restoration and the adjacent natural teeth. The implant will not move apically, but the tooth can move slightly apically. Inadequate occlusal adjustment can cause premature failure.***
- ***Expect successful service from the natural tooth/implant-supported fixed prosthesis.***

Dr. Christensen is a practicing prosthodontist in Provo, Utah. He is the founder and director of Practical Clinical Courses, an international continuing-education organization for dental professionals initiated in 1981. Dr. Christensen is a co-founder (with his wife, Rella) and senior consultant of Clinical Research Associates which, since 1976, has conducted research in all areas of dentistry and publishes its findings to the dental profession in the well-known "CRA Newsletter." He is an adjunct professor at Brigham Young University and the University of Utah. Dr. Christensen has educational videos and hands-on courses on the above topics available through Practical Clinical Courses. Call (800) 223-6569 or (801) 226-6569.