



Replacement of a Molar With 2 Narrow Diameter Dental Implants

Ziv Mazor, DMD,* Adi Lorean, DMD,† Eitan Mijiritsky, DMD,‡ and Liran Levin, DMD§

The molars are one of the first teeth to be lost over lifetime; thus, their replacement is frequently needed. Implantation is generally the preferred choice to replace a missing single tooth avoiding vital teeth preparation and bridge fabrication. Placement of implant to replace a molar presents diagnostic, surgical, and prosthetic demands, such as an enlarged mesiodistal dimension and occlusal forces distribution.^{1,2} Poor bone quality in the posterior regions, especially the maxilla, could jeopardize the short- and long-term implant success.^{3,4} Anatomical considerations and adjacent vital structures (ie, maxillary sinus and mandibular canal), occlusal loads, and the occlusal table, which is frequently wider than the implant diameter, should also be of some concern.^{5,6} Quality and density of the bone in the posterior regions can compromise initial implant stabilization and load transfer to the bone.

The most frequent single molar to be replaced is the first mandibular molar, because this tooth is lost first.^{7,8} Implantation in the posterior area is a predictable procedure over time. The low rate of complications in addition to the high long-term success rate^{1,9–11} make im-

Objectives: The aim of the present study was to present results of single molar area rehabilitated by 2 narrow diameter dental implants.

Methods: A retrospective cohort of 33 consecutive patients from 2 private practices between the years 2008 and 2009 had been evaluated. Patients who had a first molar single replaced by 2 narrow diameter implants (3 mm wide) were included in this case series. Patients' demographics, site and implant characteristics, and time of follow-up were recorded from the medical files.

Results: Overall, 33 patients received 66 implants replacing 33 missing first molars. Patients' age ranged from 23 to 76 years with an average of 49.2 ± 12.7 years. Most of the implants were used to replace a mandib-

ular molar (76%) and 16 were used to replace 8 maxillary molars. In 2 patients, immediate implantation was performed. The mean distance between the adjacent teeth was 12.1 ± 1.0 mm. Follow-up time ranged from 10 to 18 months (average, 12.2 ± 1.9 months). All implants survived the follow-up time. One implant presented with 1 mm of bone loss at 12-month follow-up.

Conclusion: Replacing a single missing molar with 2 narrow diameter dental implants might serve as a viable treatment option providing good and predictable long-term results. (*Implant Dent* 2012;21:36–38)

Key Words: bone width, success, survival, alveolar bone, dental implantation, posterior teeth, maxilla, mandible

plant restoration a reliable solution to treat posterior partial edentulism.

The use of 2 implants to replace a single molar seems a logical treatment solution to avoid prosthetic complications.^{6,12} Yet, one significant disadvantage to the use of this concept is the limitation of the size of implants and their associated prosthetic components.

Misch¹³ recommended a modus operandi for replacing a single molar: 4-mm-diameter single implant in case of 7-mm M-D span, 5 mm diameter for 8- to 12-mm M-D span, and 2 implants of 4 mm diameter each in case of 14-mm M-D span, 2 implants of 4 and 5 mm diameter for 15-mm M-D span, and 2 implants of 5 mm diameter when the M-D span is 16 mm. Nevertheless, when using new available narrow diameter implants, 2 implants could be used

even when the distance between the adjacent teeth is smaller.

The aim of the present study was to present results of single molar area rehabilitated by 2 narrow diameter dental implants.

METHODS

A retrospective cohort of 33 consecutive patients from 2 private practices between the years 2008 and 2009 was evaluated. Patients who had a first molar single replaced by 2 narrow diameter implants (3 mm wide) (Adin Dental Implants, Alon Tavor, Israel) were included in this case series. Figure 1 depicts a case demonstrating the method used for implant placement. Patients' demographics, site and implant characteristics, and time of

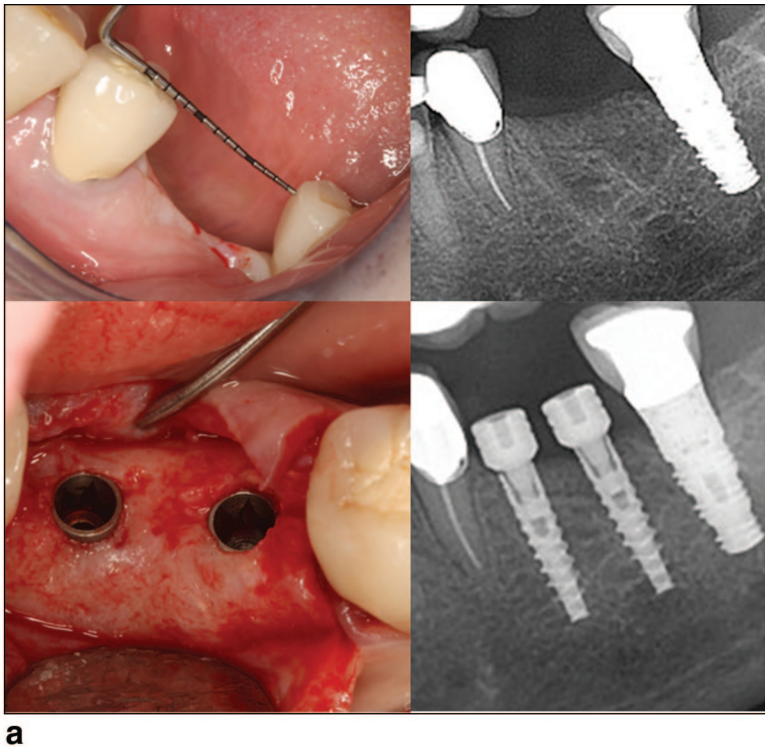
*Private Practice, Ra'anana, Israel.

†Private Practice, Tiberius, Israel.

‡Clinical Instructor, Department of Oral Rehabilitation, School of Dentistry, Tel-Aviv University, Tel-Aviv, Israel.

§Senior Lecturer, Department of Periodontology, School of Graduate Dentistry, Rambam Health Care Campus, Haifa, Israel; Faculty of Medicine, Technion, IIT, Haifa, Israel.

Reprint requests and correspondence to: Liran Levin, DMD, Senior Lecturer, Department of Periodontology, School of Graduate Dentistry, Rambam Health Care Campus, Haifa, Israel. Fax: +972-4-85431717, E-mail: liranl@technion.ac.il



used to replace 8 maxillary molars. In 2 patients, immediate implantation was performed. The mean distance between the adjacent teeth was 12.1 ± 1.0 mm. All implants were 3 mm wide with tapered Mors internal connection, and the average length was 12.6 ± 1.2 mm for the mesial implant and 12.1 ± 1.3 mm for the distal one. Follow-up time ranged from 10 to 18 months (average, 12.2 ± 1.9 months). All implants survived the follow-up time. One implant presented with 1 mm of bone loss at 12-month follow-up.

DISCUSSION

The use of dental implants for single posterior tooth replacement has become a predictable treatment modality.¹¹ Studies on bite-force measurement indicate that there is considerably greater force generated in the posterior compared with the anterior part of the same jaw.¹⁴ Occlusal forces can be 3 to 4 times as great in the molar region compared with the incisor region.¹⁵ The quantity of available bone for implant placement in the posterior is limited by the lingual concavity and the inferior alveolar nerve in the mandible, and by the sinuses in the maxilla. There is also generally an inferior quality of bone in the posterior region compared with the anterior region of the same arch.¹⁵ These conditions create a need for carefully selected treatment plans for posterior single-tooth replacement using osseointegrated dental implants.

Single regular-diameter implants might be incapable of predictably withstanding molar masticatory function and occlusal loading forces. Wide-diameter implants are a suitable alternative for replacing a missing molar in some cases; however, the use of 2 implants has been successfully demonstrated to be a functional and more biomechanically sound method of molar replacement.¹⁵ Wide-diameter implants are not always a treatment option for replacing a single molar, especially when the buccolingual dimension is deficient. The use of 2 implants might also provide better prosthetic stability and prevent rotational forces on the prosthetic components. Restoration of missing molars

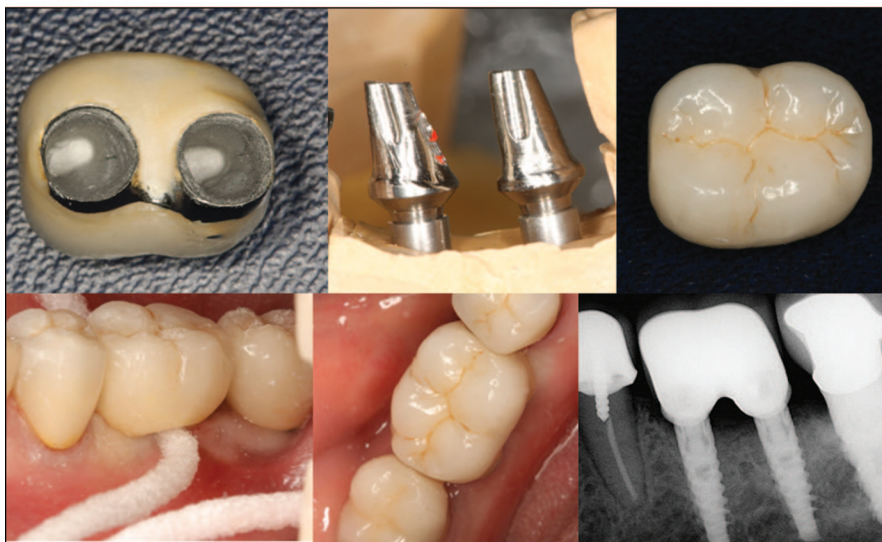

Fig. 1. Replacement of a molar with 2 narrow dental implants. **a**, A missing first left molar with a mesiodistal distance of 11 mm (upper view) was replaced with 2 narrow diameter dental implants (lower view). **b**, The final rehabilitation consisted of a crown with an artificial intraradicular space (upper view—laboratory work). Note the final restoration in place where broad floss is inserted for cleaning the area in an intraradicular manner (lower view left). Final radiographic view is presented in the lower right view.

follow-up were recorded from the medical files. Data were analyzed using descriptive statistics.

RESULTS

Overall, 33 patients (14 men and 19 women) received 66 implants re-

placing 33 missing first molars. Patients' age ranged from 23 to 76 years with an average of 49.2 ± 12.7 years. Two of the patients reported on smoking at the time of implantation. Most of the implants were used to replace a mandibular molar (76%) and 16 were

with 1 wide-diameter implant has a greater incidence of screw loosening¹⁶ and, compared with 2 implants, has a greater incidence of prosthesis mobility⁶ and a higher failure rate.¹⁷ When narrow implants are used as single-tooth replacement, especially in the molar region, an increased risk of screw loosening or fracture exists due to the combination of high masticatory forces, buccal-lingual mandibular movement, and cusp-groove orientation.¹⁸ Therefore, the use of 2 implants to replace a single molar is a logical treatment solution to avoid prosthodontic complications.¹²

One significant barrier to the widespread use of this concept is the limitation of the size of implants and their associated prosthetic components. Nevertheless, when using narrow implants, 2 implants could be used even when the distance between the adjacent teeth is rather limited.

This case series provided an evidence for the usefulness of 2 narrow diameter implants to replace a single molar. There is, however, a need for further long-term comparison studies to confirm and reaffirm the result presented here.

CONCLUSION

Replacing a single missing molar with 2 narrow dental implants might serve as a viable treatment option providing good and predictable long-term results.

Disclosure

The authors claim to have no financial interest in any company or any of the products mentioned in this article.

REFERENCES

1. Schwartz-Arad D, Samet N, Samet N. Single tooth replacement of missing molars: A retrospective study of 78 implants. *J Periodontol*. 1999;70:449-454.
2. Becker W, Becker BE, Alsuwyed A, et al. Long-term evaluation of 282 implants in maxillary and mandibular molar positions: A prospective study. *J Periodontol*. 1999;70:896-901.
3. Bass SL, Triplett RG. The effects of preoperative resorption and jaw anatomy on implant success. A report of 303 cases. *Clin Oral Implants Res*. 1991;2:193-198.
4. Bryant SR. The effects of age, jaw site, and bone condition on oral implant outcomes. *Int J Prosthodont*. 1998;11:470-490.
5. Misch CE. Available Bone and Dental Implant Treatment Plans. In: Misch CE, ed. *Contemporary Implant Dentistry*. 3rd ed. St. Louis, MO: CV Mosby; 2008:130-229.
6. Balshi TJ, Hernandez RE, Pryszyk MC, et al. A comparative study of one implant versus two replacing a single molar. *Int J Oral Maxillofac Implants*. 1996;11:372-378.
7. McCaul LK, Jenkins WM, Kay EJ. The reasons for the extraction of various tooth types in Scotland: A 15-year follow up. *J Dent*. 2001;29:401-407.
8. Vignarajah S. Various reasons for permanent tooth extractions in a Caribbean population—Antigua. *Int Dent J*. 1993;43:207-212.
9. Muftu A, Chapman RJ. Replacing posterior teeth with freestanding implants: Four-year prosthodontic results of a pro-

spective study. *J Am Dent Assoc*. 1998;129:1097-1102.

10. Levin L, Sadet P, Grossmann Y. A retrospective evaluation of 1387 single-tooth implants: A six-year follow up. *J Periodontol*. 2006;77:2080-2083.

11. Levin L, Laviv A, Schwartz-Arad D. Long-term success of implants replacing a single molar. *J Periodontol*. 2006;77:1528-1532.

12. Petropoulos VC, Wolfinger GJ, Balshi TJ. Complications of mandibular molar replacement with a single implant: A case report. *J Can Dent Assoc*. 2004;70:238-242.

13. Misch CE. Single Tooth Replacement: Treatment Options. In: Misch CE, ed. *Contemporary Implant Dentistry*. 3rd ed. St. Louis, MO: CV Mosby; 2008:327-366.

14. Haraldson T, Carlsson GE, Ingerwall B. Functional state, bite force and postural muscle activity in patients with osseointegrated oral implant bridges. *Acta Odontol Scand*. 1979;37:195-206.

15. Balshi TJ, Wolfinger GJ. Two-implant-supported single molar replacement: Interdental space requirements and comparison to alternative options. *Int J Periodontics Restorative Dent*. 1997;17:426-435.

16. Bakaeen LG, Winkler S, Neff PA. The effect of implant diameter, restoration design, and occlusal table variations on screw loosening of posterior single-tooth implant restorations. *J Oral Implantol*. 2001;27:63-72.

17. Bahat O, Handelsman M. Use of wide implants and double implants in the posterior jaw: A clinical report. *Int J Oral Maxillofac Implants*. 1996;11:379-386.

18. Conrad HJ, Schulte JK, Vallee MC. Fractures related to occlusal overload with single posterior implants: A clinical report. *J Prosthet Dent*. 2008;99:251-256.