

# Fixed Partial Denture Treatment With Mini Dental Implants

Brian J. Jackson, DDS

## INTRODUCTION

Clinicians evaluate edentulous and partially edentulous patients with atrophic ridges everyday in their practices. They are faced with the dilemma of how to provide treatment plans with long-term predictable solutions that meet patient expectations. Very small diameter implants or mini dental implants (MDI) are a treatment alternative due to their reduced size. MDI does not require bone augmentation procedures, which are technique sensitive, time consuming, and vary in predictable results.<sup>1,2</sup> The option of utilizing MDI provides a minimally invasive, safe, and cost-effective approach for restoring the patient with deficient bone volume.<sup>3,4</sup>

MDI usage has been FDA approved for long-term use in removable overdentures, partial dentures, as well as fixed multi-unit bridges.<sup>5</sup> Their inception into the field of oral implantology was as transitional devices to retain a removable or fixed prosthesis while conventional implants (greater than 3.5mm in diameter) osseointegrated.<sup>6-8</sup> Several studies have supported utilization of very small diameter implants as temporary implants to retain fixed multi-unit bridges. The idea that very small diameter implants could osseointegrate and be used long term was conceived when retrieval was difficult or impossible without separation of the implant. Subsequent research supported that the biological phenomenon of osseointegration occurred on the surface of very small diameter implants.<sup>9,10</sup> Recent research has demonstrated that mini dental implants can be utilized successfully to retain fixed multi-unit partial dentures.<sup>11,12</sup>

The use of MDI is categorized as a single-stage implant in that they are placed in a nonsubmerged

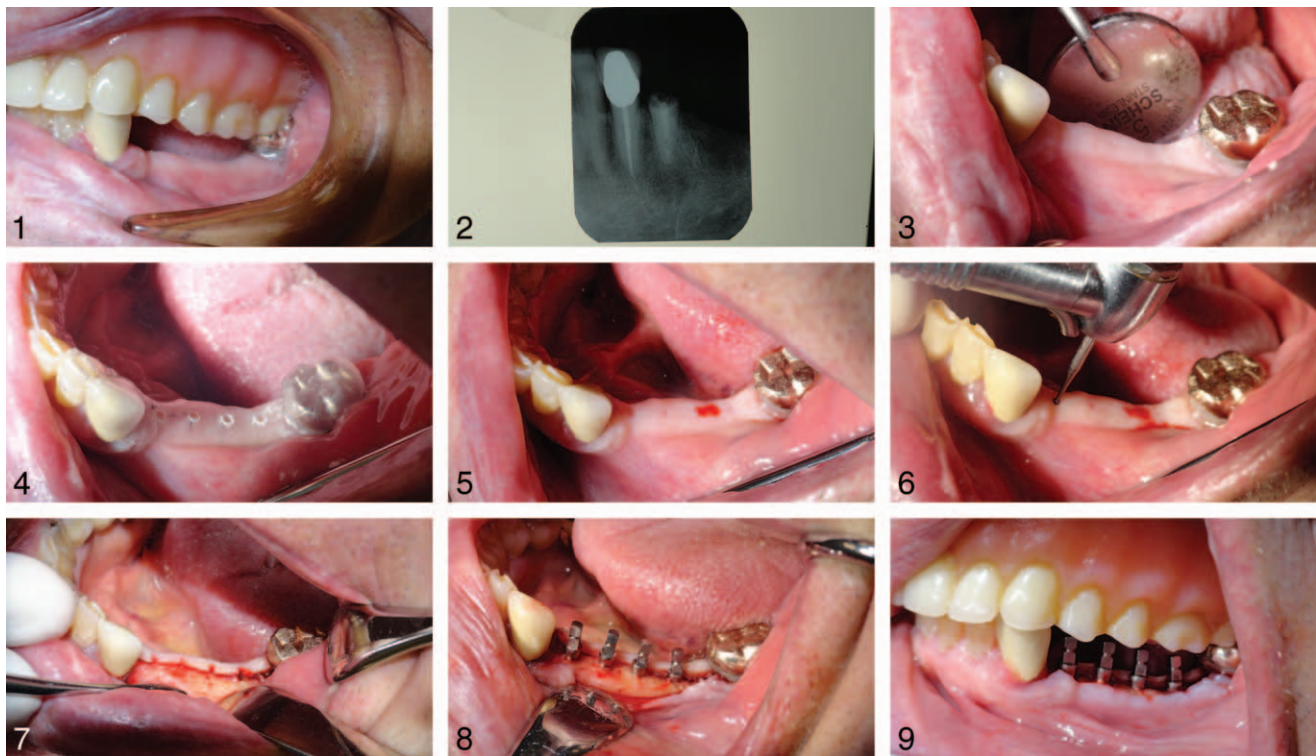
manner. The 1-piece design consists of 3 parts: a bone anchoring, gingival transversing, and prosthetic abutment.<sup>13</sup> Although controversial, the lack of a microgap may reduce the amount of crestal bone resorption as seen in conventional 2-piece submergible implants.<sup>14</sup> The gingival transferring component within the implant design should penetrate through a zone of keratinized gingiva. The presence of keratinized gingiva surrounding the MDI serves as a barrier to pathogenic bacteria. The prosthetic aspect of the implant has a predefined shoulder, eliminating the need to prepare the abutment prior to the restorative stage. The final prosthesis is ideal in maintaining good hygiene due to the prescribed shoulder margin, which can be located supragingivally or at the gingival level.<sup>15</sup> Due to the reduced size of the implant, the MDI is manufactured from titanium alloy. Furthermore, the single-stage procedure demonstrates more patient comfort with shorter healing times.<sup>16</sup>

## CASE REPORT

An 83-year-old male was referred to our practice to evaluate the mandibular left posterior area. The patient presented with a history of prostate cancer and hypertension that was well controlled and monitored regularly. The patient was taking Lanoxin and Coumadin. The patient's overall medical history was insignificant for dental implant treatment.

The patient was partially edentulous, missing the mandibular left 1st molar and 2nd premolar (#19 and 20). The partially edentulous area was previously restored with a 4-unit fixed partial denture with #18 (mandibular left 2nd molar) and #21 (mandibular left 1st premolar) serving as natural tooth abutments. The clinical exam and periapical radiograph revealed extensive root caries associated with a retained root #21 (mandibular 1st premolar) (Figures 1 and 2). A diagnosis of dental caries with a hopeless prognosis was established. The patient

Slavin, Jackson & Burns, Utica, NY.  
Corresponding author, e-mail: bjddsimplant@aol.com  
DOI: 10.1563/aaid-joi-D-14-00037



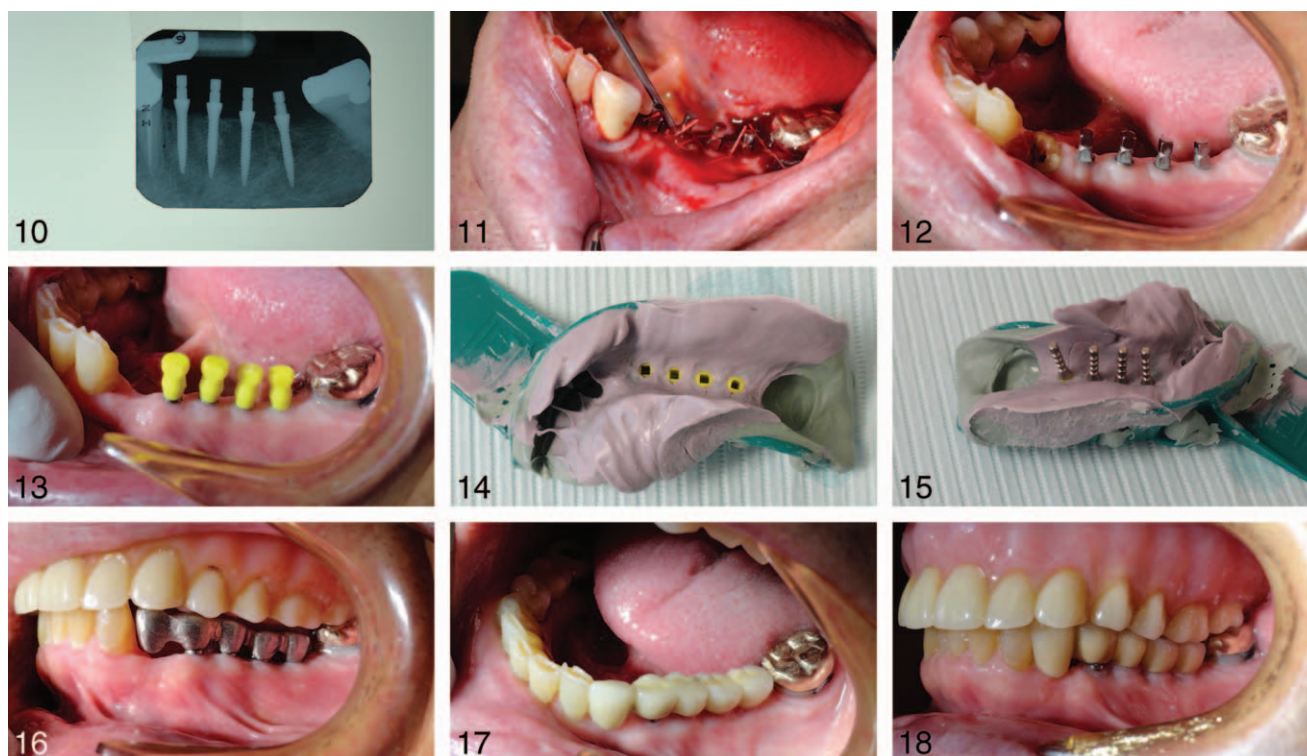
**FIGURES 1–9.** **FIGURE 1.** Initial intraoral-centric relation. **FIGURE 2.** Initial periapical radiographs. **FIGURE 3.** Initial intraoral-presurgical facial view. **FIGURE 4.** Surgical template. **FIGURE 5.** Bleeding points indicating future implant sites. **FIGURE 6.** Transgingival penetration with a #2 round surgical bur. **FIGURE 7.** Mucoperiosteal flap. **FIGURE 8.** (4) 2.1mm × 10mm collared square-head mini dental implants (MDI)-facial view. **FIGURE 9.** (4) 2.1mm × 10mm collared square-head MDI-centric relation.

reported nonspecific symptoms with #22 (mandibular left canine) but no definitive diagnosis was made. The presurgical site demonstrated a facial-lingual osseous width of 5 mm osseous ridge in areas #19 and 20, and a 3 mm zone of keratinized gingiva (Figure 3). Panoramic and periapical radiographs exhibited 13 mm of bone height, measured from the alveolar crest to the superior border of the radiographic mandibular canal.

The author presented various treatment options: conventional implants with guided bone regeneration, mini dental implants without bone grafting, or a mandibular partial denture. The treatment plan accepted was a 3-unit fixed bridge supported by 4 MDI. The implant placement would consist of 1 implant each for the premolars and 2 implants for the 1st mandibular molar. The staged procedure would be initiated with the extraction of tooth #21 and simultaneous bone grafting, followed by implant placement 6 months thereafter. Immediate placement of an implant at the time of extraction was not performed because of the location of the

mandibular nerve, and because rigid fixation might not be achieved.

The surgical phase was initiated with a 20 mL blood draw from the left median cubicle vein via standard phlebotomy technique. The blood was placed in a single spin centrifuge for 10 minutes for the separation of whole blood into platelet rich plasma (PRP).<sup>17,18</sup> The patient rinsed with 0.12% chlorhexidine solution for 30 seconds. The surgical site was anesthetized with 3 carpules of 2% lidocaine with 1:100 000 epinephrine in a buccal and lingual infiltration technique. A tooth-supported surgical guide was placed and 4 bleeding points were established by penetrating the soft tissue with an endodontic explorer (Figures 4 and 5). A #2 round bur penetrated transgingivally to create an osteotomy dimple in the crest of the ridge (Figure 6). A full mucoperiosteal flap was made with a 15C blade extending from the mandibular left 2nd molar (#18) to the mandibular left canine (#22) and reflected with a periosteal elevator (Figure 7). A 1.1-mm drill was used to create 4 partial osteotomies at a depth of 5 mm. The (4) 2.1 × 10 mm



**FIGURES 10–18.** **FIGURE 10.** Periapical radiograph-final implant placement. **FIGURE 11.** Implant surgical site bathed in platelet rich plasma (PRP). **FIGURE 12.** Mandibular left canine (#22) pre-extraction surgery. **FIGURE 13.** Mini dental implant (MDI) impression transfers. **FIGURE 14.** MDI impression transfers captured in polyvinyl siloxane material. **FIGURE 15.** Implant analogs/transfers secured in impression material. **FIGURE 16.** 5-unit metal framework try in. **FIGURE 17.** 5-unit porcelain fused to metal-facial occlusal view. **FIGURE 18.** 5-unit porcelain fused to metal prosthesis-centric relation.

square-head collared MDI (3M ESPE, St. Paul, Minn) were auto-advanced with a finger driver, thumb wrench, and ratchet to the crest of the ridge (Figures 8 and 9). Periapical radiographs were taken throughout the procedure to evaluate proximity of the implants to adjacent teeth and the inferior alveolar nerve (Figure 10). The surgical site was bathed in PRP and closed using 4.0 vicryl sutures in an interrupted manner (Figure 11). Postoperative instructions were given to the patient, ice was applied to the face, and he was discharged.

The patient presented 1 month postimplant surgery with acute, localized pain associated with the left mandibular canine (#22). A diagnosis of acute alveolar abscess was established, and the patient elected tooth extraction (Figure 12). A simple extraction was performed under block anesthesia consisting of 2 carpules of lidocaine with 1:100 000 epinephrine. A 301 and 345 elevator, followed by a 151 forceps, were used to remove the tooth. The socket was debrided with a double-ended curette and allowed to heal naturally. A

prosthetic revision of the original treatment plan was made to incorporate a mesial cantilever to the 4-unit implant supported bridge.

The restorative stage was initiated 3 months postimplant surgical placement. The restorative impression procedure was accomplished via an indirect approach. Abutment level impression transfer caps were placed over the 4 MDI (Figure 13). A polyvinyl siloxane impression material (Imprint III, 3M) was placed in a stock tray to capture the position and angulation of the 1-piece implants (Figure 14). Implant square-head, collared analogues were placed into the transfer caps secured within the impression material (Figure 15). A maxillomandibular relationship, opposing model, and shade was taken.

A certified dental technician created a final working model by pouring the intraoral impression and mounting the case on a semi-adjustable articulator. A 5-unit framework consisting of a #22 mesial pontic cantilever was cast in a semi-precious material. The framework was tried in, evaluated for

marginal integrity and interocclusal space (Figure 16). Porcelain application was performed by the dental ceramist and returned for final placement. The 5-unit fixed partial denture was placed and the occlusion refined according to implant occlusal principles. Centric occlusal contacts were aligned over the long axis of the implants, and a reduced buccal-lingual occlusal table was developed. The prosthesis was splinted with the mesial pontic exhibiting zero contact in all eccentric movements. The restoration was permanently cemented with zinc phosphate cement (Figures 17 and 18).

### DISCUSSION

The concept of minimally invasive surgical procedures has escalated in the past several years. The option of mini dental implant therapy as an implant reconstruction modality aligns with this emerging idea.<sup>19</sup> The flapless, non-bone grafting approach to implant surgery provides the patient with a safe, effective means for prosthetic reconstruction. The success of treatment depends on a thought-provoking treatment plan focused on the surgical management of limited bone volume and biomechanics.

The biological concept of osseointegration has been established for very small diameter implants. Long-term survival depends on initial rigid fixation via thread design as well as the strength of the implant.<sup>20</sup> The macrostructure thread design and roughened surface via sand-blasting and acid etching facilitate bone attachment. Studies have exhibited that roughened implant surfaces demonstrate a higher percentage of bone-to-implant contact over machined surfaces.<sup>21</sup> Small diameter implants are manufactured from titanium alloy (Ti6Al4V) for maximum strength and excellent biocompatibility. The elements of aluminum and vanadium increase tensile strength and elastic modulus and allow hardening. The utilization of titanium alloy versus medical grade pure titanium in MDI design reduces implant fracture.<sup>22-25</sup>

The surgical phase of treatment has specific objectives in order to establish a successful outcome. The primary objective is to obtain rigid fixation of the implant fixture at initial placement. The surgical protocol describes an auto advancement of the implant into an undersized, partial depth osteotomy. If mobility of the implant fixture

is confirmed at this stage, then it should be removed, replaced with a wider diameter implant, or inserted in an alternative site. It is critical that the threads are placed completely in bone, regardless of the height of the gingival tissues. The gingival topography can be managed after osseointegration has been achieved by performing a gingivoplasty to correct excess tissue coronal to the abutment aspect of the implant. The gingivoplasty procedure can be performed with a 15C surgical blade or flame diamond in a high-speed handpiece with copious irrigation. This procedure should be performed at final overdenture placement to allow for epithelialization to develop in the presence of the o-ring housings.

A surgical guide is recommended for proper placement, spacing of the implants, and establishing a parallel path of insertion for the final splinted prosthesis. The small size of the abutment square head limits the ability for intraoral preparation. A surgical guide fabricated from a reformatted cone beam computerized tomography (CBCT) can aid the clinician in the ideal placing of parallel implants. In addition, the guide can facilitate a flapless approach for implant placement. If traditional plane films are used, such as periapicals or a panorex, then a mucoperiosteal flap is recommended to visualize the width of the crestal ridge. In this case letter, the surgical aspect was performed utilizing a mucoperiosteal flap for direct visualization of the osseous crest. In atrophic ridges, a flap approach and a reformatted CBCT can enhance implant position within the parameter of available bone. A traditional osseointegrated period of 3 months is ideal for long-term survival of implant supported restorations in the mandible.

The restorative stage of treatment mimics conventional implant occlusal techniques and principles. The angulation and position of the implants are transferred to a stone model via transfer caps and implant analogues. Research has exhibited that occlusal force in the posterior region can approach 1000 Nt vs 50 to 200 Nt in the anterior jaw.<sup>26</sup> Therefore, multi-unit fixed prostheses are splinted together in a common framework to reduce stress to the crest by increasing area under a given force.<sup>27</sup> In this case, the opposing maxillary denture demonstrates less force on the fixed implant prosthesis in comparison to natural teeth or a fixed prosthesis. In addition, the maxillary

denture can be removed at bedtime for nocturnal bruxers, thereby reducing stress at the crest of the bone.

Implants that are placed in parallel facilitate an ease of prosthesis fabrication. If divergent implants exist, it is best to utilize the indirect impression technique and allow the laboratory technician to survey the implants. The technician can modify and mark the abutments/analogues to create a path of insertion. The clinician can reproduce the modifications intra-orally to seat the prosthetic framework. This approach has demonstrated better results than preparing the square head abutment and using a direct fixed prosthetic impression approach. The fabrication of a laboratory die is difficult to achieve due to the small size of the abutment postpreparing. If traditional impressions are employed, then a polyurethane die material is best to prevent fracture.

Implant occlusal principles play a major role for long-term success when use of MDI is employed. Centric occlusal contacts should exhibit a point contact and be aligned over the long axis of the implant.<sup>28</sup> The buccal-lingual dimension of the prosthesis is reduced to minimize eccentric lateral interferences. In addition, the reduced size of the prosthesis requires less applied force to pierce a bulbous of food during mastication. Treatment planning should focus on increasing numbers of implants with MDI to reduce stress and metal fatigue.<sup>29</sup> In this case, a mesial cantilever was incorporated as part of the final prosthesis. The mesial pontic exhibited zero contact in centric occlusion and all eccentric movements. The final splinted prosthesis was cemented with zinc phosphate. This type of cement provides adequate tensile strength and the ability to remove excess without causing abutment scratching.

### CONCLUSION

Patients present with missing teeth with resultant bone loss. Dentists see this clinical situation worsen over time, with clinical management becoming more challenging, requiring extensive procedures prior to implant surgery. The utilization of very small diameter implants for highly selected patients can provide a minimally invasive, safe, and predictable

alternative to conventional bone grafting procedures.

Although the usage of very small diameter or mini dental implants (MDI) continues to evolve and expand, there exists a need for an increase in the body of research.

### ABBREVIATIONS

CBCT: cone beam computerized tomography

MDI: mini-dental implant

PRP: platelet-rich plasma

### ACKNOWLEDGMENTS

The author wishes to acknowledge Caitlin Carparelli, DA, Tatyana Lyubezhanina, DA, and Melanie Fink, CDA for their assistance in the preparation of this paper, and Curt Gardali CDT (Gardali Dental Laboratory, Utica, NY) for his dental technical expertise.

### REFERENCES

1. Esposito M, Grusovin MG, Coulthard P, et al. The efficiency of various bone augmentation procedures for dental implants: A Cochrane systematic review of randomized controlled clinical trials. *Int J Oral Maxillofac Implants*. 2006;21:696–710.
2. Davarpanah M, Martinez H, Tecucianu JF, Celletti R, Lazzara R. Small-diameter implants: indications and contraindications. *J Esthet Dent*. 2000;12:186–194.
3. Shatkin TE, Shatkin S, Oppenheimer BD, et al. Mini dental implants for long-term fixed and removable prosthetics: a retrospective analysis of 2514 implants placed over a five-year period. *Compend Contin Educ Dent*. 2007;28:92–99.
4. Flanagan D. Fixed partial dentures and crowns supported by very small diameter-dental implants in compromised sites. *Implant Dent*. 2008;17:182–188.
5. Christensen GJ. The “mini” implant has arrived. *J Am Dent Assoc*. 2006;137:387–390.
6. Froum S, Emtiaz S, Bloom MJ, et al. The use of transitional implants for immediate fixed temporary prostheses in cases of implant restorations. *Pract Periodontics Aesthet Dent*. 1998;10:737–746.
7. Brown M, Tarnow D. Fixed provisionalization with transitional implants for partially edentulous patients: a case study. *Pract Periodontics Aesthet Dent*. 2001;13:123–127.
8. Petrungaro PS, Winmiller N. Using transitional implants during the healing phase of implant reconstruction. *Gen Dent*. 2001;49:46–51.
9. Balkin BE, Steflik DE, Naval F. Mini-dental implant insertion with the auto-advance technique for ongoing applications. *J Oral Implantol*. 2001;27:32–27.
10. Sendax V. Mini Dental Implants: Principles and Practices. St Louis, Mo: Mosby; 2013.
11. Flanagan D. Implant-supported fixed prosthetic treatment using very small-diameter implants: a case report. *J Oral Implantol*. 2006;32:34–37.

12. Mazor Z, Steigmann M, Leshem R, et al. Mini-implants to reconstruct missing teeth in severe ridge deficiency and small interdental space: a 5-year case series. *Implant Dent.* 2004;13:336–341.
13. Siepenkothen T. Clinical performance and radiographic evaluation of a novel one-piece implant in a private practice over a mean of seventeen months. *J Prosthet Dent.* 2007;97:569–578.
14. Herman JS, Cochran DL, Nummikoski PV, Buser D. Crestal bone changes around titanium implants. A radiographic evaluation of unloaded non-submerged and submerged implants in the canine mandible. *J Periodontol.* 1997;68:1117–1130.
15. Buser D, Mericske-Stern R, Dula K, Lank NP. Clinical experience with one-stage, non-submerged dental implants. *Adv Dent Res.* 1999;13:153–161.
16. Barrachina-Diez J, Jashkandi E, Stamp F, Etal S. Part 1: implant characteristics and loading protocols. A systematic literature review with meta-analysis. *Int J Oral Maxillofac Implants.* 2013;28:503–518.
17. Anitua F. Plasma rich in growth factors: preliminary results of use in preparation of future sites for implants. *Int J Oral Maxillofac Implants.* 1999;14:529–535.
18. Marx RE. Platelet-rich plasma: evidence to support its use. *J Oral Maxillofac Surg.* 2004;62:489–496.
19. Gibney JW. Minimally invasive implant surgery. *J Oral Implantol.* 2001;27:73–76.
20. Cochran DL, Schenk RK, Lussi A, Higginbottom FL, Buser D. Bone response to unloaded and loaded titanium implants with a sandblasted and acid-etched surface: a histometric study in the canine mandible. *J Biomed Mater Res.* 1998;40:1–11.
21. Wennerberg A, Albrektsson T, Andersson B, Krol JJ. A histomorphometric and removal torque study of screw-shaped titanium implants with three different surface topographies. *Clin Oral Implants Res.* 1995;6:24–30.
22. Titanium Alloy Ti 6Al-4V ELI – Carpenter Technical Data-sheet. Wymissing, Pa: CRS Holdings Inc; 2011.
23. Titanium and titanium alloys. In: Campbell FC, ed. *Elements of Metallurgy and Engineering Alloys.* Materials Park, Ohio: ASM International; 2011.
24. Wennerberg A, Albrektsson T. Effects of titanium surface topography on bone integration: a systematic review. *Clin Oral Impl Res.* 2009;20(suppl 4):172–184.
25. Li Y, Lee SS, Zhang W, Aprecio R, Zunt SL. Tissue response to two mini dental implants in miniature swine. *J Dent Res.* 2012; 91(spec iss A):349.
26. Cosme DC, Baldisserotto SM, Canabarro SA, et al. Bruise and voluntary bite force in dentate adults. *Int J Prosthodont.* 2005; 18:328–332.
27. Brunski JB. In vivo bone response to biomechanical loading at the bone/dental-implant interface. *Adv Dent Res.* 1999;13:99–119.
28. Kim Y, Oh T-J, Misch CE, Wang H-L. Occlusal considerations in implant therapy: clinical guidelines with biomechanical rationale. *Clin Oral Implant Res.* 2005;16:26–35.
29. Vigolo P, Givani A, Majzoub Z, et al. Clinical evaluation of small-diameter implants in single-tooth and multiple-implant restorations: a 7-year retrospective study. *Int J Oral Maxillofac Implants.* 2004;19:703–709.