

IMMEDIATE PLACEMENT OF MULTIPLE MINI DENTAL IMPLANTS INTO FRESH EXTRACTION SITES: A CASE REPORT

Dennis Flanagan, DDS

This case report discusses the immediate placement of 3 mini dental implants into 3 fresh extraction sockets. The implants were used to support a splinted fixed partial denture. Immediately placing implants of a very small diameter into fresh extraction sockets to support a fixed partial denture is possible. Some implant sites cannot accept standard-sized implants because of length or width deficiencies. Very small diameter implants may be able to support fixed prostheses in these sites.

Key Words: dental implant, small diameter dental implants, fixed partial denture

INTRODUCTION

Patients can present with compromised teeth that are unrestorable and require extraction. The resulting edentulous site may not be amenable for conventional, standard-sized (3.75 mm diameter) dental implant placement and subsequent fixed prosthetic construction because of inadequate site length and width. There have been several studies using small diameter (2.75–3.3 mm diameter) implants but no high-quality prospective studies of the 2-mm diameter variety.^{1–8} Nomenclature has been confusing. Orthodontic anchorage implant have been named “mini” based on the short length,⁹ but some have suggested that implants be labeled by diameter as follows: reduced diameter (3.25–3.5 mm), small diameter (2.5–3.2 mm), and mini dental implants (1.8–2.4 mm).

Immediate placement of dental implants may preclude dramatic postextraction bone loss.¹⁰ However, these studies used standard-sized implants. There are no studies that address the use of mini dental implants and postextraction bone loss. Smaller implants may impede osseous blood supply less than standard-sized implants and may produce less bone

displacement. The ability of mini implants to resist chronic occlusal loading forces has not been well studied.

Very short implants are, however, able to resist the small forces for orthodontic anchorage.⁹

A site length may also be inadequate for standard-sized implants. That is, they may not fit appropriately allowing for adequate implant and/or tooth spacing. Inter-implant spacing for blood supply and osseous healing is desirable.¹¹ Mini dental implants may be placed to accomplish this. Placing 1-piece mini dental implants immediately into fresh extraction sockets has been reported for removable overdentures.¹²

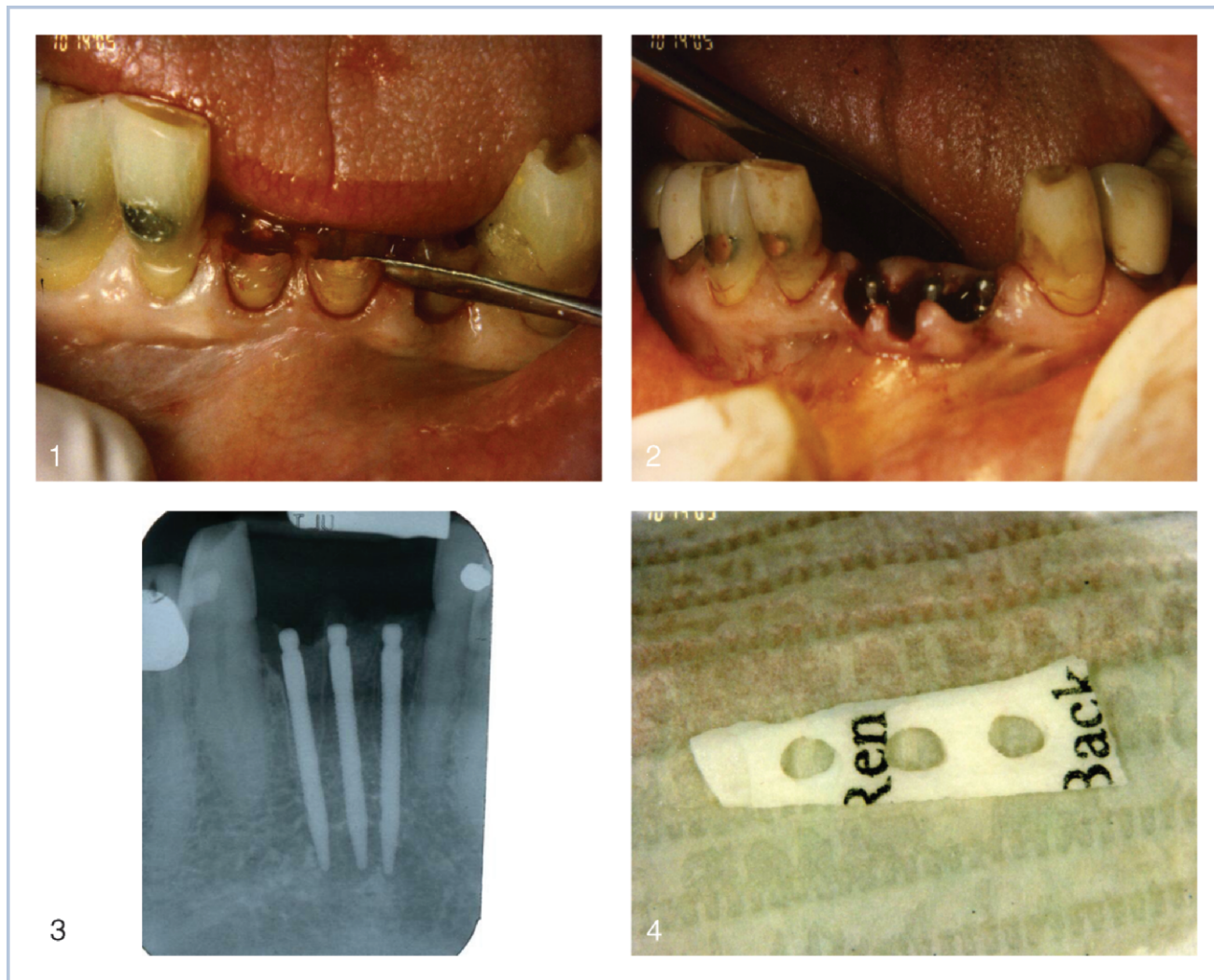
The occlusal scheme for any implant-supported prosthesis has yet to be universally agreed upon.¹³ Some implantologists relieve the occlusion of implant-supported restorations in a mixed, natural-tooth-implant situation to account for the intrusion allowed by the tooth periodontal ligament.⁷

This case report describes the removal of 3 mandibular anterior teeth and the immediate placement of 3 very small diameter 1-piece implants and subsequent fixed prosthetic construction.

CASE REPORT

A 59-year-old man presented with fractured teeth (Nos. 23, 24, and 25; Figure 1). After clinical and radiographic examinations, these teeth were deemed

Dennis Flanagan, DDS, is in private practice in Willimantic, Conn. Address correspondence to Dr Flanagan at 1671 West Main St, Willimantic, CT 06226. (e-mail: dffdds@charter.net)



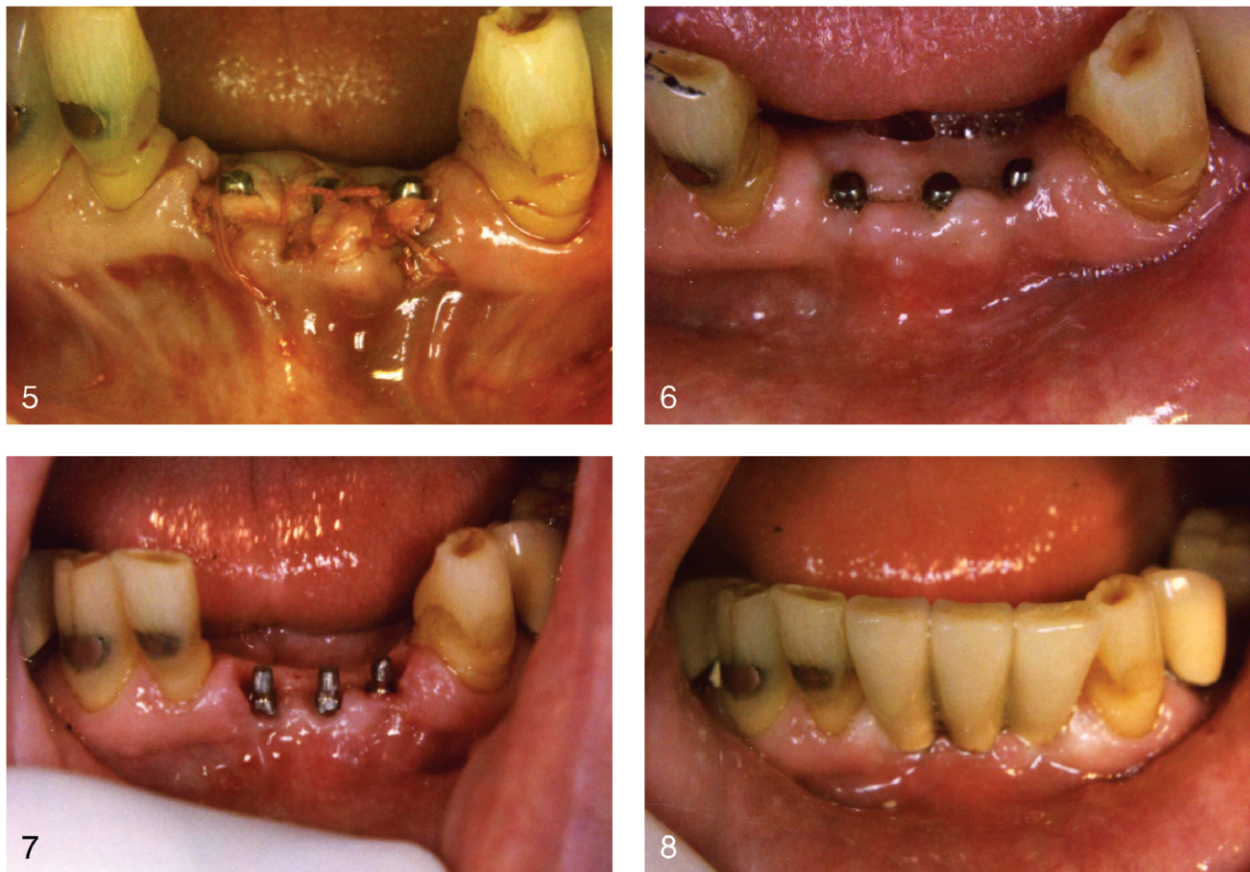FIGURES 1-4. FIGURE 1. Teeth Nos. 23-25 were deemed unrestorable and were extracted by sectioning and removing the remaining roots. FIGURE 2. The osteotomies were made to be as parallel as possible, and the implants were installed. FIGURE 3. A radiographic view of the installed implants. FIGURE 4. A piece of acellular dermal graft was festooned and punched to fit over the implants.

unrestorable without heroic treatment, and the resulting prognosis was guarded to poor. Options were discussed with the patient, who chose extraction, implant placement, and fixed splinted crowns.

Local infiltration anesthesia was obtained with articaine 4% with 1:100 000 epinephrine (Septocaine, Septodont, New Castle, Del). The residual roots were atraumatically removed by drill sectioning and elevated by use of a periosteal elevator. Even with careful extraction technique, a thin portion of facial plate fractured and was removed. The sockets were curetted. Each site was prepared to accept a 1.8 × 18 mm (Imtec, Ardmore, Okla) 1-piece mini dental implant. Attention was given to keep the osteotomies as parallel as possible (Figures 2 and 3).

Each implant was placed according to the manu-

facturer's instructions. The voids between the implants and bone sockets were filled with particulate allograft (nondemineralized bone, Pacific Coast Tissue Bank, Los Angeles, Calif) and a festooned piece of acellular dermal allograft (Alloderm, LifeCell Corp, Branchburg, NJ) was placed over the site to cover gingival voids. The dermal piece was measured to fit over the implants (Figure 4). No osseous barrier membrane was used. No undermining of the mucoperiosteal tissue was performed so as to minimize trauma and loss of blood supply from the periosteum. A punch was used to provide holes for each implant so that the dermal allograft could fit over the implants and down onto the site and under the gingival flaps to cover and contain the graft material and implant site. The gingiva and dermal graft were held with 4-0 polyglactin 910



FIGURES 5-8. FIGURE 5. The acellular dermal graft was sutured under the gingival flap to close the site and contain the particulate bone allograft material. FIGURE 6. The site healed uneventfully. FIGURE 7. The percutaneous portions were slightly prepared for parallelism and impressed for splinted fixed partial denture construction. FIGURE 8. The final prosthesis was cemented with zinc phosphate cement.

suture (Vicryl, Ethicon, Somerville, NJ) (Figure 5). Initial implant stability was attained. The patient was orally administered 1000 mg amoxicillin and prescribed amoxicillin 875 mg twice a day and chlorhexidine oral rinses twice a day. Pain was controlled with 600 mg of orally administered ibuprofen as needed.

A healing time of 4 months was observed. Immediate loading was considered but deemed too great a risk, and the patient was not averse to not wearing a provisional prosthesis.

At the first prosthetic appointment the gingiva was locally anesthetized with articaine, and the protruding implant posts were evaluated for stability (Figure 6). Having been judged osseointegrated they were then lightly prepared for parallelism (Figure 7). They were impressed with a polyvinyl siloxane (Imprint, 3M ESPE, St Paul, Minn) impression material, an acrylic provisional cement, and a 3-unit noble alloy splinted fixed partial denture was constructed. The incisal edges

were slightly shy of occluding with the maxillary incisors and did not contact in excursions. The final restoration was cemented provisionally for 1 week for the patient and his family to approve. It was then finally cemented with zinc phosphate cement (Fleck's Cement, Mizzy, Cherry Hill, NJ) (Figure 8).

The splinted fixed partial denture has been successfully functioning for 2 years with no complications. There has been no radiographically apparent bone loss, symptoms, bleeding on probing, or clinical signs of inflammation and mobility.

DISCUSSION

Many prospective implant sites cannot accept standard-sized implants because of unavailable length or atrophied bone width. This case report demonstrates that mini dental implants can be successfully used to restore such sites, at least in the short term. Adequate

bone is needed to encase each implant, and there needs to be adequate blood supply to maintain osseous and gingival health. Mini dental implants offer smaller physical impedance to the vasculature and less bone displacement compared with standard-sized implants. This may be an important issue with some sites. Immediate placement of implants into fresh extraction sockets may preserve bone and speed treatment.

These implants were placed with particular attention to keeping the osteotomies as parallel as possible to minimize the preparation of the percutaneous abutment. The splint construction was planned to be conventional. Because of the very small diameter, there is not much metal to waste during preparation to counter an unparallel implant. Circumspection during abutment preparation is warranted. Construction of conventional fixed units helps to control treatment costs.

This patient did not desire to wear a provisional appliance. However, if it were necessary an Essix (Essix Raintree, Metairie, La) type tooth-borne appliance would have been constructed. This type of appliance does not contact the implants or the surgical site.

There are caveats to heed. Initial osteotomy parallelism should be observed. Initial implant stability is needed for osseointegration healing to occur. Primary closure and graft material containment may be important.

CONCLUSIONS

Immediate placement of multiple mini dental implants into fresh extraction sockets can support a medium-span fixed partial denture.

ACKNOWLEDGMENT

The author appreciates the kind and gentle redaction of Danielle Green, DMD.

REFERENCES

1. Romeo E, Lops D, Amorfini L, Chiapasco M, Ghisolfi M, Vogel G. Clinical and radiographic evaluation of small-diameter (3.3-mm) implants followed for 1–7 years: a longitudinal study. *Clin Oral Implants Res.* 2006;17:139–148.
2. Comfort MB, Chu FC, Chai J, Wat PY, Chow TW. A 5-year prospective study on small diameter screw-shaped oral implants. *J Oral Rehabil.* 2005;32:341–345.
3. Vigolo P, Givani A, Majzoub Z, Cordioli G. Clinical evaluation of small-diameter implants in single-tooth and multiple-implant restorations: a 7-year retrospective study. *Int J Oral Maxillofac Implants.* 2004;19:703–709.
4. Kido H, Schulz EE, Kumar A, Lozada J, Saha S. Implant diameter and bone density: effect on initial stability and pull-out resistance. *J Oral Implantol.* 1997;23:163–169.
5. Kanie T, Nagata M, Ban S. Comparison of the mechanical properties of 2 prosthetic mini-implants. *Implant Dent.* 2004;13:251–256.
6. Davarpanah M, Martinez H, Tecucianu JF, Celletti R, Lazzara R. Small-diameter implants: indications and contraindications. *J Esthet Dent.* 2000;12:186–194.
7. Flanagan D. Implant-supported fixed prosthetic treatment using very small-diameter implants: a case report. *J Oral Implantol.* 2006;32:34–37.
8. Shatkin TE, Shatkin S, Oppenheimer BD, Oppenheimer AJ. Mini dental implants for long-term fixed and removable prosthetics: a retrospective analysis of 2514 implants placed over a five year period. *Compend Contin Educ Dent.* 2007;28:92–99.
9. Fritz U, Diedrich P, Kinzinger G, Al-Said M. The anchorage quality of mini-implants towards translatory and extrusive forces. *J Orofac Orthop.* 2003;64:293–304.
10. Schropp L, Kostopoulos L, Wenzel A. Bone healing following immediate versus delayed placement of titanium implants into extraction sockets: a prospective clinical study. *Int J Oral Maxillofac Implants.* 2003;18:189–199.
11. Mazor Z, Steigmann M, Leshem R, Peleg M. Mini-implants to reconstruct missing teeth in severe ridge deficiency and small interdental space: a 5 year case series. *Implant Dent.* 2004;13:336–341.
12. Ahn MR, Choi JH, Sohn DS. Immediate loading with mini dental implants in the fully edentulous mandible. *Implant Dent.* 2004;13:367–372.
13. Kim Y, Oh T-J, Misch CE, Wang H-L. Occlusal considerations in implant therapy: clinical guidelines with biomechanical rationale. *Clin Oral Implant Res.* 2005;16:26–35.