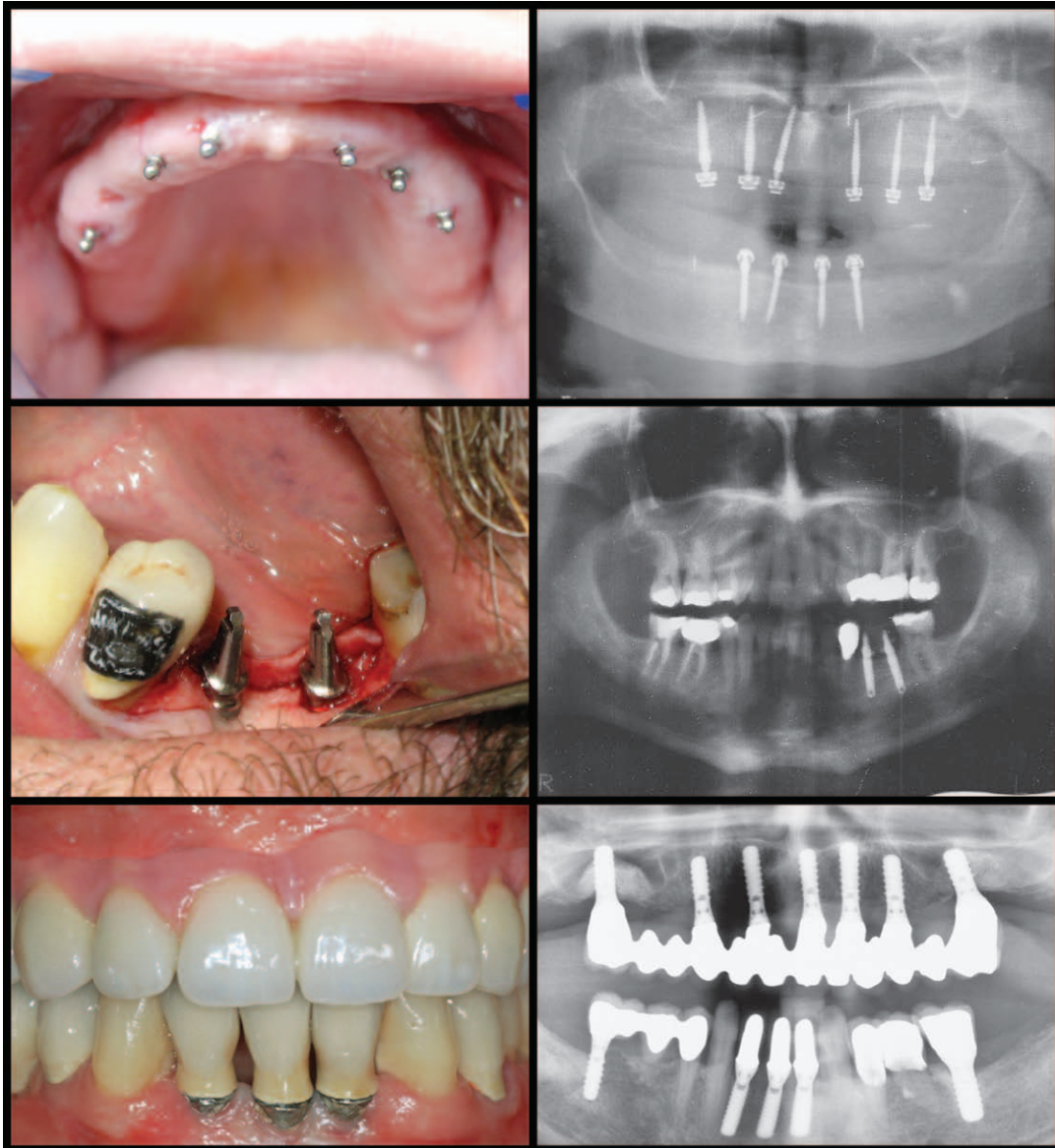

Implant Design and Implant Types



Sponsored by:

BIOHORIZONS®

The Mini Dental Implant in Fixed and Removable Prosthetics: A Review

Dennis Flanagan, DDS^{1*}
Andrea Mascolo, DDS²

Dental implant treatment can restore oral function to edentulous patients. Recently, mini implants have been shown to be successful in minimally invasive treatment. There are initial reports of mini implants retaining removable prostheses and supporting fixed partial and complete dentures. This article reviews the treatment of edentulous patients with prostheses and mini implants and offers guidelines for successful outcomes.

Key Words: dental implant, mini implant, small-diameter implant, minimally invasive, flapless surgery, prosthesis, fixed prosthesis, removable prosthesis

INTRODUCTION

The use of dental implants to replace natural teeth has become commonplace in contemporary restorative and surgical dental practices throughout the world.

Substantiation of their efficacy has been well documented in the dental literature. There have been many advances in surgical techniques and implant design features, and the use of implants in edentulous sites can be successful and can have predictable, functional, and esthetic outcomes.

A growing body of data suggests that mini dental implants can be used to retain removable complete and partial dentures in selected patients. Much of the research has been done on mini implants for orthodontic use. Orthodontic forces applied are much less than occlusal forces, and they are unidirectional and constant, unlike occlusal forces.

Mini implants may be relatively easy to place and restore with appropriate preoperative data collection, such as osseous ridge contour and gingival quantity. Additionally, there is some evidence that in highly selected situations, mini dental implants can be used to support fixed partial or complete dentures.¹⁻³

Mini implants may be immediately loaded in the appropriate osseous situations and may provide an alternative treatment if osseous conditions preclude a standard sized implant approach.^{2,3,11-14} In situations where there is an inadequate interdental space, reduced interocclusal space, convergent adjacent tooth roots or close proximity of adjacent tooth roots or narrow atrophic osseous contour, mini implants may be appropriate.¹⁻³

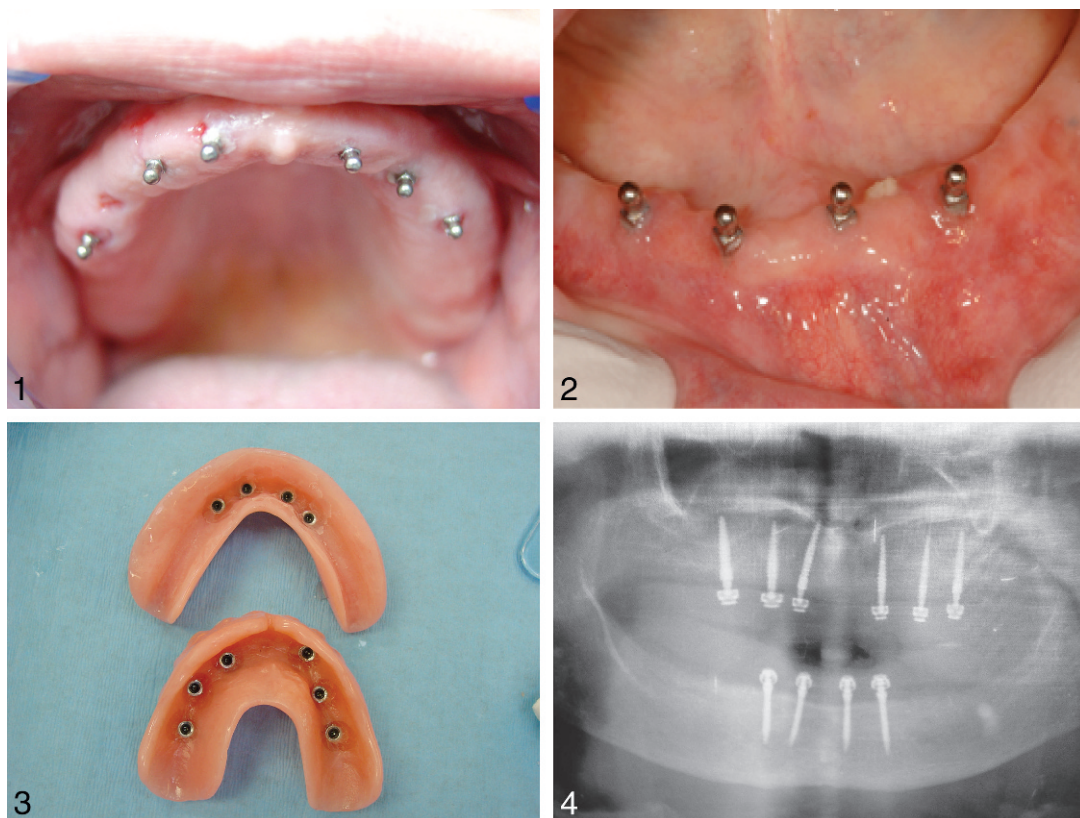
Mini implants are consistent with the trend towards minimally invasive dentistry. Minimally invasive dentistry has been brought to the forefront by some practitioners and may be applied to implant dentistry where appropriate. Small diameter or mini implants may provide solutions in patients where there is severe osseous atrophy or systemic

¹ Private practice, Willimantic, Conn.

² Private practice, Allessandria, Italy.

* Corresponding author, e-mail: dffdds@comcast.net

DOI: 10.1563/AAID-JOI-D-10-00052.1



FIGURES 1-4. **FIGURE 1.** Mini implants can retain a maxillary removable complete denture (Dr Todd Shatkin). **FIGURE 2.** Four mini implants that retain a removable complete mandibular denture. **FIGURE 3.** Intaglios with retainers in place to retain maxillary and mandibular removable complete dentures (Dr Todd Shatkin). **FIGURE 4.** Panoramic radiograph of maxillary and mandibular mini implants that retain removable complete dentures (Dr Todd Shatkin).

conditions that may contraindicate protracted standard sized implant treatment. For example, a severely debilitated patient may tolerate the placement of 4 mini dental implants with immediate loading to facilitate the retention of a removable mandibular complete denture but not able to tolerate the protracted treatment time required for standard sized implants.³

The objective of this article is to discuss the appropriate use of mini dental implants and to begin to establish guidelines for their use.

REMOVABLE PROSTHETICS

Mini implants can retain maxillary or mandibular removable prostheses (Figures 1 through 4). However, the supporting bone should be of the Misch type I or II for

appropriate long-term success. Atrophic bone is usually of these types.

Mini implants can also provide an immediate solution for patients with atrophic edentulism. Successful immediate loading of mini implants is related to primary stability for retention of removable dentures.^{1-3,11,12} When the implants are placed in denser types of bone, with an insertion torque of at least 30 Ncm, they may be immediately loaded to retain an overdenture. On completion of the procedure, the patient immediately has a stable functional denture. This treatment can be inexpensive and expeditious compared with standardized implant treatment.

Mini implants were initially designed by manufacturers to stabilize complete overdentures but quickly evolved as devices for prosthetic retention and support because of

the success of clinical cases.¹⁵⁻¹⁹ When placed in dense bone mini implants can be immediately loaded to retain removable complete and partial dentures. The implant is surgically placed and the retainer is embedded in the acrylic base of the denture in a pick-up technique.

Just because the bone is dense does not ensure 100% success, however. Occlusal forces may overload the implant and cause a failure.

Survival analyses demonstrate the long-term high performance of mini dental implants used for denture stabilization. Survival analyses of mini implant have rates more 90% depending on methodology and survival criteria.^{1,2,12,20}

The minimum number of mini implants required for appropriate retention of complete removable dentures may be 6 in the maxilla and 4 in the mandible.^{1,2,12,20} The parallelism of mini implants for overdentures generally should not exceed 20 degrees to avoid nonseating of the denture and conversion of axially directed loads to off-axial loads by the angled position of the implant.^{1-3,12,21} A surgical guide may be needed to ensure close parallelism for mini-implant placement.

FIXED PROSTHETICS

In sites where there is osseous atrophy or site-length attenuation, mini implants may be placed to support fixed restorations in highly selective patients (Figures 5 and 6). Esthetic concerns arise. The esthetic zone is wherever the patient deems it to be. Patient expectations may be unrealistic and acceptance of potentially smaller prosthetic coronas may be objectionable to certain patients.

Immediate loading of mini implants may not be appropriate for fixed appliances. Fixed prosthetics may apply much greater off-axial forces, which may induce micro-

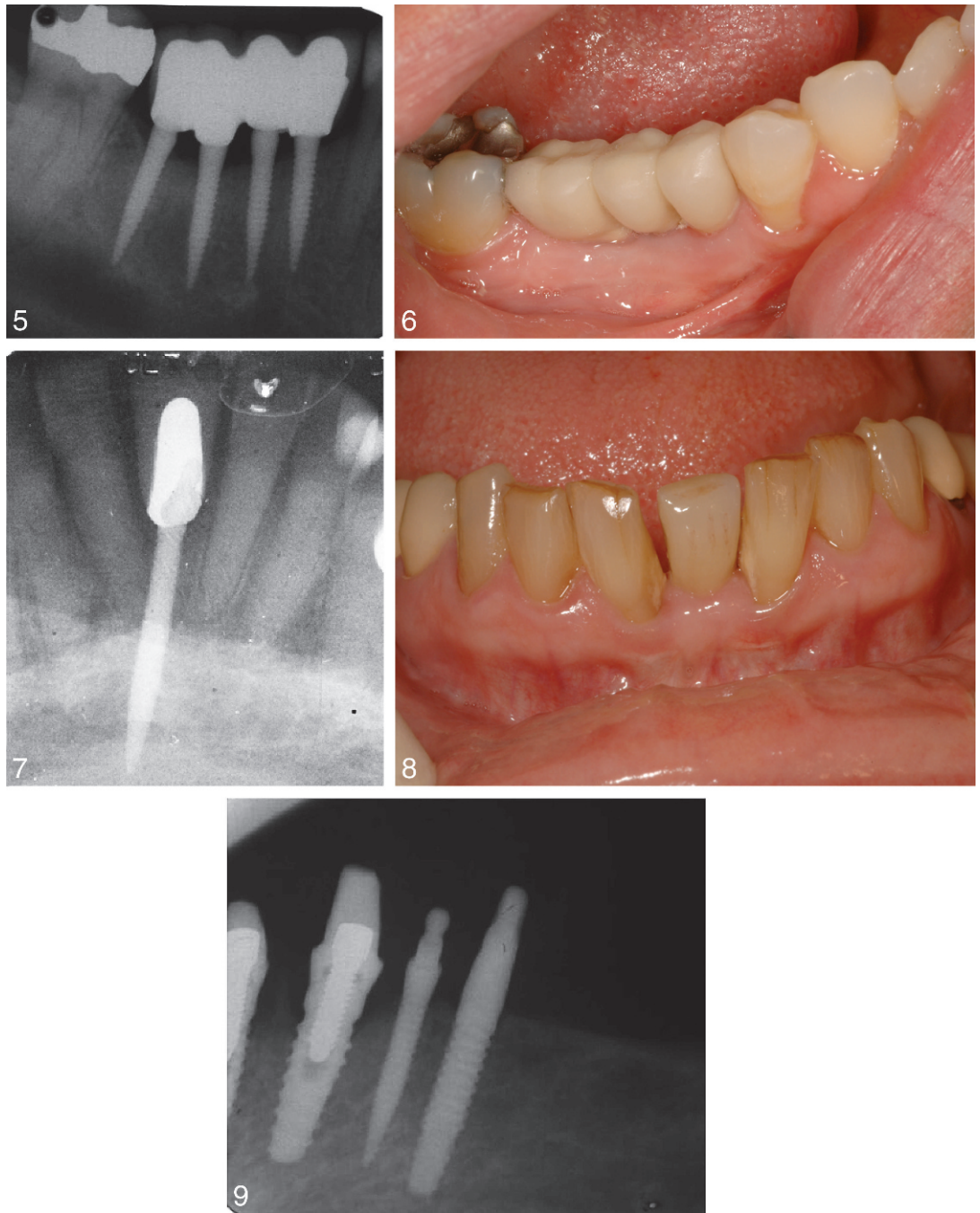
movement and result in the implant failing to integrate or a delayed loss of integration. Clinical caution should be exercised in these cases. Bone should be Misch type I or II, and an occlusal scheme that distributes occlusal loads evenly or an implant protective occlusal scheme should be used. However, there is little published evidence to confirm fixed mini-implant-supported complete or partial denture treatment in the maxilla.¹⁻³

Although a minimum of 6 implants may be needed to retain a maxillary removable complete denture, 10 to 12 implants may be needed to support splinted fixed complete maxillary prostheses.¹⁻³ Occlusal and masticatory forces are distributed over multiple splinted implants, thus reducing the relative load on any single implant by increasing the surface area loaded against the supporting bone.³

Two mini implants may be used for certain mandibular tooth-bound molar sites to accept a splinted crown restoration.^{3,22} Generally, these sites have shortened site lengths where a standard diameter implant may not fit with adequate tooth-to-implant spacing. Two mini implants can resist axial forces. However, rounded and narrow prosthetic teeth may be required to present a small occlusal table to minimize off-axial forces.^{2,3}

Single mini implants may support single crown restorations (Figures 7 and 8). Sites with short interdental space (less than 5 mm), such as maxillary lateral and mandibular incisors, and sites where tooth movement has imposed on the site length or the local anatomy is diminutive may accept a single mini implant.^{3,23} Anterior sites may be more appropriate because of lower occlusal forces.

Surgical guides may be needed for single or multiple mini-implant placements for fixed prosthetics.² These guides may be constructed from computerized tomograms or directly on a working cast by a laboratory technician.



FIGURES 5-9. **FIGURE 5.** Radiograph of 4 mini implants supporting a fixed splinted prosthesis. **FIGURE 6.** Splinted fixed prosthesis supported by 4 mini implants 3 years after surgery. **FIGURE 7.** A radiograph of a single mini implant that supports a single crown. **FIGURE 8.** Single crown supported by a single mini implant. **FIGURE 9.** Radiograph of 3 implants, a standard external Hex 4.1-mm diameter implant (far left) with bone loss to the first thread, a 3-mm mini implant with slight bone loss (far right), and a 1.8-mm mini implant with no apparent radiographic bone loss (center).

When mini implants are splinted in fixed partial or complete dentures, the adjacent implants are anchored to each other, dissipating force and minimizing the potential for implant micromovement. However, cement

loosening in one abutment may cause the fixed bridge to rotate slightly on the cemented abutment and lose osseointegration. An astute clinician may choose to definitively cement only mini-implant-sup-

ported prostheses to prevent this complication. The most retentive metal-to-metal cements are the resins and resin-modified glass ionomers. Care should be taken to ensure that the surface tension of the mixed cement does not prevent the cement from reaching the deepest part of the casting during the cementation procedure.

Mini implants are one piece and do not have separate abutments. Thus, there is no micro-gap issue. The coronal portion of the implant is the abutment and can be prepared for parallelism. A conventional crown and bridge impression technique is appropriate. Polyvinyl siloxane materials provide a satisfactory impression with little tissue toxicity. The coronal portion of the implant may require preparation to ensure parallelism and a passive fit. The implant surgeon should take care to place the mini implants closely parallel so that only minimum or no preparation is required. Excessive preparation may predispose the corona to metal fatigue fracture.

Natural teeth have periodontal ligaments and intrude under an occlusal load to as much as 200 μm . Implants do not intrude under an occlusal load. During clenching and grinding, the implant-supported prosthesis may be the only contact and may thus bear the full force of occlusion (26). Each patient is different in this regard, and this tooth intrusion is difficult to measure, so a built-in prosthetic occlusal relief or a gap in unforced maximal intercuspation of approximately 100 μm may be appropriate. This ensures that the implant-supported prosthesis will not bear the full force of the jaws during clenching.

LABORATORY CONSIDERATIONS FOR MINI IMPLANT FIXED PROSTHETICS

The coronas of mini implants are small. To construct fixed prostheses, the laboratory should use a polyurethane die material (Poly-

Die, Guilford, Conn) that is strong and durable for a working cast.³ An additional layer of die separator may be required to ensure a passive fit for the fixed prosthesis. The laboratory technician can be instructed to make a wax pattern with a large lingual support and metal circumferential margin to prevent distortion of the pattern during lifting and spruing. The casting and porcelain application is then performed in the usual fashion.

DISCUSSION

Mini dental implants have diameters ranging from 1.8 to 3.3 mm and lengths ranging from 10 to 15 mm. Standard-diameter implants range from about 3.4 to 5.8 mm. One advantage of mini implants is that in some sites they may be placed without raising a surgical flap, thus making the procedure minimally invasive and the surgery more tolerable.³⁻⁵

The use of mini dental implants to support or retain dental prostheses is a more recent development in implant dentistry and has become a controversial topic (Figures 1 and 2). Failures in some cases have dissuaded some clinicians from using mini implants. These failures may have been due to placement in inadequate bone sites or use of implants of inadequate length. Mini implants may require a minimum length of 11.5 mm to be successful. Appropriate osseous support depends on bone density; however, this comment is based on clinical experience and not on scientific research.^{1,2} Because mini implants have a very small diameter, the clinician should use implants that are as long as anatomically possible. This increases the bone-presenting profile and lessens the force per square millimeter applied to the bone under load.

The clinician must have knowledge of the osseous contour of the underlying bone because the implants require osseous support for proper osseointegration and long-

term function. These implants do require osseous support for proper osseointegration and long-term function. Without proper support, osseous dehiscences or fenestrations may result in an early or late failure under load. Computerized tomographic scans or ridge-mapping techniques can provide the clinician with contour information to ensure proper implant placement.⁶

Atrophic thin osseous ridges can be augmented with extra-cortical grafts or ridge expansion.⁷⁻⁹ Standard-sized implants may need 1.8 mm cortical thickness for appropriate osseous support while mini implants may require only 1 mm in certain situations.¹⁰ A 2 mm wide ridge that is split with a No. 15 scalpel or piezoelectric blade, expanded with a chisel-type osteotome and then apically drilled, can provide the minimum ridge width for mini-implant treatment.

The physical dimensions of the mini and standard-diameter implants can be compared using, for simplicity, 2 mm diameter and 10 mm length for the mini implant and 4 mm diameter and 10 mm length for the standard implant.

The circumference of a mini implant is $\pi \times \text{diameter (2 mm)} = 6.28 \text{ mm}$. The circumference of a standard 4-mm implant is $\pi \times 4.0 \text{ mm} = 12.56 \text{ mm}$. The mini implant has about 50% (6.28/12.56) of the percutaneous exposure compared with the standard-diameter implant.

Assuming a cylinder, the profile of a mini implant (2 mm \times 10 mm) is about half compared with a standard-diameter implant (4 mm \times 10 mm):

$$\begin{aligned} 2 \text{ mm} \times 10 \text{ mm} &= 20 \text{ square mm} \\ 4 \text{ mm} \times 10 \text{ mm} &= 40 \text{ square mm} \\ 20/40 &= 1/2 \end{aligned}$$

However, the volume of a mini implant is about 1/4 that of a standard-diameter implant. For simplicity the volume will be calculated as a cylinder for a 2 \times 10 mm mini implant and a 4 \times 10 mm standard implant:

$$\begin{aligned} \text{Volume} &= \pi \times r^2 \times h, \text{ where } \pi = 3.14, r = \\ &\text{radius, } h = \text{height;} \\ \text{Mini implant volume} &= 3.14 \times 1 \times 1 \times 10 \\ &= 31.4 \text{ cubic mm; and} \\ \text{Standard implant volume} &= 3.14 \times 2 \times 2 \\ &\times 10 = 125.6 \text{ cubic mm} \\ 125.6/31.4 &= 4 \end{aligned}$$

Thus, the standard-diameter implant is about four times the volume of the mini implant. Empirically, the larger volume displacement may inhibit healing angiogenesis and osteogenesis by physically blocking cellular in growth and cytokine activity.

Because mini implants have a very small diameter, the clinician should use implants that are as long as anatomically possible. This increases the bone-presenting profile and lessens the per square millimeter force applied to the bone under load.

Mini implants can be successfully used to retain or support prostheses in certain types of sites where bone volume is limited and where there is attenuated interdental or interocclusal space, reduced width of the residual ridge, convergent roots or close proximity of root trunks, congenitally missing maxillary lateral incisors, and pre- or postorthodontic treatment.^{1-3,13,17,24} Orthodontic and provisional implants generally have machined surfaces that are not rough so they can be easily removed at the end of treatment. These are temporary modalities. In addition, the forces applied to orthodontic implants are unidirectional and a small fraction of multidirectional occlusal forces.

If an implant site is inadequate, site development can be done. Augmentation techniques have been reported in the dental literature that facilitate placement of standard-diameter implants in a deficient ridge using blocks, particulated grafts, or ridge expansion.^{9,25} These surgeries may require several stages before prosthetic construction is initiated. Augmentation procedures have drawbacks such as prolonged treatment times, morbidity, and expense.⁸ Mini dental

treatment may be an appropriate alternative to standard-sized implant treatment in the appropriate patient.^{1-3,9}

As with standard-diameter implant treatment, there are relatively few systemic contraindications or relative contraindications to implant treatment. These relative contraindications include radiation therapy over 50 Gy, uncontrolled diabetes, severe osteoporosis, and excessive long-term cigarette smoking (Meier).

Minimally invasive mini implants can enable the treatment of patients with relative contraindications to standard-sized implant treatment, including geriatric patients and patients with psychological disorders (anxiety). Smokers are at a greater risk for mini implant failure compared with nonsmokers.^{2,35} Bruxism may be an adverse factor, however, this has not been established and may be minimized by an appropriate occlusal scheme.²⁶

In general, implant treatment may not be indicated for children under age 16 because of the dynamic osseous changes these patients undergo that cause anatomic changes for oral and osseous implant position.

Minimally invasive implant surgery allows clinicians to place implants using less surgical time, usually without extensive flaps, resulting in less bleeding and postoperative discomfort.^{2,3} The design of mini implants is such that insertion techniques minimize soft-tissue and bone displacement. Mini implants produce less osseous displacement than standard implants and may present less of a barrier for osseous healing and angiogenesis for osseointegration. A mini implant has about a quarter of the volumetric displacement of a standard-diameter implant of the same length. There is also less percutaneous exposure compared with standard-sized implants because the mini implant has about 50% less circumference.³ This may be important if oral hygiene is compromised

by presenting less of a surface area that may accumulate plaque.

Thin cortical bone and loose underlying trabeculation (types III to IV) of the posterior maxilla provide a decreased osseous matrix for osseointegration and may not be appropriate for mini-implant treatment.¹⁴ Bone types I and II may provide the best results in the long term. Furthermore, occlusal forces are much greater in the posterior and may be a consideration for treatment planning. The occlusal forces in the anterior are much less, and this area is more conducive for mini-implant use.

The healing period for mini implants may be shorter than that for standard-sized implants but this may be related to the denser bone quality into which mini implants are generally placed.¹¹ The denser bone required for mini implants may provide better initial support than less dense bone sites. One study, by Büchter and coworkers,²⁸ found no significant changes in the fixation of mini implant after 1 and 4 weeks of bone healing. Another study suggested that micromovements around the fixtures may not occur with immediate loading of mini implants.^{2,29} Immediate loading can be performed without loss of stability when the load-related biomechanics do not exceed an unknown upper limit of movement at the osseous crest.²⁹ However, these orthodontic applied loads were constant, low force, and not cyclic as in normal oral physiology, and these studies were performed in animals. The results may not be extrapolated to human application.

For initial stability of standard-diameter implants, a healing micromovement less than 75–150 μm and an insertion-placement torque value ≥ 32 N/cm may be needed for uneventful immediate loading.¹⁴ This immediate loading may in fact be nonfunctional loading because there is usually a large gap between the prosthesis and the opposing dentition when in maximum intercuspation.

These parameters may or may not be applicable to mini implants because the mini implant delivers more force per square millimeter to the bone.

Implants supporting fixed prostheses may be more successful than those supporting removable prostheses. Survival rates for fixed prostheses are 98.3%.²

Mini implant failures are attributed to mobility with or without suppuration; the failure time for these procedures usually will occur within 6 months.^{1,2}

The accumulating research in implant dentistry is usually on standard-diameter implants. This information may or may not be applicable to mini implants. An astute clinician needs to take into account the physical differences between these implants before applying any implant research to clinical treatment.

Mini implants do not appear to be subjected to postplacement bone resorption as much as standard diameter external hexed implants. Mini implants are one piece with no abutment microgap and have much less physical displacement, which may be responsible for this (Figure 9). Figure 1 shows radiographic bone levels around 3 implants. The far left implant is an external hex Implant (3-I, Palm Beach Gardens, Fla) shows radiographic bone loss to the first thread. The far right implant is a 3-mm one-piece implant (Biohorizons, Birmingham, Mich) that shows slight radiographic bone loss. The center implant, which shows little or no bone loss, is a 1.8 mm diameter mini implant (IntraLock, Ardmore, Okla).

Mini implants exert greater force per square millimeter on the supporting bone than standard-diameter implants. These forces may overload or fracture the supporting bone, causing the implant to fail.³ Less dense osseous sites, such as type IV, may be contraindicated for mini implants.^{12,30}

The presenting bone site needs to be evaluated during the osteotomy procedure.

If the bone is deemed to be less dense the clinician must judge the appropriate use of mini implants in that particular site. This requires knowledge of the underlying osseous contour. The osseous contour can be established with a computerized tomogram or ridge-mapping techniques.⁶

Attached gingiva of at least 2 mm is advantageous for flapless procedures and to prevent periodontal inflammation.^{3,31} Primary stability is the major concern for implant survival and insertion torque is an important parameter for stability. Appropriate torque placement may range from 32 to 50 Ncm for standard-diameter implants. Mini implants may require a higher torque to ensure postoperative stability.^{33,34} A torque of 50 Ncm may be a maximum for mini implants because of the potential for fracture of the implant body.

Occlusion and splinting are also important factors in mini implant survival. Although an implant-protected occlusal scheme is appropriate, splinting may be important to minimize cyclic-loading metal fatigue and implant coronal fracture.³²

Standard-sized implants may need 1.5–2 mm space from a natural tooth. Mini implants may only require 0.5 mm minimum space.

Primary stability is the main concern for implant survival, and insertion torque is an important parameter for stability. Appropriate torque placement may range from 32 to 45 Ncm for standard-sized implants, but mini implants may require a larger, 50 Ncm, torquing placement force to ensure postoperative stability (IntraLock).^{33,34} A torque of 50 Ncm may be a maximum for mini implant placement because of the potential for implant fracture.

Based on the experience of the authors, a minimum implant length of 11.5 mm may be required for immediate loading of mini implants and for retention of removable complete dentures.^{2,3} Although the implant

length does not contribute as much to the implant stability as does the diameter, this small amount may be enough to ensure immobility and resistance to occlusal loading. Thus, the longer length may provide additional surface at the bone/implant interface to compensate for the small diameter. A length of 10 mm in type I bone may be acceptable in patients with lesser occlusal biting forces.

Combination syndrome is an oral condition that is characterized by an edentulous maxilla with an atrophic maxillary anterior with fibrous replacement, supererupted mandibular anterior natural teeth, hypertrophic maxillary tuberosities, and atrophic edentulous posterior mandibles. This condition can be appropriately treated with mini implants. The maxillary complete denture is usually unstable because of the compressible maxillary anterior tissue. Because there is no posterior support for the occlusion, the denture releases the posterior seal by the anterior compression against the maxillary anterior fibrous tissue. Posterior support can be provided by placing mini implants in the atrophic posterior mandible to support fixed splinted crowns that occlude with the posterior maxillary denture teeth. Generally, the atrophic bone in the posterior mandible is narrow but can have enough height to avoid the neurovascular canal. A lingualized or zero-degree occlusal scheme is appropriate.

CONCLUSIONS

Mini dental implants may be appropriate to retain removable prostheses and support fixed complete and partial dentures. Anatomic locations, bone quality, esthetic considerations, and protective occlusal schemes are keys to ensure successful treatment outcomes. Several low-level studies have demonstrated the feasibility, predictability, and relative efficacy of mini-implant treat-

ment. Following are suggested initial guidelines for mini implant use:

- Type I and II (Misch) bone sites are most appropriate for mini implants
- Minimum of 1-mm thickness of facial and lingual cortical bone
- Approximately 100 μ m occlusal relief for fixed prosthetics
- A rounded minimal occlusal table
- Minimum space of 0.5 mm between tooth and mini implant
- Minimum of 6 mini implants for removable complete dentures in the maxilla
- Minimum of 4 mini implants for removable complete dentures in the mandible
- Minimum of 10 mini implants for splinted fixed complete prosthetics in the maxilla
- Minimum of 8 mini implants for splinted fixed complete prosthetics in the mandible
- Implant protective type of occlusal scheme for fixed prosthetics
- Esthetic requirements are addressed preoperatively
- Polyurethane working die material or material of similar durability
- Extra die separator may be indicated

Most of the mini-implant evidence is based on retrospective data, case series, or uncontrolled studies. Randomized, controlled, prospective, longitudinal human trials are needed to further validate this treatment.

REFERENCES

1. Shatkin TE, Shatkin S, Oppenheimer AJ, et al. A simplified approach to implant dentistry with mini dental implants. *Alpha Omegan*. 2003;96:7-15.
2. Shatkin TE, Shatkin S, Oppenheimer. Mini dental implants for the general dentist. *Compend Contin Educ Dent*. 2003;24(S1):26-34.
3. Flanagan D. Fixed partial dentures and crowns supported by very small diameter dental implants in compromised sites. *Implant Dent*. 2008;17:182-191.
4. Flanagan D. Flapless dental implant placement. *J Oral Implantol*. 2007;33:75-83.
5. Hahn J. Single-stage, immediate loading, and flapless surgery. *J Oral Implantol*. 2000;26:193-198.
6. Flanagan D. A method for estimating preoperative bone volume for implant surgery. *J Oral Implantol*. 2000;26:262-266.

7. Lustmann J, Lewinstein I. Interpositional bone grafting technique to widen narrow maxillary ridge. *Int J Oral Maxillofac Implants*. 1995;10:568–577.
8. Nkenke E, Radespiel-Tröger M, Wiltfang J, Schultze-Mosgau S, Winkler G, Neukam FW. Morbidity of harvesting of retromolar bone grafts: a prospective study. *Oral Clin Implants Res*. 2002;13:514–521.
9. Misch CM, Misch CE. The repair of localized severe ridge defects for implant placement using mandibular bone grafts. *Implant Dent*. 1995;4:261–267.
10. Spray JR, Black CG, Morris HF, Ochi S. The influence of bone thickness on facial marginal bone response: stage 1 placement through stage 2 uncovering. *Ann Periodontol*. 2000;5:119–128.
11. Bulard RA. Mini implants. Part I. A solution for loose dentures. *J Okla Dent Assoc*. 2002;93:42–46.
12. Bulard RA, Vance JB. Multi clinic evaluation using mini-dental implants for long term denture stabilization: a preliminary biometric evaluation. *Compend Contin Educ Dent*. 2005;26:892–897.
13. Bulard RA. Mini dental implants: enhancing patient satisfaction and practice income. *Dent Today*. 2001;20:82–85.
14. Uribe R, Peñarrocha M, Balaguer J, Fulgueiras N. Immediate loading in oral implants. Present situation. *Med Oral Patología Oral Cirugía Bucal*. 2005;10(suppl 2):E143–E153.
15. el Attar MS, el Shazly D, Osman S, el Domiati S, Salloum MG. Study of the effect of using mini-transitional implants as temporary abutments in implant overdenture cases. *Implant Dent*. 1999;8:152–158.
16. Nagata M, Nagaoka S. Mini-implant is effective as a transitional fixation anchorage for transplantation of teeth. *Jpn J Conserv Dent*. 2002;45:69.
17. Sendax VI. Mini-implants as adjuncts for transitional prostheses. *Dent Implantol Update*. 1996;7:12–15.
18. Fenlon MR, Palmer RM, Palmer P, Newton JT, Sherriff M. A prospective study of single stage surgery for implant supported overdentures. *Clin Oral Implants Res*. 2002;13:365–370.
19. Petrungraro PS, Windmiller N. Using transitional implants during the healing phase of implant reconstruction. *Gen Dent*. 2001;49:46–51.
20. Morneburg TR, Proschel PA. Success rates of microimplants in edentulous patients with residual ridge resorption. *J Oral Maxillofac Implants*. 2008;23:270–276.
21. Watanabe F, Hata Y, Komatsu S, Ramos TC, Fukuda H. Finite element analysis of the influence of implant inclination, loading position, and load direction on stress distribution. *Odontology*. 2003;91:31–36.
22. Sato Y, Shindoi N, Hosokawa R, Tsuga K, Akagawa Y. Biomechanical effects of double or wide implants for single molar replacement in the posterior mandibular region. *J Oral Rehabil*. 2000;27:842–845.
23. Mazor Z, Steigmann M, Leshem R, Peleg M. Mini-implants to reconstruct missing teeth in a severe ridge deficiency and small inter dental space: a 5 year case series. *Implant Dent*. 2004;13:336–341.
24. Davarpanah M, Martinez H, Tecucianu JF, Celletti R, Lazzara R. Small-diameter implants: indications and contraindications. *J Esthet Dent*. 2000;12:186–194.
25. Tinti C, Parma-Benfenati S. Clinical classification of bone defects concerning the placement of dental implants. *Int J Periodontics Restorative Dent*. 2003;23:147–155.
26. Fritz U, Diedrich P, Kinzinger G, Al-Said M. The anchorage quality of mini-implants towards translatory and extrusive forces. *J Orofac Orthop*. 2003;64:293–304.
27. Massif L, Frapier L, Micallef JP. Insertion of mini-screws: with or without pre-drilling? *Orthod Fr*. 2007;78:123–132.
28. Büchter A, Wiechmann D, Koerdt S, Wiesmann HP, Piffko J, Meyer U. Load-related implant reaction of mini-implants used for orthodontic anchorage. *Clin Oral Implants Res*. 2005;16:473–479.
29. Comfort MB, Chu FC, Chai J, Wat PY, Chow TW. A 5-year prospective study on small diameter screw shaped oral implants. *J Oral Rehabil*. 2005;32:341–345.
30. Vigolo P, Givani A. Clinical evaluation of single mini-implant restorations: a five year retrospective study. *J Prosthet Dent*. 2000;84:50–54.
31. Linkevicius T, Apse P, Grybauskas S, Puisys A. The influence of soft tissue thickness on crestal bone changes around implants: a 1-year prospective controlled clinical trial. *Int J Oral Maxillofac Implants*. 2009;24:712–719.
32. Flanagan D, Ilies H, McCullough P, McQuoid S. Measurement of the fatigue life of mini dental implants: a pilot study. *J Oral Implantol*. 2008;34:7–11.
33. Dilek O, Tezulas E, Dincel M. Required minimum primary stability and torque values for immediate loading of mini dental implants: an experimental study in nonviable bovine femoral bone. *Oral Surg Oral Med Oral Pathol Oral Radiol Endod*. 2008;105:e20–e27.
34. Reddy MS, O'Neal SJ, Haigh S, Aponte-Wesson R, Geurs NC. Initial clinical efficacy of 3-mm implants immediately placed into function in conditions of limited spacing. *Int J Oral Maxillofac Implants*. 2008;23:281–288.
35. De Bruyn H, Collaert B. The effect of smoking on early implant failure. *Clin Oral Implants Res*. 1994;5:260–264.
36. Meijer GJ, Cune MS. Surgical dilemmas, medical restrictions and risk factors. *Ned Tijdschr Tandheelkd*. 2008;115:63–651.