

# Utilizing small diameter implants in replacing congenitally missing laterals

*Dr. Ara Nazarian explores an implant option for patients with smaller dental dimensions*

The management of small restorative areas in the esthetic zone has posed significant problems for the implant and restorative team. The lack of bone available for the surgeon as well as the lack of restorative space available between the adjacent teeth makes tooth replacement with implants challenging for both the restorative dentist and the laboratory technician. In the past, patients with congenitally missing teeth or microdontia have been treated with resin-bonded bridges, removable retainers, or cantilever crowns to avoid the use of standard-diameter implants and prosthetics in this area.

Too often, surgeons attempting to place standard-diameter implants have forced the restorative team to manage these small dimensions with a lack of adequate prosthetics because of the size and diameter of the fixture head. In addition, surgical complications, such as contact with the adjacent roots, dehiscences of the labial plate, or the “show through” of the titanium through thin soft tissues, has posed a significant complication risk when attempting to use implants for tooth replacement in these situations.

Recently, manufacturers in the implant industry have offered a 3-mm diameter implant design to address these challenges. Most of the implants available in the 3-mm size have been one-piece or unibody implants, which often necessitate conventional tooth-preparation techniques by the restorative team as well as standard cord-impression techniques for indexing the restorative margins. With some systems, there is no need for preparation due to a cervical marginal collar that can be captured utilizing a snap-in impression transfer.

### Case presentation

A young patient in her mid 30s presented to my practice for replacement of her congenitally

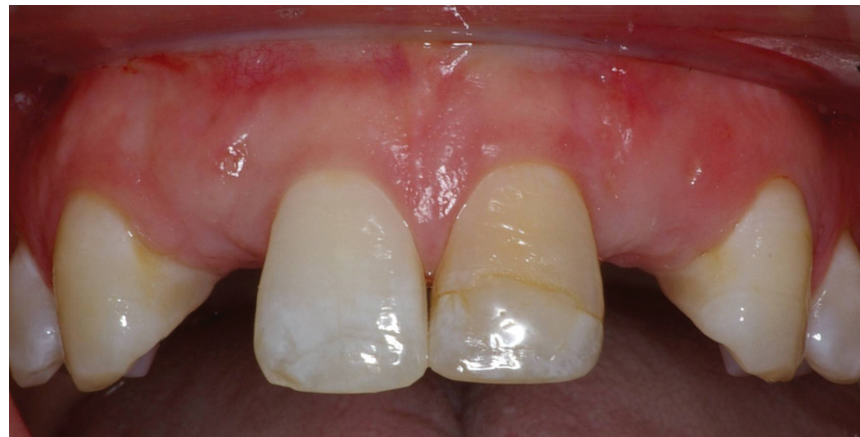

Figure 1: Retracted frontal view of area (pre-treatment)

missing maxillary lateral incisors (teeth Nos. 7 and 10) following orthodontic treatment. Based on the lack of mesial-distal space for a normal lateral incisor as well as the lack of distance between the adjacent natural tooth roots, it was apparent that only a small-diameter implant would facilitate tooth replacement in this region. The patient was also interested in restoring teeth Nos. 8 and 9 due to discoloration and breakdown. Tooth No. 9 had undergone endodontic therapy 10 years before due to a traumatic injury. After endodontic therapy was completed, the tooth was restored by her previous provider by rebonding on the broken portion and sealing the access opening with direct composite. A preliminary bone graft procedure was performed to gain adequate width facio-lingually using particulate graft (Grafton® DBM and MinerOss®, BioHorizons®) and tent screws, and after 6 months of healing, a CT scan was taken and formatted for the computer treatment-plan software through 3D Diagnostix.

Based on the preoperative clinical diagnosis using stone models, a wax-up, surgical guide, and CT scan, we were able to accurately treatment plan this case to make certain that no complications would arise from the conservative non-

flap approach. SimPlant® software (Materialise Dental) was used through 3D Diagnostix virtual assistance to precisely plan the placement of the one-piece implants, ensuring accuracy of placement in all three dimensions.

The maxillary anterior area of teeth Nos. 7-10 was anesthetized using 1.8 mL 4% Septocaine® (Septodont) with 1:100,000 epinephrine (Figure 1). Once anesthesia was administered, the site for the implant was begun with a 1.8-mm pilot drill through the surgical guide extending through the soft tissue using a surgical motor (AEU-7000E, Aseptico). The location



Ara Nazarian, DDS, maintains a private practice in Troy, Michigan, with an emphasis on comprehensive and restorative care. He is a Diplomate of the International Congress of Oral Implantologists (ICOI). His articles have been published in many

of today's popular dental publications. Dr. Nazarian is the director of the Reconstructive Dentistry Institute. He has conducted lectures and hands-on workshops on esthetic materials and dental implants throughout the United States, Europe, New Zealand, and Australia. Dr. Nazarian is also the creator of the DemoDent patient education model system. He can be reached at (248) 457-0500 or [www.aranazariandds.com](http://www.aranazariandds.com).

was centered facial-lingually as well as mesial-distally due to the metal sheaths within the surgical pilot guide.

The pilot drill was advanced to a depth of 16 mm, measuring from the tissue surface. This additional 2 mm was the same depth of the tissue height to bone. In other words, 14 mm for the osteotomy in bone and 2 mm for tissue thickness was created to place a 14-mm-long implant. A parallel pin gauge was placed in the site of the osteotomy, and an x-ray was taken to check the angulations of the pin between the adjacent teeth within the maxilla. Using a rotary tissue punch, provided in the OCO Biomedical surgical kit, a 3-mm outline was created over the initial osteotomy and the tissue plug was removed with a serrated curette (Dental USA). Because there was a thin band of attached gingiva, a countersink drill was used to countersink the implant collar. The final drill in the OCO Biomedical surgical drill is side-cutting only and used to form the final osteotomy because the depth was set by the pilot drill. Intermediate drills are not required in this system, which makes the drilling sequence easy to implement. Once the osteotomy was completed, a 3 mm x 14 mm I-Mini™ OCO Biomedical threaded implant was placed in the osteotomy using an implant finger driver until increased torque was necessary. The ratchet wrench was then connected to the adapter and the implant torqued to final depth, reaching a torque level of 65 Ncm. A postoperative radiograph was made of the implant to confirm ideal placement (Figures 2 and 3).

Once the implants were placed and prepared (Komet® abutment burs, H8566), teeth Nos. 8 and 9 were prepared utilizing diamond preparation burs (Komet® 5850) (Figure 4). Following sequential preparation of the maxillary teeth, a stick-bite registration was taken using Take-1 Advanced™ bite registration (Kerr). This stick-bite would aid the technician in preparing the model and mounting the case. It also communicated to the ceramist the orientation of the interpupillary line, so that the incisal edges of the final restorations would not appear canted.

After the 3 mm x 14 mm I-Mini™ OCO Biomedical implants were placed

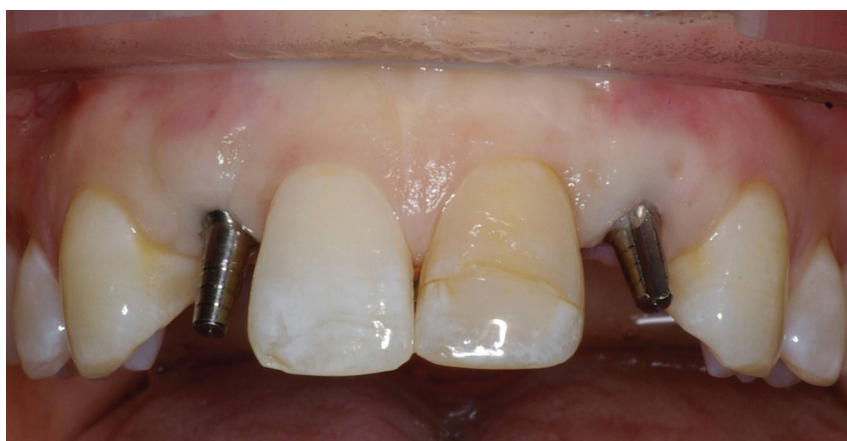

Figure 2: Placement of 3 mm x 14 mm I-Mini™ OCO Biomedical dental Implants

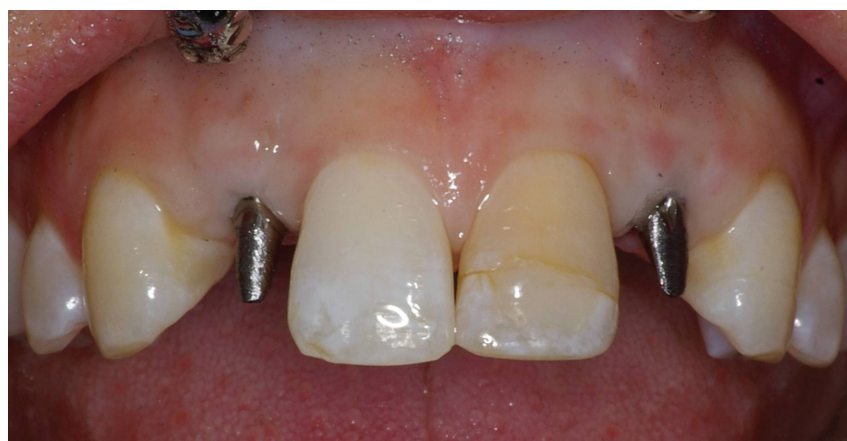

Figure 3: Preparation of implants

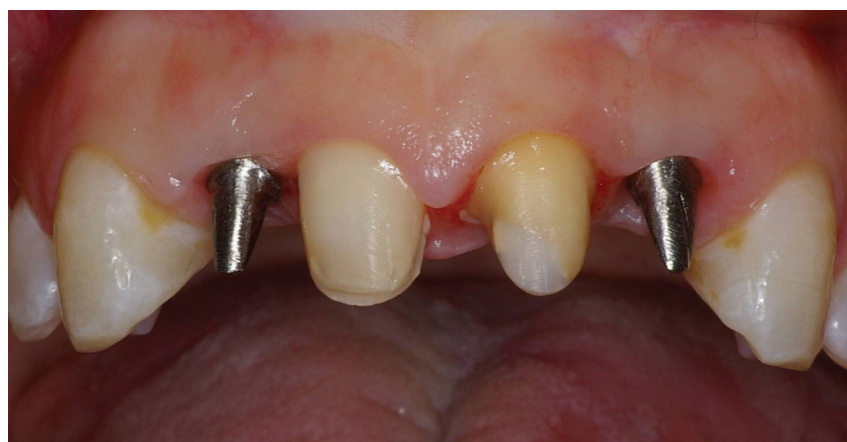

Figure 4: Preparation of teeth and implants

and maxillary centrals prepared, a temporary plastic snap cap was placed on the one-piece abutments and a polycarbonate provisional created from a wax-up was relined over the temporary caps and finished outside of the mouth using acrylic burs (Komet® USA). The immediate temporary was cemented using TempBond® Clear™ (Kerr) (Figure 5).

The implant was evaluated clinically after one week. The patient stated she had no postoperative

discomfort or swelling.

After 4 months of healing, the patient returned for definitive impressions for the final restorations that would consist of three crowns and one veneer. Once the patient was anesthetized and the temporaries removed, the preparations were cleaned using plain pumice (Preppies™ paste, Whip Mix Corporation). Utilizing Expasyl™ Strawberry (Kerr), we not only controlled hemorrhaging, but also achieved gingival retraction



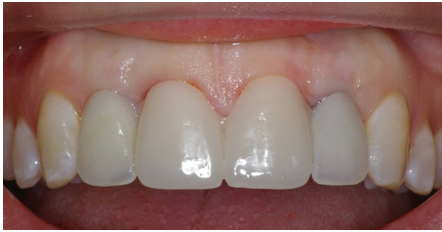

Figure 5: Provisional restoration

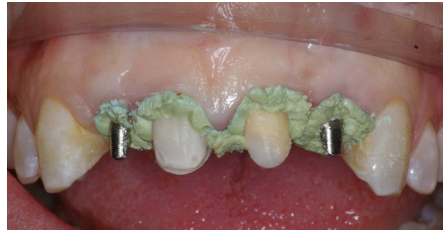

Figure 6: Retraction using Expasyl™

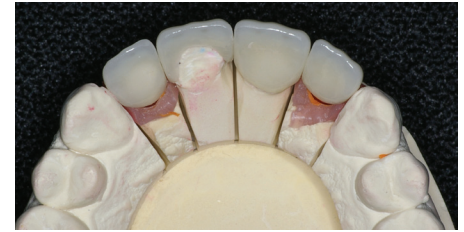

Figure 7: Lab work on restorations

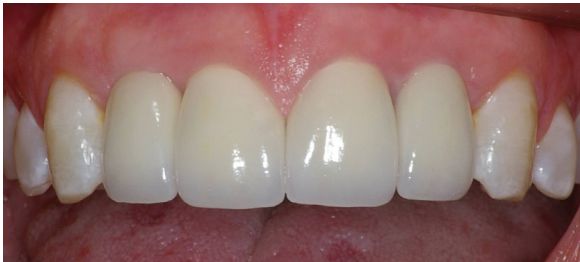

Figure 8: Retracted frontal view of final restorations

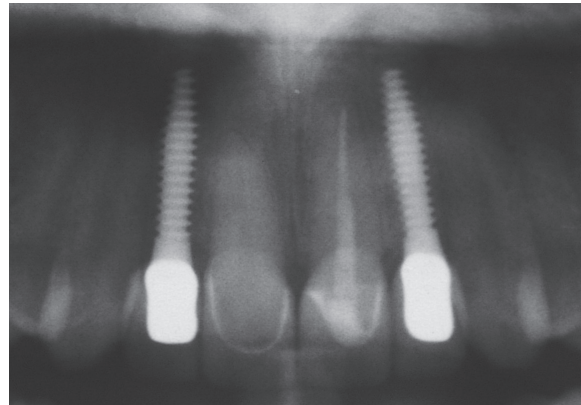


Figure 9: Radiograph of restorations seated

around the prepared teeth and implants (Figure 6). After approximately 2 minutes in the sulcus, the Expasyl™ was rinsed off with copious amounts of water. Impressions were taken using a fast setting polyvinyl material (Take-1 Advanced™, Kerr) and sent off to the laboratory (Burbank Dental Lab) for indexing and fabrication of the final restorations (Figure 7).

Note the bone preservation at the crest in the radiograph taken at 4 months. This may be a result of the lack of a microgap present with I-Mini™ OCO Biomedical dental one-piece implant.<sup>1-4</sup> Bone appears to be present above the neck of the implant and just below the chamfer margin of the abutment.

The laboratory was able to proceed with standard implant prosthetics, and the final cementable single-unit crowns were fabricated on a smaller prosthetic table. This allowed the restorative team to address the contours of the soft tissue and to develop the subtle esthetics necessary for small-diameter tooth replacement.

The final all-ceramic Lava™ restorations (3M), single-implant restorations were cemented using Maxcem Elite™ (Kerr) cement, and the feldspathic restorations on teeth Nos. #8 (veneer) and 9 (full

porcelain crown) were cemented into place with NX3 white opaque cement (Kerr). A slightly lighter shade was selected for the restorations because the patient desired to whiten her remaining teeth through bleaching (Figure 8).

The final radiographs, taken at 8 months postoperatively, are shown in Figure 9. Note the excellent bone response at the crest of the ridge around the one-piece 3 mm I-Mini™ OCO Biomedical dental Implants.

### Conclusion

The replacement of small incisor teeth in the esthetic zone has posed a challenge for providers in implant dentistry. Today, the availability of smaller-diameter one-piece implants with pre-machined contour abutments has assisted the dental team in restoring these challenging areas with dental implants rather than conventional prosthetic dentistry. The 3-mm one-piece I-Mini™ from OCO Biomedical has allowed clinicians to meet this challenge safely and accurately in an efficient, biologically sound, and esthetic fashion.

This clinical case report highlights the use of these smaller-diameter implants as an important

and vital part of the implant team's armamentarium in treating small-incisor replacement dilemmas. It is important to note that these one-piece implants are not to be used as small-diameter abutments for significant long-span bridge work, but have been designed specifically for the replacement of small-diameter incisors in the esthetic zone where they need to support single teeth. I have had much success with this form of tooth replacement and believe that it is an excellent option for our patients.

### Disclosure

Special thanks to Dr. Carl Misch for the particulate graft in this case, and to Tony Sedler from Burbank Dental Lab for the dental lab work. The author reports no conflicts of interest. **IP**

### References

1. Hermann JS, Buser D, Schenk RK, et al (2001) Biologic width around one- and two-piece titanium implants. *Clin Oral Implants Res* 12(6):559-571.
2. Hermann JS, Buser D, Schenk RK, et al (2000). Biologic width around titanium implants. A physiologically formed and stable dimension over time. *Clin Oral Implants Res* 11(1):1-11.
3. Sennerby L, Rocci A, Becker W, et al (et al) Short-term clinical results of Nobel Direct implants: a retrospective multicentre analysis. *Clin Oral Implants Res* 19(3):219-226.
4. Ostman PO, Hellman M, Albrektsson T, et al (2007) Direct loading of Nobel Direct and Nobel Perfect one-piece implants: a 1-year prospective clinical and radiographic study. *Clin Oral Implants Res* 18(4): 409-418.