

# IMPLANT-SUPPORTED FIXED PROSTHETIC TREATMENT USING VERY SMALL-DIAMETER IMPLANTS: A CASE REPORT

Dennis Flanagan, DDS

## KEY WORDS

Mini dental implant  
Compromised sites  
Occlusal scheme  
Bone density  
Bone-ridge length

A case report is presented where an edentulous mandibular anterior site is restored with very small- or mini-diameter (1.8-mm) dental implants. The surgical and prosthetic use of very small-diameter dental implants is discussed. Such implants can be successfully used in appropriate sites where there is adequate bone density for immediate implant stability and an implant-protected occlusal scheme.

## INTRODUCTION

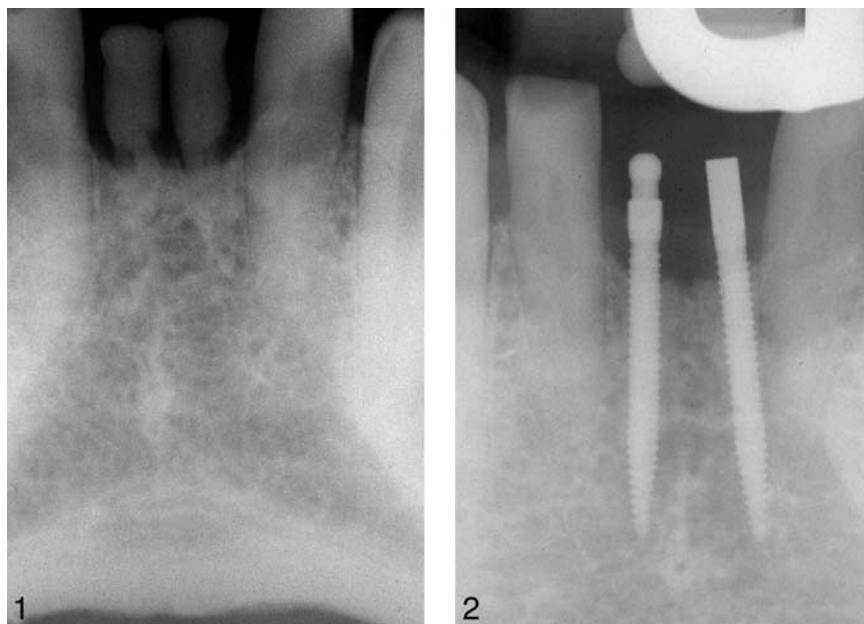
Patients present for implant treatment with variable amounts of bone volume, ridge length, and interocclusal space. Some sites are not amenable to the standard sizes of many available implants. Most dental-implant companies offer standard-diameter implants in the range of 3.75 to 4.2 mm, but smaller diameters are available from 2.0 to 3.3 mm. Implants with very small or mini diameters of 1.8 mm are also available (Imtec, Ardmore, Okla). These have primarily been used in multiples to retain complete overdentures in the maxilla and mandible.<sup>1,2</sup> The term *mini* has also been used to describe very short implants with standard diameters.<sup>3</sup> This case report demonstrates an uncommon compromised site that was restored with two 1.8-mm diameter implants

that support a splinted, 2-unit fixed partial denture prosthesis replacing the mandibular central incisors.

## CASE REPORT

The patient, a 42-year-old man, presented for restoration of his missing teeth #24 and #25. The deciduous central incisors had exfoliated with no succedaneous incisors (Figure 1). Radiographs and study casts were made for analysis. His occlusion was a class II division 2 with a 100% overbite compromising the interocclusal available space. Occlusal abrasion had occurred, further reducing the available interocclusal space. The ridge contour was mapped by a bone-sounding technique.<sup>4</sup> The length of the ridge was 11 mm. Clearly, standard-width implants would not fit in the space available without orthodontic treatment. The ridge length would not allow placement of small-diameter, 3.25-mm

Dennis Flanagan, DDS, is in private practice in general dentistry. Address correspondence to Dr Flanagan at 1671 West Main Street, Willimantic, CT 06226 (e-mail: dffdds@charter.net).



FIGURES 1–2. FIGURE 1. Preoperative radiograph. FIGURE 2. Postoperative radiograph of 1.8-mm diameter implants.

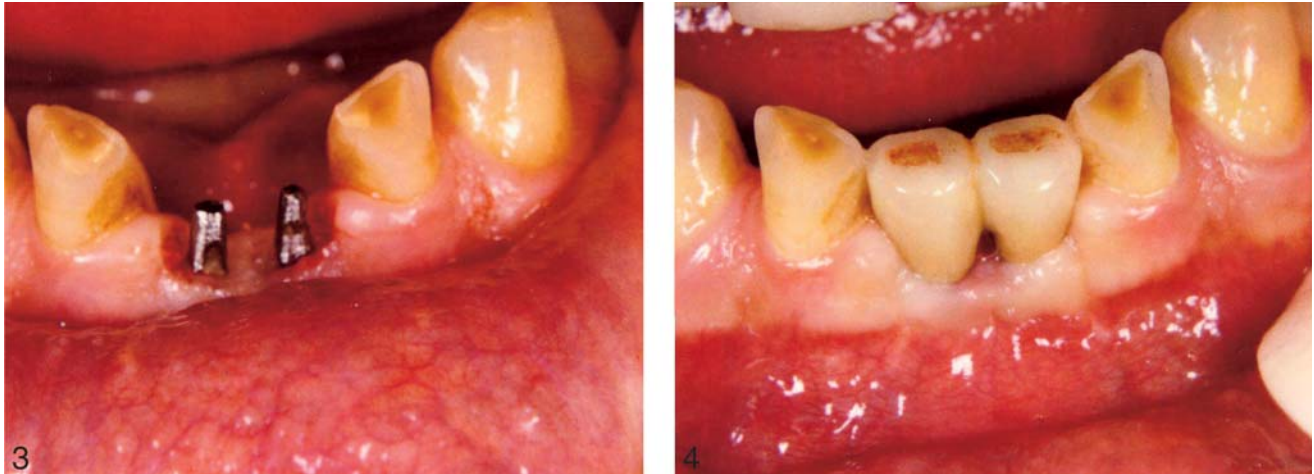implants. There would be 3 mm between each implant and 1.5 mm between each implant and its adjacent tooth, totaling 12.5 mm and thereby exceeding the 11 mm of available length. An orthodontic consultation was completed, but the patient decided against treatment. A discussion ensued that presented options for treatment. The placement of small 1.8-mm implants and subsequent placement of a fixed prosthesis replacing teeth #24 and #25 was decided upon. The patient accepted the treatment plan and that no provisional restoration would be placed during the healing integration or prosthetic construction phases. Immediate loading was considered but deemed too great a risk.

On the day of surgery, the patient was infiltrated in the anterior mandible, facially and lingually, with 1.8 mL of articaine (Septocaine). The sites were marked with a surgical guide. A split-thickness apically positioned flap was raised with

a #15C scalpel to increase the resulting zone of attached gingiva. Many small-diameter sites can be drilled with only an envelope incision. In fact, raising a flap may be unnecessary when there is adequate attached gingiva and the osteotomy can be performed directly through the gingiva. In this case, a flap was raised and each osteotomy was started with a #4 round burr. Then a 1.2-mm drill was used to complete the osteotomy to a 15-mm depth. This drill cannot be internally irrigated, so only external irrigation was used. The implants are placed with a specific technique as described by the manufacturer. Concisely, an implant is placed in the bone and turned with a thumb-wrench device. When the implant can no longer be easily turned into the bone, a ratchet device is used to complete the placement. It is important to note that when turning becomes difficult, after 1 complete turn of the implant, a 1-minute waiting period is observed to allow the bone

to recover from compression of the advancing implant. Not observing this waiting period may result in implant fracture, bone overcompression, or microfracture and subsequent loss of the implant. In this patient, the implants were placed without incident (Figure 2).

The patient was instructed in aftercare, and amoxicillin clavulic acid 875 mg and chlorhexidine oral rinse were prescribed, both to be taken twice per day. He was contacted by telephone the evening of placement and was doing well. He returned at 1 week for follow-up and had healed well with no complications. An integration and healing phase of 11 weeks was observed, whereupon he returned for construction of a fixed prosthesis. The anterior mandible was again infiltrated with a small amount of articaine (0.4 mL) for gingival anesthesia. The protruding occlusal or crestal portion of each implant was slightly prepared with a fine-diamond burr to achieve parallelism and to accept splinted-crowns-type prosthesis (Figure 3). The coronal aspect is very small at 1.8 mm wide and only 4 mm high. Overpreparation is not an option. Inventory problems forced the use of 2 different coronal designs. Impressions were made (Imprint, ESPE 3-M: St Paul, Minn.) but no provisional prosthesis was made. A 2-unit porcelain fused to noble metal splint was constructed that avoided direct centric and excursionary contacts. The laboratory technician was instructed to apply an extra layer of die separator. Two weeks later, the esthetics and function of the constructed prosthesis were evaluated. The prosthesis was cemented with zinc phosphate cement. The patient has successfully functioned with



FIGURES 3–4. FIGURE 3. Slightly prepared coronals. FIGURE 4. Cemented prosthesis in place.

the prosthesis with no complications for 2 years (Figure 4).

#### DISCUSSION

In this patient, the type of occlusion and reduced vertical dimension and ridge length presented a dimensional problem for space to accept an implant-supported restoration in the anterior mandible. The available bone for an implant site in many cases can leave much to be desired. Bone volume, bone quality, and ridge length can present the implantologist with a challenge for restorative treatment. Creative but efficacious solutions need to be considered. An up-to-date and pervasive knowledge of the array of implant sizes and shapes is an asset for treatment. Implant diameters are available from 1.8 to 7 mm. Many implantologists believe that a smaller-diameter implant is more desirable than a larger one for reasons of blood supply, that is, larger-diameter implants may impede the blood supply to bone surrounding the implant. Additionally, if an unforeseen bone density or site inadequacy is encountered during the osteotomy of a small-diameter

implant, the use of a slightly larger-diameter implant that is able to attain better initial stability remains an option, if there is adequate space. Consequently, it may be better to have a bias toward a smaller-diameter implant rather than one with a larger diameter. At times, larger-diameter implants may be better suited in the esthetic zone for emergence profile of the crown.

Small-diameter implants have been used for retention of complete maxillary and mandibular overdentures, but there is a dearth of reports for their use in fixed prosthetics.<sup>5</sup>

Although the forces of occlusion are less in the anterior areas of the jaws than in the posterior, the overbite presented by this patient would produce consistently chronic lingually directed off-axial forces. The prosthesis was relieved in centric occlusion to avoid this chronic contact and reduce the resulting-force impact.

Teeth may intrude as much as 250  $\mu\text{m}$ , whereas an osseointegrated implant may move as much as 7  $\mu\text{m}$  in bone. As the teeth move into bone, the opposing teeth may directly contact the prosthesis, and the discrepancy of movement may produce a loss

of integration of the bone-to-implant contact and result in implant failure. There may be room for error in that the opposing teeth also intrude, thus giving the prosthetic implant less of a firm force against it. Therefore, if the teeth adjacent to the supporting implant intrude up to 250  $\mu\text{m}$  and then make contact with the opposing teeth, which can intrude 250  $\mu\text{m}$  as well, the sum of these intrusions may be as much as 500  $\mu\text{m}$  before a solid-contact is made.

Very small-diameter implants may be prone to metal fatigue fracture if the prosthesis is placed in an inappropriate occlusal scheme. However, there is no evidence-based implant-specific concept of occlusion.<sup>6</sup>

#### CONCLUSIONS

Standard available implants may not be appropriate for patients' compromised sites when the patients present for treatment. Knowledge of the available array of implant sizes is an asset for the implantologist. The use of very small- or mini-diameter implants may be advantageous. Sites with inadequate length may be suited

for these implants to provide adequate support for the prosthesis. The available blood supply around and about a small-diameter implant may be better than that of a larger-diameter implant. Sites accepting these small-diameter implants should be of denser bone types I and II.

#### ACKNOWLEDGMENTS

The author appreciates the kind and gentle redaction of Danielle

Green, DMD, and Martie Flanagan, BSRN.

#### REFERENCES

1. Kanie T, Nagata M, Ban S. Comparison of the mechanical properties of 2 prosthetic mini-implants. *Implant Dent.* 2004;13:251-256.
2. Ahn MR, Choi JH, Sohn DS. Immediate loading with mini dental implants in the fully edentulous mandible. *Implant Dent.* 2004;13:367-372.
3. Fritz U, Diedrich P, Kinzinger G, Al-Said M. The anchorage quality of mini-implants towards translatory and extrusive forces. *J Orofac Orthop.* 2003; 64:293-304.
4. Flanagan D. A method for estimating preoperative bone volume for implant surgery. *J Oral Implantol.* 2000; 26:262-266.
5. Mazor Z, Steigmann M, Leshem R, Peleg M. Mini-implants to reconstruct missing teeth in severe ridge deficiency and small interdental space: a 5 year case series. *Implant Dent.* 2004;13:336-341.
6. Kim Y, Oh T-J, Misch CE, Wang H-L. Occlusal considerations in implant therapy: clinical guidelines with biomechanical rationale. *Clin Oral Implants Res.* 2005;16:26-35.