Mandibular Denture Retention: The Mini Implant Solution

Inclusive Magazine: Volume 2, Issue 1

by Stephen A. Wagner,

Melton, DDS

This is a historic moment for dentistry, especially for dentists who provide removable complete dentures in their practice. More patients than ever before are edentulous and in need of complete dentures — and their number is rising. Until recently, these patients were destined to wear prostheses that, in many cases, were unstable or even unwearable. Their ability to chew was limited and, even with clinicians' best efforts, their overall level of satisfaction was disappointing.

That all changed in 1984. We now have dental implants in our armamentarium and proven techniques that allow the average dentist to provide stable, retentive dentures that offer patients a great deal of satisfaction. Previously, the biggest impediment to providing this service was cost: the cost of placement, the cost of the implants themselves and the cost of the final denture. Mini implants have changed all of that, making the implant-retained denture and the satisfaction that comes with it an attainable reality for virtually all patients.[1]

The case in Figure 1 shows three mini implants that were placed 21 years ago. The mandibular overdenture was remade after 10 years of service. The O-ring housings can be seen in the intaglio surface of the denture (*Fig.* 2).

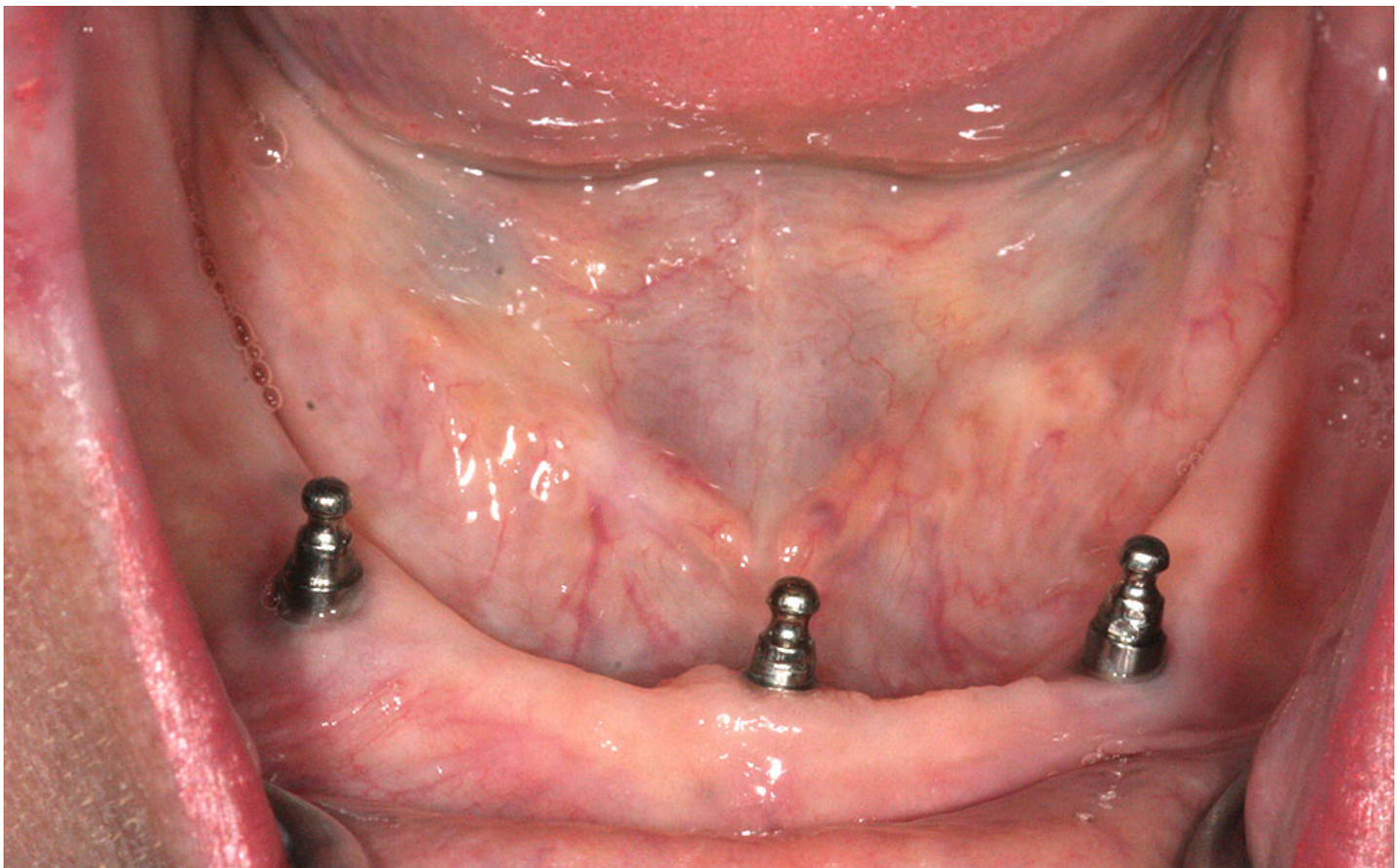

Figure 1: *Case at 21-year follow-up appointment.*

Figure 2: *Intaglio surface of mandibular overdenture.*

What Are Mini Implants?

The FDA granted clearance to standard-diameter implants (implants with a diameter of 3 mm or larger) in 1976. Since then, dental implants have become the foundation of an industry and have been used with great success and increasing sophistication. But even today, implant placement is limited by a lack of bone structure to support the implant body, a lack of attached gingiva in the desired implant area and the cost of the implants themselves.

Enter mini implants. Most mini implants are less than 3 mm in diameter and feature a one-piece construction. They offer either an O-ring retention system or, more recently, proprietary retentive elements such as the ERA® (Sterngold; Attleboro, Mass.) and implant-based Locator® Abutment (Zest Anchors; Escondido, Calif.). The cost per implant is low, ranging in price from about $70 to $150, and many of them come with the retentive fixture included in the cost of the implant.[2]

Mini implants are indicated where bone is limited, especially in the labial-lingual dimension, and when patient cost is an issue. These factors come into play particularly in the severely resorbed anterior edentulous mandible, where use of a traditional implant may require extensive bone modification, such as bone grafting. They must be used in areas with attached mucosa and placed as close to parallel as possible.

Mini implants are indicated where bone is limited, especially in the labial-lingual

dimension, and when patient cost is an issue.

Many companies currently produce mini implants, including Dentatus, Dental Implant Technologies, Implant Direct, OCO Biomedical, IMTEC, Intra-Lock International and Sterngold. And legions of companies are introducing their own mini implant systems every year.

Indications of Mini Implants

In these authors' opinion, mini implants are perfect for retaining mandibular dentures. The implants should be placed mesial to the mental foramina to avoid damage to the mandibular nerve. All implants should be placed through attached gingiva and where parallelism of the implants is possible.

In the maxilla, the use of mini implants is limited primarily by the surgeon's inability to place the implants in a parallel fashion. The anatomy of the edentulous maxilla often requires the implants to be placed with the heads of the implants buccal to the implant body. This compromises the parallel placement of the implants and, in turn, decreases the ability of the restorative dentist to successfully place the O-ring abutments on the retentive element of the implant body. If mini implants with integrated Locator Abutments (OCO Biomedical) are used, the implants can be placed with some degree of nonparallelism, but parallelism of all implants is preferred.

Parallelism Is Key

Mini implants with O-ring abutments must be placed as parallel as possible to obtain effective retention with the denture and to prevent wear of the O-rings over time. This requires a skilled surgeon with impeccable technique, a surgical guide that angles the surgeon's drill in a predetermined direction, or any number of commercial devices designed to obtain parallelism at the time of surgery.

In general, the remaining bone found in the anterior edentulous mandible is conducive to parallel implant placement, but the bone of the residual edentulous maxilla is not. The pattern of bone loss in the maxilla requires that the implants be placed with the heads of the implants labial or buccal to the implant body, resulting in divergent implant placement. In many cases, the retentive O-ring in the denture cannot effectively engage the undercut of the implant, preventing it from becoming an effective retentive feature of the final denture.

Does Diameter Matter?

Narrow-diameter implants were designed for use in residual ridges that were too narrow for regular implants. They were first considered transitional implants that were to be used for temporary stabilization prior to engaging standard abutments. Narrow-diameter implants are also indicated when the bone in the implant site is limited in a buccal-lingual dimension and bone grafting is not possible or permitted.

One theoretical disadvantage of a narrow-diameter implant is the reduction of resistance to occlusal loading. However, in animal studies, the retention of an implant was directly connected to the length of the implant and not to the diameter, suggesting that a narrow-diameter implant of significant length is acceptable in most situations. This is an area that will require further study before a definitive conclusion can be made.

Optimal Number of Implants

Most clinicians feel that four implants placed in the area of tooth #22, #24, #25 and #27 are optimal for retention and stability of a mandibular denture when using mini implants with O-ring retention elements. Two implants do not afford enough retention in most cases. Placing five to six implants in the symphysis often creates a situation where the implants are overcrowded, which prevents effective use of the implants *(Fig. 3)*. Increasing the number of implants often results in a straight-line configuration, thereby creating a fulcrum on which the denture will rotate *(Fig. 4)*.[3]

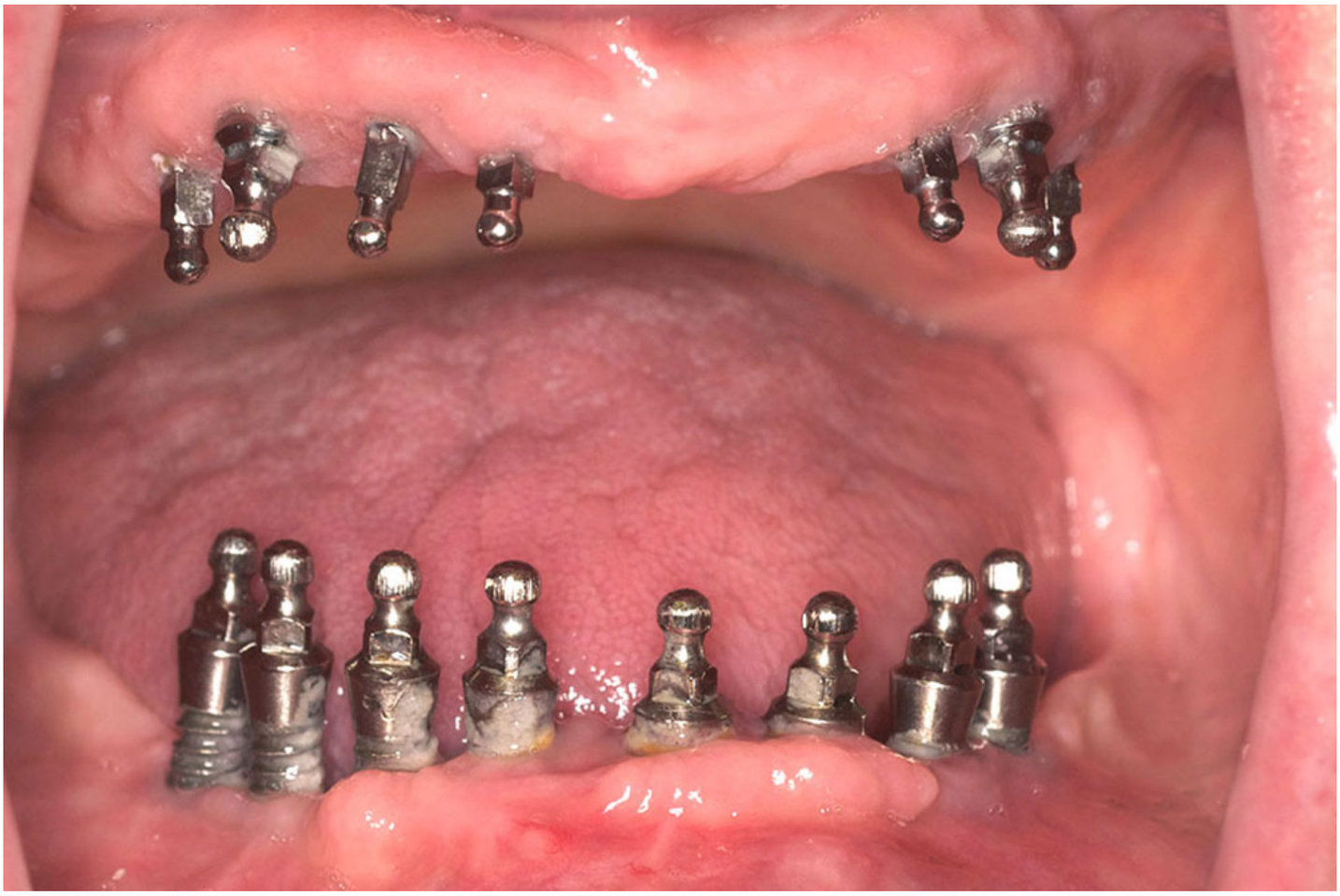

Figure 3: *Too many implants.*

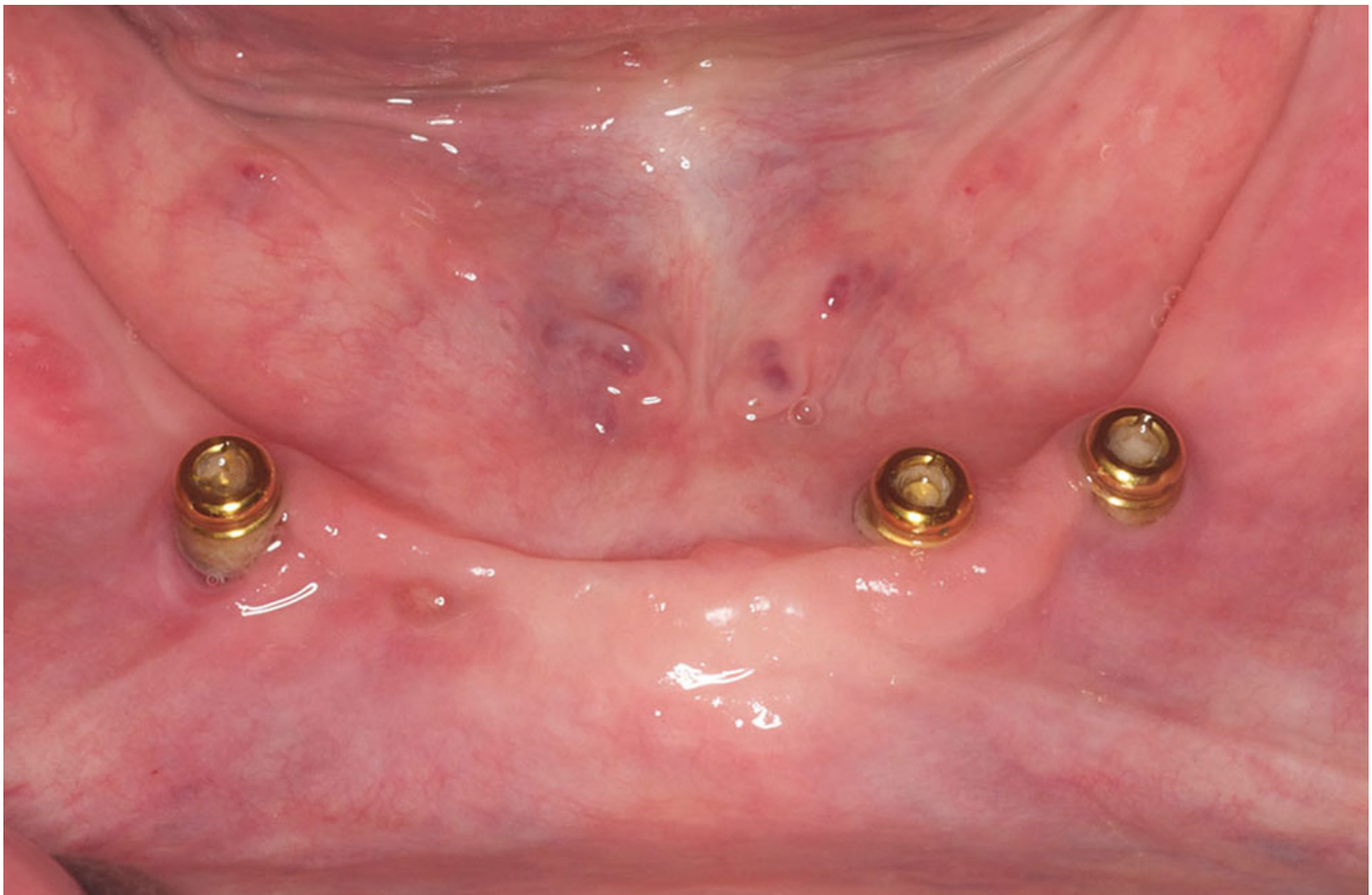

Figure 4: *Implants with no anterior-posterior spread.*

The most effective placement of implants is 5 mm mesial to the mental foramina with two implants placed as anteriorly as possible, without overcrowding. The goal is to place the implants with a maximum anterior-posterior dimension, thereby creating a stable four-implant "table leg" position and providing maximum stability for the implant-supported denture.[4]

Surgical Technique

When placing mini implants in the anterior, the clinician must decide whether to place the implants directly through the mucosa using a "flapless" technique, or to expose the bone of the anterior mandible with a releasing incision and identify the position of the mental foramina and placement of the implants with the basal bone exposed. The flapless technique has the advantage of speed because the time required to lay a flap is eliminated. Most implant companies promote this technique because it relieves any fear associated with the flapping open of the mucosa. It is believed that most general dentists with limited surgical experience will feel more comfortable with this procedure.

The main disadvantage of a flapless technique is that the clinician essentially is performing the procedure blind, which greatly limits his or her ability to evaluate the shape and quality of the existing bone, as well as the final result. Critics often assume that implants placed using a blind technique are not secured in bone at all, but rather placed in bone and in the soft tissue of the lingual floor of the mouth. This would be caused by the implant drill being guided to the lingual by the sloping ridge shape of a residual mandibular alveolus. Regardless, there is no way for the surgeon to evaluate the postoperative placement unless a cone-beam CT (CBCT) scan is taken. A panorex radiograph will not show the labial-lingual positioning of the implants, only their position in the mesiodistal plane.

These authors believe that narrow-diameter implants should be placed using a technique that exposes the body of the anterior mandible, which allows the surgeon to adequately evaluate implant placement. Using a flapless technique should be limited to treating those few patients with an obvious, rounded alveolar ridge with adequate bone or those cases where digital treatment planning and guided surgery are utilized.

Surgical Planning

Surgical planning for mini implants should include the use of a completed denture or trial denture constructed with the proper vertical dimension of occlusion (VDO). An existing denture that does not demonstrate the proper VDO or tooth placement is not sufficient. A radiograph that demonstrates the quality and quantity of bone in the proposed surgical site is required. Depending on the situation, this can be a panographic radiograph or a CBCT scan. It must be understood that the distance between the inferior bony margin of the mandible and the alveolar ridge is increased and cannot be relied upon to give an accurate measurement with most panoramic radiographs. A panorex also does not give any indication of the three-dimensional shape of the mandible. A CBCT typically produces a panoramic radiograph that can be used to accurately measure the inferior and superior length of the anterior mandible and produce cross sections of the anterior mandible, which will demonstrate the lingual concavity of the mandible, if present.

Using a Surgical Stent

A surgical stent can be used to aid the surgeon in determining the position of the mental foramina in cases where a flapless technique will be used. First, an impression of the mandibular alveolar ridge is made. Next, the surgeon attempts to identify the mental foramina by palpation, then transfers that position to the resultant cast. A resin stent is made and two 5 mm ball bearings are inserted into the base to indicate the positions of the mental foramina. A panorex radiograph is then made with the base in place to determine the accuracy of the positioning of the mental foramina. Any discrepancy between the placement of the ball bearings in relation to the radiographic presentation of the mental foramina should be noted. This will enable the surgeon to place the distal implants in the maximum anterior-posterior placement. Utilizing a surgical guide based on a CBCT scan provides another approach to precisely place the implants in a flapless procedure.

Positioning the Implants

The ideal position of a four-implant overdenture is two implants placed as anteriorly as the arch of the mandible permits. Research has shown that the distal implants must be positioned at least 5 mm mesial to the mental foramina. Invading the 5 mm boundary can temporarily injure the mental nerve or cause permanent nerve damage in the area. The anterior implants should be placed in the area of tooth #24 and #25 in such a way that does not position them too close together.

It is not uncommon to find two implants positioned so close together that one implant prevents the attachment of one of the retentive elements. However, the goal is to create the greatest anterior-posterior spread possible for a stable table-leg effect. If the implants are too close to each other in an anterior-posterior position, the denture will rock around a fulcrum created by the implants, which will make the denture feel unstable when seated in the patient's mouth.

Mandible Versus Maxilla

Mini implants, when used to support complete dentures, are more appropriate for the mandible than the maxilla. More specifically, implants have the highest success rate when placed in the alveolar and basal bone of the anterior mandible as determined by the right and left mental foramina. In most cases, the bone is dense and the implants can be placed parallel to one another and still be positioned in solid bone.

This bone differs from the bone of the maxilla. In many cases, the bone of the maxilla is poorly trabeculated, and the structure of the bone dictates that the implants be placed divergent to one another. This divergence can decrease the implants' retentive ability and, in some cases, can prevent the O-ring retainer from attaching to the undercut of the implant body.

Immediate or Delayed Loading?

Many of the implant companies recommend that you immediately load a mini implant at the time of surgery. They reason that an implant placed in solid bone will withstand the retentive stresses created by the prosthesis and will give the patient the immediate satisfaction of a solid denture.

However, these authors recommend delaying the definitive placement of the O-ring retainers and instead to use a soft denture reline material, such as COE-SOFT™ (GC America; Alsip, Ill.), to provisionally retain the denture during the healing phase following implant placement. The O-ring retainers can be placed at a later date following complete healing of the bone and soft tissue, and the patient still will experience the sense of security that comes with an implant-retained denture.

Role of Attached Gingiva

Every implant must be placed through keratinized attached epithelium. Unfortunately, many implants are placed through unattached mucosa (*Fig. 5*). When this occurs, the tissues will not heal properly and will continuously be irritated by the movement of the labial or buccal vestibules. Thus, it is very important that adequate attached gingiva be identified before mini implants are prescribed.[5]

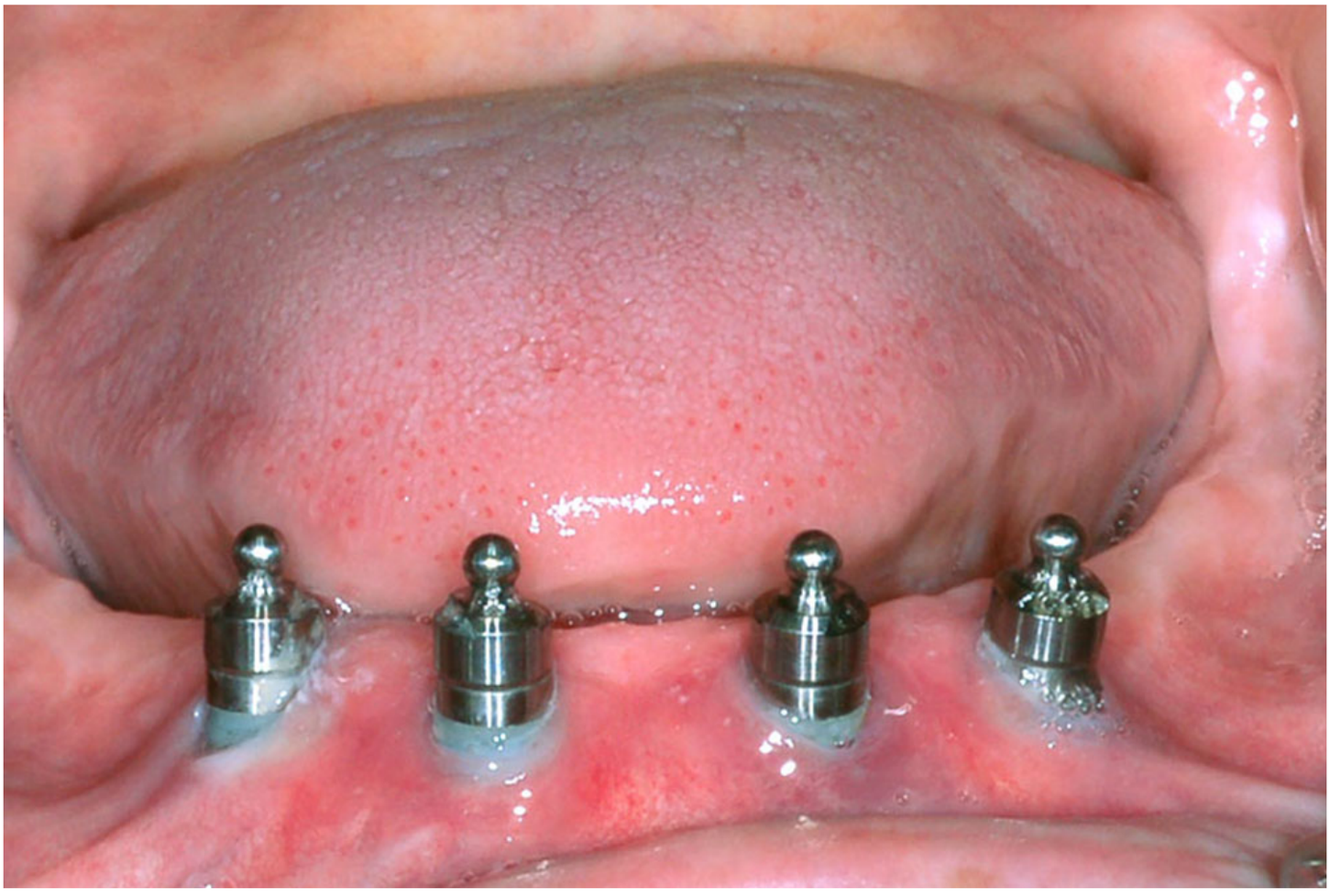

Figure 5: *Implants placed in the mucosa.*

Conclusion

Traditionally reserved for provisional applications during the osseointegration phase of standard-diameter implants, small-diameter or mini implants are quickly proving to be a viable alternative for a variety of permanent applications. Among the most common is the retention of a full denture in the edentulous mandible. With their low cost compared to standard-diameter implants, relatively noninvasive surgical protocol and ability to be prescribed in instances of severely resorbed alveolar ridges, mini implants have resulted in the increased satisfaction of a growing number of denture-wearing patients, and provide fresh hope to those who may confront this challenge in the future.

References

1. *Christensen GJ. The 'mini'-implant has arrived. J Am Dent Assoc. 2006 Mar;137(3):387-90.*
2. *Bryant SR, MacDonald-Jankowski D, Kim K.*

Does the type of implant prosthesis affect outcomes for the completely edentulous arch? Int J Oral Maxillofac Implants. 2007;22 Suppl:117-39.

3. *Bulard RA, Vance JB. Multi-clinic evaluation using mini-dental implants for long-term denture stabilization: a preliminary biometric evaluation. Compend Contin Educ Dent. 2005 Dec;26(12):892-7.*
4. *Rodriguez AM, Orenstein IH, Morris HF, Ochi S. Survival of various implant-supported prosthesis designs following 36 months of clinical function. Ann Periodontol. 2000 Dec;5(1):101-8.*
5. *Nedir R, Bischof M, Szmukler-Moncler S, Belser UC, Samson J. Prosthetic complications with dental implants: from an up-to-8-year experience in private practice. Int J Oral Maxillofac Implants. 2006 Nov-Dec;21(6):919-28.*

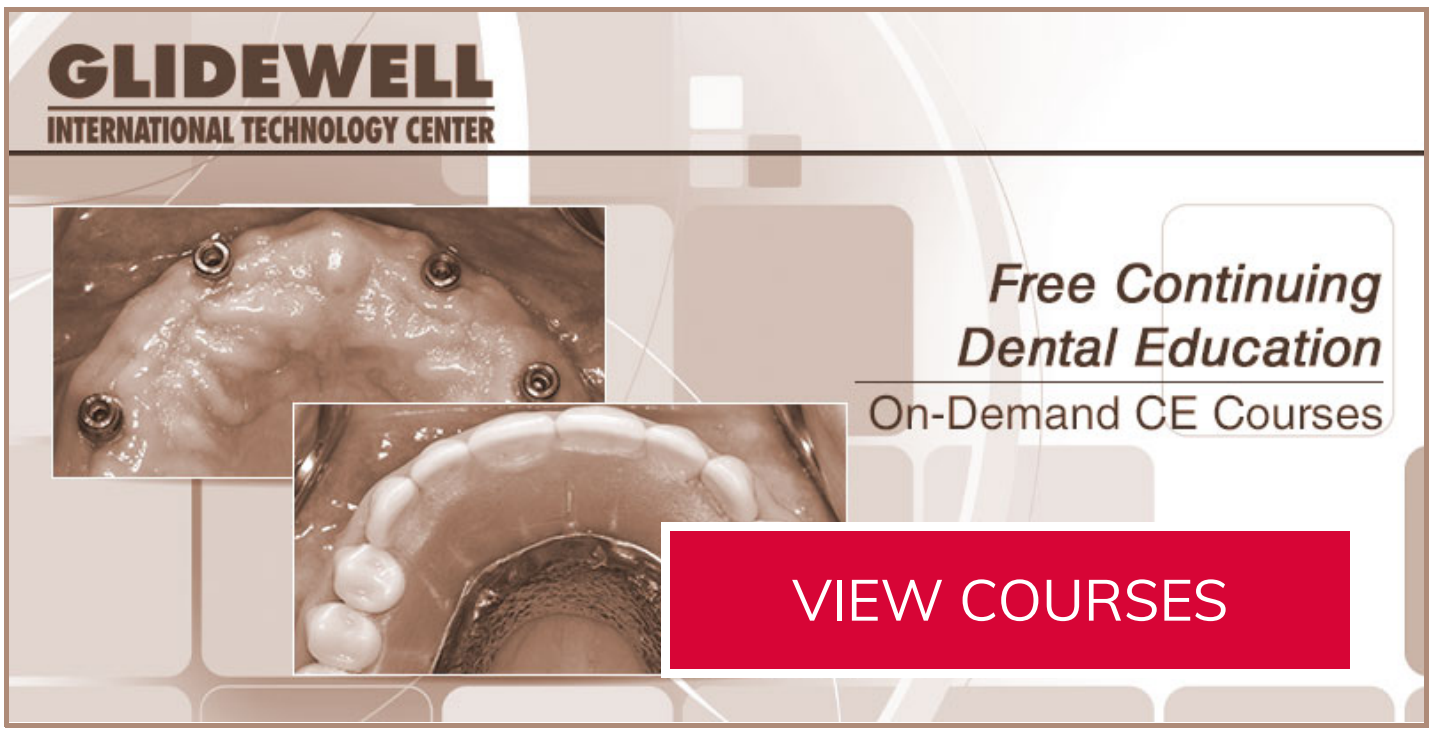

Want to advertise your company here?