

# Mini Dental Implants for the General Dentist: A Novel Technical Approach for Small-Diameter Implant Placement

Todd Ellis Shatkin, DDS  
Private Practice  
Amherst, New York

Samuel Shatkin, DDS, MD  
Private Practice  
Amherst, New York  
Clinical Associate Professor  
of Plastic Surgery  
State University of New York at  
Buffalo Medical School  
Buffalo, New York

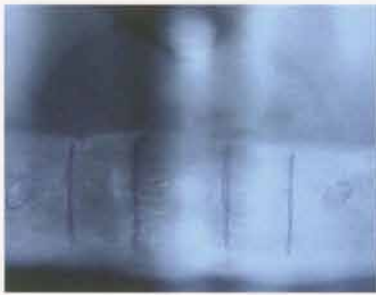
Adam J. Oppenheimer  
Medical Student  
University of Rochester  
Rochester, New York

**Abstract:** *The first dental implants accepted by the profession were devised in the early 1940s as a means to provide a more stable alternative to standard dentures. The surgical placement of these implants, however, was quite invasive and other methods of dental implantation were soon developed. Brånemark revolutionized the field of oral implantology with his discovery that large-diameter, screwlike dental implants could achieve long-term osseointegration, and thus be used to successfully stabilize fixed prostheses. Innovations in dental implantology have continued. One noteworthy development is the Sendax Mini Dental Implant™ (MDI), a minimally invasive, small-diameter endosseous implant comprised of titanium alloy components and the only small-diameter endosseous implant to receive Food and Drug Administration approval for long-term dental prosthesis stabilization. Traditionally, these implants have been used as transitional devices for the stabilization of both fixed and removable dental prostheses. Recent evidence suggests, however, that MDIs may be suitable for long-term use. While follow-up study is needed to determine whether these findings are statistically significant over long durations, the current success has interesting implications for the future uses of MDIs. This article describes a novel technique for the placement of MDIs for long-term prosthetic stabilization. Because the procedure for placing these implants is minimally invasive, they can be used in patients who would normally be considered high-risk (eg, patients on anticoagulant or steroid therapy). In addition, the general dentist can master this technique with minimal training and surgical experience, significantly expanding his or her armamentarium.*

Over the years, dental implantology has undergone a dramatic evolution.<sup>1</sup> Subperiosteal implants were introduced in the 1940s and 1950s.<sup>2</sup> This technique involved two separate surgical procedures and the placement of a cast framework that rested directly on the alveolar ridge. By the 1960s, the use of surgical-blade implants had become popular, largely because of the successes experienced by Linkow.<sup>3</sup> By placing a thin blade through a trough in the alveolar ridge, Linkow was able to stabilize prostheses on abutments protruding through the mucosa. Mandibular staple-type implants were used in the 1970s and 1980s with varying degrees of success.<sup>4</sup> These transosseous implants required an involved surgical procedure, usually including hospitalization and both intraoral and extraoral incisions.

The high complication rate seen among these early techniques<sup>5</sup> was eliminated with the discovery of osseointegration and the development of





**Figure 1—** Panoramic x-ray with implant locations marked and mental foramina outlined.

endosseous dental implants by Brånemark.<sup>6-8</sup> These relatively large-diameter (3.5 mm to 5 mm) screw-type titanium implants enjoyed substantial long-term success during the 1980s and 1990s, and are still the most common type of dental implants used today. Since their inception, endosseous implants have been manufactured by many companies and in many different sizes, with different surface treatments, textures, and variations. Endosseous implants have displayed significant osseointegration over long durations, with stabilities approaching 90% and 100% in the maxilla and mandible, respectively, for some treatment modalities.<sup>9</sup>

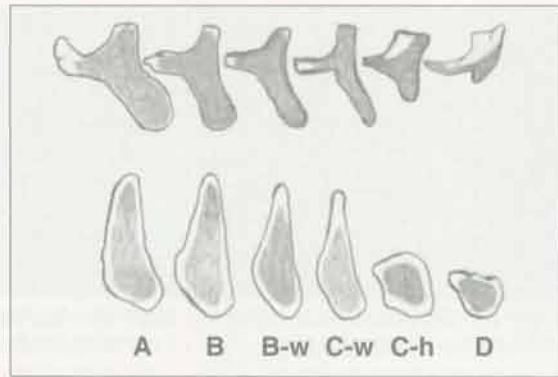
The high complication rate seen among early techniques was eliminated with the discovery of osseointegration and the development of endosseous dental implants.

Victor I. Sendax, DDS, developed the mini dental implant (MDI) system in the mid-1970s. His main purpose was to use mini implants as transitional devices in fixed-bridge salvage cases and also to stabilize loose, periodontally involved teeth.<sup>10</sup> Substantial success in such transitional function has led to the use of small-diameter endosseous implants primarily in the healing phases of conventional larger-diameter endosseous implants.<sup>11,12</sup> In addition to the Sendax Mini Dental Implant™ system<sup>a</sup>, several other mini implant systems have been used in this manner. These systems include the Modular Transitional Implant (MTI) System<sup>b</sup> and the Bicortical Screw® Implant<sup>c</sup>, among others. Although many of the other mini implant systems are well engineered, the IMTEC® MDI system is the only

<sup>a</sup>IMTEC Corporation, Ardmore, OK 73401; 800-879-9799

<sup>b</sup>Dentatus USA, Ltd, New York, NY 10016; 800-323-3136

<sup>c</sup>Bicortical Implants Inc, a division of Oraltronic®, Green Bay, WI 54304; 888-701-1492



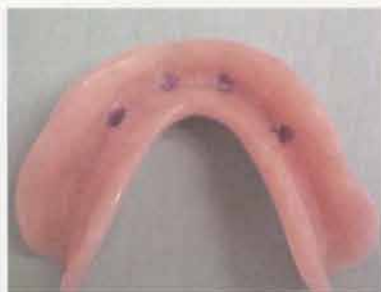**Figure 2—** Misch-Judy classification of bone division. Adapted with permission from CE Misch.<sup>13</sup>

one to achieve Food and Drug Administration (FDA) approval for long-term (nontransitional) use.<sup>13</sup> Recently, the FDA has granted additional approval for long-term use in both fixed and removable prostheses. To date, no other small-diameter endosseous implant system has achieved this recognition.

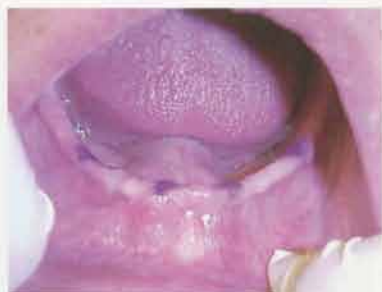A study by Balkin et al<sup>14</sup> provided conclusive histological evidence that MDIs undergo osseointegration comparable to that of large-diameter implants. Given these findings, the researchers concluded that Sendax MDIs were suitable for ongoing applications. A biomechanical study published by Block et al<sup>15</sup> confirmed that the pull-out strength and stress distribution of an implant correlates to the length of the implant, not its diameter, and concluded that small-diameter endosseous implants may be sufficient for prosthetic stabilization if the maximum-length implant is used in the procedure. Shatkin et al are currently assessing a long-term efficacy analysis of the Sendax MDI. This analysis will be based on the 3-year follow-up of approximately 1,000 MDIs placed to stabilize full maxillary and mandibular dentures, fixed bridges, and individual teeth.

There are many advantages to using the novel MDI placement approach outlined in this article. Similar minimally invasive, single-stage surgical procedures for larger-diameter implants have displayed numerous positive results, including reduced bleeding, decreased postoperative discomfort, and, most importantly, shortened healing times.<sup>16,17</sup> Furthermore, the MDI protocol is designed for immediate loading, which provides instant results for the patient.<sup>18,19</sup> In addition, MDIs may be used when there is not sufficient bone for larger-diameter implants, as in cases of reduced ridge width<sup>20,21</sup> and single-tooth replacement.<sup>22</sup>

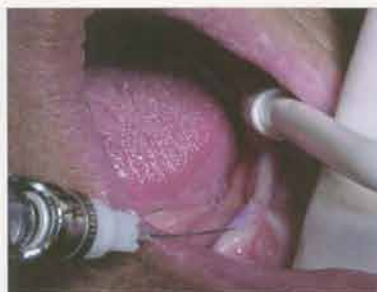



**Figure 3A**—Markings placed in denture with a surgical skin-marking pencil.



**Figure 3B**—Markings transferred to ridge by inserting "marked" denture.



**Figure 4**—Providing infiltration anesthesia at premarked implant position.

Most importantly, the MDI is designed so the general dentist can successfully place the implants after completing a single Academy of General Dentistry–accredited training course,<sup>23,24</sup> thus eliminating the need for a specialist's referral.<sup>25</sup> This final point proves particularly relevant in today's general dental practice.<sup>26</sup> Two computational modeling studies performed by Douglass et al<sup>27,28</sup> predict that the need for prosthodontic therapy will grow because of the increased life expectancy in the population aged 65 and older.<sup>29</sup> General dentists should be aware of this changing demographic, and may wish to offer MDIs to their patients.

## Materials

To successfully incorporate the MDI technique into the dental practice, these materials should be obtained: a minimum of four regular-thread mini-implants and MAX thread mini-implants in each available size; a surgical kit with instrumentation and drills; a high-torque surgical handpiece; a customized informed-consent form; an MDI model; spare O-rings; and ACCESS<sup>®</sup> curved-bristle toothbrushes and oral hygiene care system for postoperative oral hygiene care.<sup>30</sup>

## Methods

### Step One: Candidate Selection

The dentist's first task when considering the MDI procedure is to select suitable candidates. These candidates include, but are not limited to, patients who: have difficulty wearing a lower denture, have a poor alveolar ridge, cannot tolerate a palate appliance on the maxilla, have a large torus palatinus or torus mandibularis, are concerned about denture appliance reliability in social settings, or simply want to feel more confident.<sup>31</sup> Cost allows for the development of a much broader

patient-selection base. Patients who have financial limitations may find the MDI procedure to be an excellent alternative, because the cost is significantly lower than conventional larger-diameter implants.<sup>32</sup> An MDI denture stabilization procedure using four MDIs costs approximately a third as much as conventional implant stabilization.<sup>33</sup>

The MDI protocol is designed for immediate loading, which provides instant results for the patient.

Patients on long-term steroid or anticoagulant therapy are good candidates for MDIs. Case reports<sup>34</sup> and large-scale studies indicate that steroid-induced osteoporosis does not increase the risk for dental-implant failure.<sup>35,36</sup> Furthermore, additional studies by Dao et al<sup>37</sup> indicate that implants are viable in patients with osteoporosis in any form. The minimally invasive MDI technique results in virtually no bleeding.<sup>16,17</sup> A recent study by Herion et al<sup>38</sup> concluded that dental surgery on patients undergoing anticoagulant therapy is safe, provided that well-controlled surgical technique and "careful local hemostasis" is used. In addition, a 60-reference literature review concluded that patients' anticoagulant therapy should be continued during dental procedures, because the interruption of such therapy resulted in a significantly higher morbidity and mortality rate.<sup>39</sup> If an incision or flap is contemplated for these patients, the treating dentist should consult the patient's primary physician before performing surgery.

When the dentist has established that a patient is a good candidate for the MDI procedure, he or she may elect to place the patient on broad-spectrum antibiotic therapy (eg, penicillin, cephalexin, or erythromycin) 1





**Figure 5**—Proper pilot hole depth is measured using an endodontic rubber stopper.

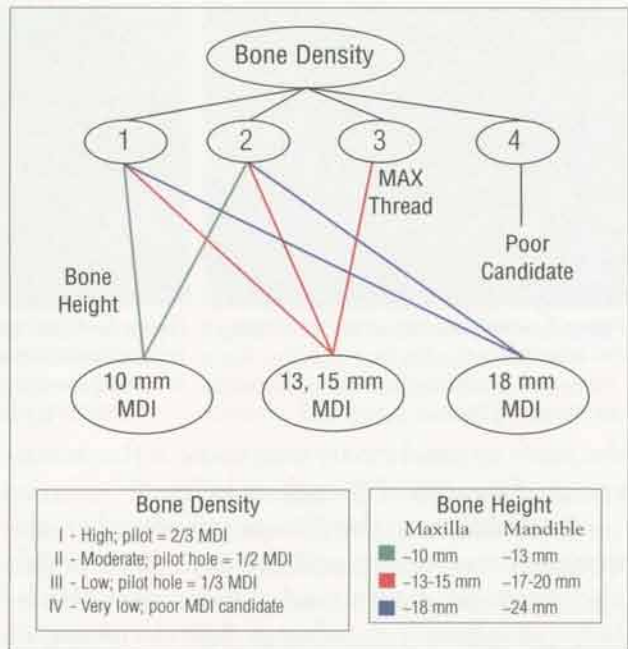
week before the procedure. Evidence suggests that preoperative prophylactic antibiotic treatment can significantly reduce implant failure rates.<sup>40,41</sup>

While some studies have indicated that other dental procedures (eg, extractions) may be performed at the time of implant placement,<sup>42-44</sup> the following technique suggests a mutually exclusive approach for MDI insertion.

### Step Two: Radiographic Planning and Number of Implants

A panoramic x-ray should be performed to locate and outline important anatomical landmarks, as well as to determine bone height, width, and density.<sup>45</sup> In cases where poor ridge width is encountered, the authors recommend that a lateral cephalometric x-ray also be taken. For anterior mandibular denture stabilization cases, the locations of the canine, first bicuspid, and lateral incisors should be marked on the radiograph (Figure 1). Computerized tomography scans may be used for this procedure, but typically are not necessary in such simple treatment modalities.<sup>45</sup>

Next, depending on the size and type of the prosthesis, the number of implants that need to be placed should be determined. Traditionally, four implants are sufficient for full mandibular-denture stabilization, while six implants are recommended to secure a full maxillary denture.<sup>26,46</sup> When replacing individual teeth, one implant for each bicuspid or



**Figure 6**—Algorithm for MDI placement.

anterior tooth (as per traditional implant protocol),<sup>47</sup> and two MDIs for each molar is recommended.<sup>48</sup> When replacing adjoining missing teeth, the authors suggest splinting MDIs together with the fixed restoration whenever possible for increased long-term success.

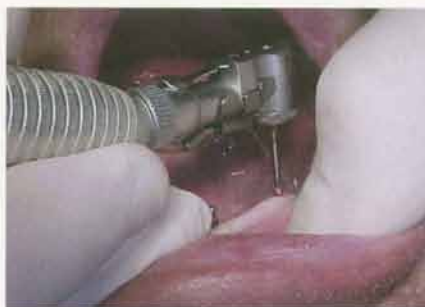### Step Three: Determine Appropriate MDI Size

MDIs are available in 1.8-mm (standard thread) and 2.2-mm (MAX thread) diameters, and in heights of 10 mm, 13 mm, 15 mm, and 18 mm. The clinician should always use the longest MDI possible for the available bone.<sup>15</sup> In Type I or II mandibular bone, standard-thread MDIs with implant lengths of approximately 75% of the total height of the available bone should be used. Penetration through the inferior border of the mandible with the implant must be avoided. In the maxilla and Type III mandibular bone, MAX thread MDIs with implant lengths of approximately 90% of the available bone should be used.<sup>48</sup> Implant lengths must be determined carefully; penetration into

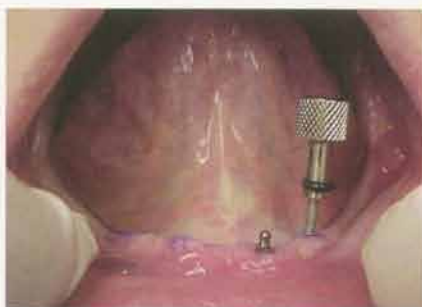**Table 1**—Width Determination Using the Misch-Judy Classification Scheme

Division	Quality	Buccal-Lingual Width	MDI Placement Ramifications
A	Abundant	> 5 mm	None
B	Sufficient	2.5 to 5 mm	None
C-w	Deficient (width)	< 2.5 mm	Incision or mucosal flap
D	Atrophic	Minimal	Not suitable for MDI placement

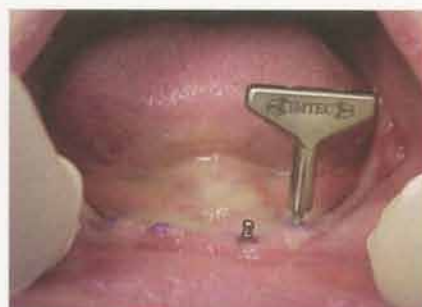



**Figure 7**—Pilot hole placement with copious irrigation.



**Figure 8**—Initial placement of implant with finger driver advanced through the cortical bone layer.



**Figure 9**—Winged thumb wrench for “auto advancement” into medullary cancellous bone.

the sinus or nasal cavity may cause inflammatory complications and implant failure.<sup>49,51</sup>

In addition to the parameters already mentioned (bone height and density), bone width also must be determined. Under the Misch-Judy classification scheme for divisions of available bone in implant dentistry, the edentulous site can be categorized into four divisions, A through D, based on several anatomical considerations: width (w), length (l), height (h), angulation (a), and crown/implant ratio (>1) (Table 1 and Figure 2).<sup>52</sup> When C-w (width-deficient) bone is encountered, an incision or flap is recommended to ensure accurate implant placement. In cases of severely atrophic bone (type D), MDI placement is not recommended.

#### **Step Four: Denture Marking and Transfer (Shatkin Technique)**

This novel approach, developed by the primary author, uses a surgical skin-marking pencil to determine accurate implant placement. For example, in the case of full-mandibular-denture stabilization, the dry denture is marked between the canine and first bicuspid posteriorly and in the area of the lateral incisors anteriorly. Next, the patient's arch is dried and the denture is placed in the patient's mouth. After removing the denture, the marks should transfer to the alveolar ridge. These transfer spots then should be darkened with the skin marker

(Figures 3A and 3B). These marks will guide the remainder of the procedure.

#### **Step Five: Infiltration Anesthesia**

After the marks have been transferred, infiltration anesthesia should be used between the periosteum and the bone.<sup>48</sup> While a local anesthesia block of the inferior alveolar nerve is indicated in most dental procedures to eliminate somatosensory perception of the mandibular anatomy, infiltration anesthesia is preferable when placing MDIs. This approach affords the patient continued sensation of the inferior alveolar nerve, which in turn allows the patient to offer feedback during the procedure, and thus decreases the chance of potential nerve paresthesia.<sup>53</sup> Local anesthetic is injected on the mark, buccal to the mark, and lingual to the mark at each location (Figure 4).

#### **Step Six: Creation of Pilot Hole**

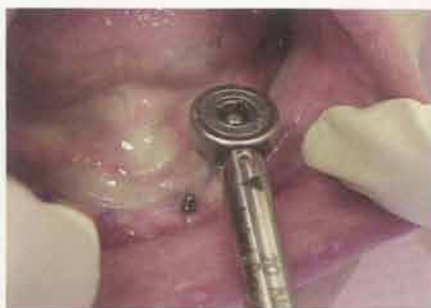Per standard operative protocol, care should be taken to use sterile surgical techniques.<sup>54</sup> Appropriate tissue preparation (using betadine) or preoperative oral rinsing (with chlorine dioxide), and surgical draping should be used.

After an endodontic rubber stopper is placed on the pilot drill as a depth gauge (Figure 5), the dentist drills to the proper depth (Table 2 and Figure 6), carefully measuring two thirds, one half, or one third the length of MDI to be

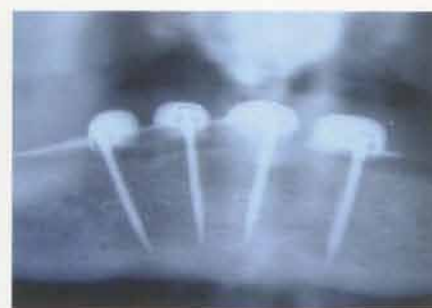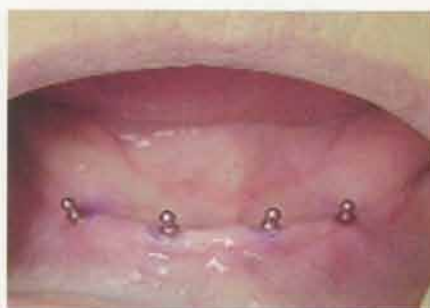**Table 2—Density-Pilot Hole Correlation**

Density	Description	Pilot Hole	Thread
I	High-density bone — highly trabeculated	2/3	Standard
II	Moderate-density bone — classic mandibular	1/2	Standard
III	Low-density bone — cancellous, spongy	1/3	MAX
IV	Very low-density bone	Not suitable for MDI placement	





**Figure 10**—Ratchet driver for final insertion against resistance (used for final few turns only).



**Figures 11 and 12**—Postoperative photograph and x-ray of insertion of four lower MDI implants.

placed, depending on the patient's bone-density type. When Type III bone is encountered, an MDI MAX thread implant should be used.<sup>48</sup> This will increase the surface area available for osseointegration of the implant. When Type IV bone is encountered, MDIs are contraindicated, because very low-density bone is a risk factor for implant failure.<sup>55</sup>

The pilot drill is used to carefully puncture through the tissue down to the bone, without drill rotation. After locating the bone surface, with the drill on, a pilot hole is drilled with a tapping motion using copious irrigation (Figure 7). The drill must be kept at the proper angulation in the bone. Improper drill angulation can result in limited prosthetic options.<sup>56</sup>

Overinstrumentation of the receptor site must be avoided. As previously cited, Balkin et al<sup>14</sup> established that MDIs undergo osseointegration comparable to that of large-diameter implants. This process requires several months of implant–bone interface. Additionally, these researchers discovered that the implants were able to be loaded immediately if they were “turned into bone through a starting opening but not a prepared site.”<sup>14</sup> In this manner, the MDI acts much like an osteotome. By increasing peri-implant bone density, this “auto-advance” technique allows MDIs to sustain an immediate functional load. It is, therefore, a sine qua non of this procedure. In the event that a pilot hole is accidentally drilled to the full length of the implant, the MDI can be used only as a transitional implant, and will not be suitable for ongoing or long-term stabilization of the prosthesis.<sup>48</sup>

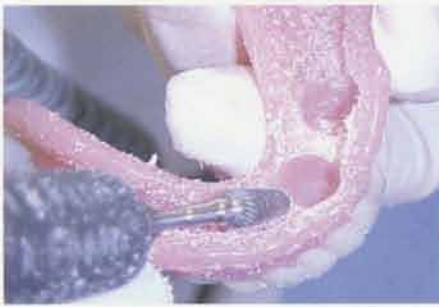### **Step Seven: Implant Insertion**

The provided plastic cap is used to deliver the implant to the site. The implant must not be touched under any circumstances, because

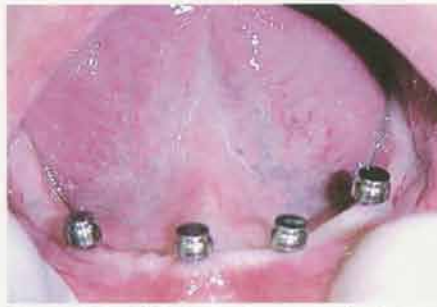this will contaminate the sterile implant surface. Using the provided plastic cap, the implant is inserted into the pilot opening through the gingiva to the bone and rotated clockwise with strong, downward pressure until firm bony resistance is met.<sup>48</sup> Care should be taken to insert the MDIs properly, avoiding angulation toward the roots of adjacent teeth.<sup>56</sup>

Insertion of the mini-implant with the titanium finger driver should be continued as far as the clinician can go (Figure 8), then the winged thumb wrench should be used for additional leverage (Figure 9). At this point the implant will “auto-advance” as it is turned.<sup>14</sup> The winged thumb wrench should be turned slowly, until firm, bony resistance is met. If the implant is turned too fast at this point, it may fracture. If the mini-implant can be completely inserted with the winged thumb wrench, it should continue to be turned until all of the threads are subgingival. If too much resistance is met, as is often the case in the extremely dense bone of the anterior mandible, the ratchet wrench can be used for the final few turns (Figure 10). The ratchet wrench should be used only in this situation (ie, for the final few turns of the implant).<sup>48</sup> Very slow incremental turns with short rests between turns will allow full implant insertion without bone stripping or implant fracture.<sup>57</sup> If very heavy resistance is met, the implant should be backed out immediately and the pilot hole made deeper, or a shorter implant should be used. The ratchet's rotation should never be forced, or the implant will snap at the neck. Vertical pressure should be constantly applied on the head of the ratchet wrench in the direction of desired insertion. Complete the insertion of all MDIs—one at a time—so that no threads are supragingival. Approximately 1 mm to 1.5 mm of the square neck portion should remain above the mucosa (Figures 11 and 12).





**Figure 13**—Laboratory bur used to drill holes in denture at previously marked positions.



**Figure 14**—MDI O-ring housings in place; blockout shims on implants.



**Figure 15**—Holes filled with autocuring attachment resin.

### **Step Eight: Denture Placement and Prosthetic Technique**

As a general rule, denture positioning should be as close to the original plan as possible. With a pear-shaped, denture-adjustment laboratory bur, holes should be placed in the patient's denture at the premarked locations (Figure 13). O-ring housing abutments should be placed on the implant O-balls (Figure 14). The patient's denture should then be tried in for full seating. This should be a passive seating of the denture. Blockout shims should be placed on the MDIs to prevent the acrylic or resin from locking onto the implant surface during removal. The holes in the denture should then be filled with implant housing-attachment resin or pink cold-cure acrylic (Figure 15). Before the acrylic or resin sets, the denture should be placed on the O-ring housings and seated firmly. The patient should bite down to seat the denture and hold the bite for about 3 to 5 minutes, until the resin or acrylic sets. Next, the denture appliance should be removed and the security of the housing in the denture should be assessed (Figure 16). Flowable resin (light-cured), cold-cured acrylic, or cyanoacrylate should be added if any housings are loose. Excess material should be trimmed and the tissue surface of the denture should be smoothed to avoid creating sore spots. The borders of the denture should be shortened 1 mm to 2 mm to avoid causing sore areas in the vestibule.<sup>48</sup>

### **Step Nine: Postoperative Instructions**

The patient should be scheduled for an appointment 24 hours after placement. He or she should be instructed to ice the affected area extraorally during the first 24 hours and rinse with warm salt water several times during this period. Most importantly, the patient should wear his or her denture continuously for

the first 24 hours. The patient should be told not to remove the appliance, even if it is a removable partial denture, until the dentist has had an opportunity to inspect it at the follow-up appointment. This will allow the tissue around the MDIs to heal without advancing around the implant necks and O-balls.

### **Step Ten: Follow-up**

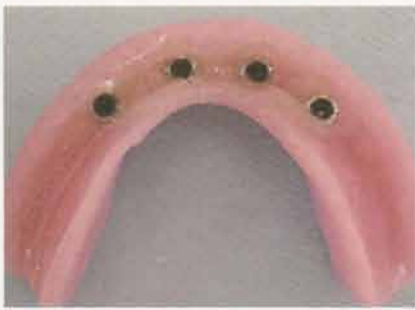At this postoperative appointment, the patient's occlusion should be checked and the denture should be adjusted. The patient should be instructed to wear the denture as much as possible until his or her next appointment. It is very important that the dentist see the patient at 24 hours, 3 days, and 1 week postoperatively, and to be available at other times as needed for the patient during the first few weeks after the MDI procedure.<sup>58</sup> Frequently, additional adjustments are necessary during this critical period.<sup>59</sup>

The dentist should see the patient again every 3 months for the first year, and every 6 months for the second year and thereafter. The patient should be fully informed of the necessity for strict adherence to this postoperative examination period.<sup>60,61</sup> The patient should also be educated on proper oral hygiene care and have recall prophylaxis appointments, including professional cleaning of the prosthesis and implants. Careful attention should also be directed to the integrity of the O-rings during this time. Typically, the O-rings need to be replaced every 12 months.

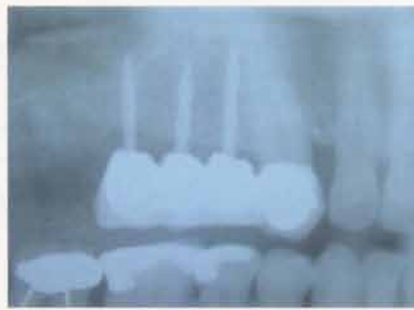### **Other Applications of the MDI System**

The efficacy of the small-diameter endosseous implants for transitional use has been well established.<sup>10-12</sup> Bulard<sup>62</sup> describes his experiential success for many of the long-term stabilization procedures traditionally reserved for the more invasive, large-diameter implants,





**Figure 16**—The denture is removed from the mouth with the O-rings in place.



**Figure 17**—Fixed denture 14 months after initial placement. Note the excellent bone condition around the implants.

including: long-term stabilization of fixed and removable prostheses (Figure 17); fixed bridge salvage cases (when an abutment tooth is lost or broken); the retention of partial dentures, Cusil® dentures<sup>d</sup>, and wireless partials; for single-tooth replacement (recommended only for teeth with mild occlusal forces, ie, lateral and central incisors); for distal abutment work (replacement of free-end saddle partial dentures with fixed crown-and-bridge work); and for pier abutments (to break up a long-span bridge and provide additional support). Continuing clinical trials are under way for these treatment modalities.

## Conclusion

The advantages of small-diameter endosseous implants over their large-diameter counterparts are clear. While continued use of large-diameter implants certainly will be necessary and preferred for many cases, the recent FDA approval of the Sendax Mini Dental Implant™ for long-term use has provided a significant clinical alternative. Using the technical procedure outlined in this article, the authors' practices have experienced considerable success. A preliminary statistical examination of implants placed with this technique has yielded results comparable to those of large-diameter implants. These results—in addition to those found in previous MDI osseointegration and biomechanical studies—point to the potential, successful long-term use of the MDI. This potential has profound implications, especially when considering that the placement protocol has been designed expressly for the general dentist, with minimal surgical experience necessary. By attending a single mini-residency or seminar training program, general dentists should be capable of placing MDIs and, thus, able to introduce mini-implant dentistry into their daily practice.<sup>62</sup>

<sup>d</sup>National Dentex Corp, Wayland, MA 01778; 508-358-4422

## Disclosure

Dr. Todd Shatkin is a paid consultant to and provides seminar course instruction and mini-residency programs on behalf of IMTEC® Corporation on the use of the Sendax MDI™ system.

## References

1. Taylor TD, Agar JR. Twenty years of progress in implant prosthodontics. *J Prosthet Dent.* 2002;88:89-95.
2. Dahl G. History of intramucosal inserts. *J Oral Implantol.* 1991;17:440.
3. Linkow L. Tuber blades. *J Oral Implantol.* 1980;9:190-216.
4. Meijer HJ, Van Oort RP, Raghoobar GM, et al. The mandibular staple bone plate: a long-term retrospective evaluation. *J Oral Maxillofac Surg.* 1998;56:141-146.
5. Simons AM, Hanks SY. Correction of denture fracture secondary to overextended transosteal pins in a staple implant. *J Oral Implantol.* 1993;19:43-46.
6. Brånemark PI. Osseointegration and its experimental background. *J Prosthet Dent.* 1983;50:399-410.
7. Hansson HA, Albrektsson T, Brånemark PI. Structural aspects of the interface between tissue and titanium implants. *J Prosthet Dent.* 1983;50:108-113.
8. Brånemark PI, Hansson BO, Adell R, et al. Osseointegrated implants in the treatment of the edentulous jaw. Experience from a 10-year period. *Scand J Plast Reconstr Surg.* 1977;16(suppl):1-132.
9. Adell R, Lekholm U, Rockler B, et al. A 15-year study of osseointegrated implants in the treatment of the edentulous jaw. *Int J Oral Surg.* 1981;10:387-416.
10. Sendax VI. Mini-implants as adjuncts for transitional prostheses. *Dent Implantol Update.* 1996;7:12-15.
11. el Attar MS, el Shazly D, Osman S, et al. Study of the effect of using mini-transitional implants as temporary abutments in implant overdenture cases. *Implant Dent.* 1999;8:152-158.
12. Petrunaro PS, Windmiller N. Using transitional implants during the healing phase of implant reconstruction. *Gen Dent.* 2001;49:46-51.
13. Jameson J. The Jameson files: mini-dental implants. *Dent Econ.* May 2001.
14. Balkin BE, Steflik DE, Naval F. Mini-dental implant insertion with auto-advance technique for ongoing applications. *J Oral Implantol.* 2001;27:32-37.
15. Block MS, Delgado A, Fontenot MG. The effects of diameter and length of hydroxyapatite-coated dental implants on ultimate pullout force in dog alveolar bone. *J Oral Maxillofac Surg.* 1990;48:174-178.
16. Campelo LD, Camara JR. Flapless implant surgery: a 10-year clinical retrospective analysis. *Int J Oral Maxillofac Implants.* 2002;17:271-276.
17. Gibney JW. Minimally invasive implant surgery. *J Oral Implantol.* 2001;27:73-76.
18. Horiuchi K, Uchida H, Yamamoto K, et al. Immediate loading of Brånemark system implants following place-



- ment in edentulous patients: a clinical report. *Int J Oral Maxillofac Implants*. 2000;15:824-830.
19. Porter JM. Same-day restoration of mandibular single-stage implants. *J Indiana Dent Assoc*. Fall 2002;81:22-25.
  20. Ibbott CG, Kovach R, Carlson-Mann LD. Indications for small diameter screw-type implants. *J Can Dent Assoc*. 1996;62:795-797.
  21. Barber HD, Seckinger RJ. The role of the small-diameter dental implant: a preliminary report on the Miniplant® system. *Compend Contin Educ Dent*. 1994;15:1390-1392.
  22. Vigolo P, Givani A. Clinical evaluation of single-tooth mini-implant restorations: a five-year retrospective study. *J Prosthet Dent*. 2000;84:50-54.
  23. Andersson B, Odman P, Lindvall AM, et al. Surgical and prosthodontic training of general practitioners for single tooth implants: a study of treatments performed at four general practitioners' offices and at a specialist clinic after 2 years. *J Oral Rehabil*. 1995;22:543-548.
  24. DeBruyn H, Linden U, Collaert B, et al. Quality of fixed restorative treatment on Brånemark implants. A 3-year follow-up study in private dental practices. *Clin Oral Implants Res*. 2000;11:248-255.
  25. Eckert SE, Koka S, Wolfinger G, et al. Survey of implant experience by prosthodontists in the United States. *J Prosthodont*. 2002;11:194-201.
  26. Henry PJ. Future therapeutic directions for management of the edentulous predicament. *J Prosthet Dent*. 1998;79:100-106.
  27. Douglass CW, Watson AJ. Future needs for fixed and removable partial dentures in the United States. *J Prosthet Dent*. 2002;87:9-14.
  28. Douglass CW, Shih A, Ostry L. Will there be a need for complete dentures in the United States in 2020? *J Prosthet Dent*. 2002;87:5-8.
  29. Christensen GJ. Are prosthodontics a vital part of dentistry? *J Am Dent Assoc*. 2002;133:647-648.
  30. Sendax IMTEC® Mini Dental Implants [materials list]. Ardmore, Okla: IMTEC® Corporation; 1999.
  31. Sendax VI. Mini implant strategy offers a broad range of uses. *Dent Today*. 1995;14.
  32. Madow M. Adventures in dentures. *The Richards Report*. 2002;10:1-3.
  33. Gillespie ES. How to profit from...implants. *Dent Econ*. Oct 2000.
  34. Cranin AN. Endosteal implants in a patient with corticosteroid dependence. *J Oral Implantol*. 1991;17:414-417.
  35. Smith RA, Berger R, Dodson TB. Risk factors associated with dental implants in healthy and medically compromised patients. *Int J Oral Maxillofac Implants*. 1992;7:367-372.
  36. Fujimoto T, Niimi A, Sawai T, et al. Effects of steroid-induced osteoporosis on osseointegration of titanium implants. *Int J Oral Maxillofac Implants*. 1998;13:183-189.
  37. Dao TT, Anderson JD, Zarb GA. Is osteoporosis a risk factor for osseointegration of dental implants? *Int J Oral Maxillofac Implants*. 1993;8:137-144.
  38. Herion F, David JL, Boxho P, et al. Anti-vitamins K and oral surgery: the end of their prohibition? [in French]. *Rev Med Liege*. 2002;57:330-333.
  39. Wahl MJ. Myths of dental surgery in patients receiving anticoagulant therapy. *J Am Dent Assoc*. 2000;131:77-81.
  40. Laskin DM, Dent CD, Morris HF, et al. The influence of preoperative antibiotics on success of endosseous implants at 36 months. *Ann Periodontol*. 2000;5:166-174.
  41. Dent CD, Olson JW, Farish SE, et al. The influence of preoperative antibiotics on success of endosseous implants up to and including stage II surgery: a study of 2,641 implants. *J Oral Maxillofac Surg*. 1997;55(12 suppl 5):19-24.
  42. Beagle JR. Immediate placement/immediate load: a single-tooth case study utilizing the ITI dental implant system. *J Indiana Dent Assoc*. Fall 2002;81:17-21.
  43. Kosinski TE, Skowronski R Jr. Immediate implant loading: a case report. *J Oral Implantol*. 2002;28:87-91.
  44. Maksud MA. Immediate implants in fresh posterior extraction sockets: report of two cases. *J Oral Implantol*. 2001;27:123-126.
  45. Garg AK, Vicari A. Radiographic modalities for diagnosis and treatment planning in implant dentistry. *Implant Soc*. May/June 1995;5:7-11.
  46. Henry PJ. A review of guidelines for implant rehabilitation of the edentulous maxilla. *J Prosthet Dent*. 2002;87:281-288.
  47. Henry PJ. Tooth loss and implant replacement. *Aust Dent J*. 2000;45:150-172.
  48. Sendax IMTEC® Mini-Dental Implants [videotape]. Ardmore, Okla: IMTEC® Corporation; 1999.
  49. Ueda M, Kaneda T. Maxillary sinusitis caused by dental implants: report of two cases. *J Oral Maxillofac Surg*. 1992;50:285-287.
  50. Quiney RE, Brimble E, Hodge M. Maxillary sinusitis from dental osseointegrated implants. *J Laryngol Otol*. 1990;104:333-334.
  51. Gumru O, Kocak H. Acute maxillary sinusitis from a dental implant: an unusual case report. *J Marmara Univ Dent Fac*. 1996;2:551-553.
  52. Misch CE. Divisions of available bone in implant dentistry. *Int J Oral Implantol*. 1990;7:9-17.
  53. Heller AA, Shankland WE 2nd. Alternative to the inferior alveolar nerve block anesthesia when placing mandibular dental implants posterior to the mental foramen. *J Oral Implantol*. 2001;27:127-133.
  54. Friberg B. Sterile operating conditions for the placement of intraoral implants. *J Oral Maxillofac Surg*. 1996;54:1334-1336.
  55. Jaffin RA, Berman CL. The excessive loss of Brånemark fixtures in type IV bone: a 5-year analysis. *J Periodontol*. 1991;62:2-4.
  56. Lewis S, Avera S, Engleman M, et al. The restoration of improperly inclined osseointegrated implants. *Int J Oral Maxillofac Implants*. 1989;4:147-152.
  57. Rueggeberg FA. University of Georgia Medical College, Augusta—Torque & Dynamic Loading Tests—IMTEC 3710HA Dental Implants and Sendax MDI mini dental implants. September 2001.
  58. Walton JN, MacEntee MI. A retrospective study on the maintenance and repair of implant-supported prostheses. *Int J Prosthodont*. 1993;6:451-455.
  59. Walton JN, MacEntee MI. Problems with prostheses on implants: a retrospective study. *J Prosthet Dent*. 1994;71:283-288.
  60. Miyata H. Osseointegrated implants in clinical dentistry. Follow-up maintenance phase [in Japanese]. *Shigaku*. 1989;77(SPEC):1235-1245.
  61. Yi SW, Ericsson I, Kim CK, et al. Implant-supported fixed prostheses for the rehabilitation of periodontally compromised dentitions: a 3-year prospective clinical study. *Clin Implant Dent Relat Res*. 2001;3:125-134.
  62. Bulard RA. Mini Dental Implants: Enhancing patient satisfaction and practice income. *Dent Today*. 2001;20:1-5.



# Quiz

Dental Learning Systems provides 2 hours of Continuing Education credit for those who wish to document their continuing education endeavors. Participants are urged to contact their state registry boards for special CE requirements. To receive credit, complete the enclosed answer sheet and mail it, along with a check for \$20, to Dental Learning Systems, 405 Glenn Drive, Suite 4, Sterling, VA 20164-4432, for processing. You may also phone your answers in to 888-596-4605, or fax them to 703-404-1801. Participants with a score of at least 70% will receive a certificate documenting completion of the course. For more information, call 800-926-7636, ext 180. Program #: D497

## CE—Drs. English and Bohle

---

1. What characteristics should diabetic patients exhibit to be recommended for implant treatment?
  - a. They should be in metabolic control.
  - b. They should have antibiotic protection.
  - c. They should avoid smoking.
  - d. all of the above
2. When placing in which of the following can longer implants be used without modification?
  - a. temporal rim
  - b. superior orbital rim
  - c. zygomatic arch
  - d. maxillary sinus
3. Several studies found that small titanium screws were able to function as rigid osseous anchorage against orthodontic load for 3 months when the healing period was how long?
  - a. immediate
  - b. less than 3 weeks
  - c. 6 weeks
  - d. 3 to 4 months
4. How many MDIs equal one traditional implant in surface area?
  - a. 0.5
  - b. 1
  - c. 2.5
  - d. 4
5. There has been a suggested critical threshold of which of the following, that above which fibrous encapsulation dominates over osseointegration?
  - a. penetration
  - b. implant width
  - c. implant surface area
  - d. micromotion
6. Failure point tests on MDIs found the average fracture point of all MDIs to be:
  - a. 35.7 Ncm.
  - b. 47.3 Ncm.
  - c. 64.2 Ncm.
  - d. 74.8 Ncm.
7. Failed sites in D1 bone can be re-entered after healing for how long?
  - a. immediately
  - b. 3 to 4 weeks
  - c. 3 to 4 months
  - d. never
8. Too much lingual inclination can cause what problems?
  - a. floor of the mouth penetration
  - b. O-ring housings being outside of the lingual flange contour
  - c. unacceptable path of insertion for the denture
  - d. all of the above
9. What does the vertical movement of the O-ring housing accommodate?
  - a. gingival sulcus flushing with saliva
  - b. mucosal compression under forces of mastication
  - c. acrylic or porcelain denture teeth
  - d. space for the silane coupling agent
10. Occlusal forces on a cusp tip of a first molar can reach:
  - a. 25,000 psi.
  - b. 50,000 psi.
  - c. 75,000 psi.
  - d. 100,000 psi.

*Dental Learning Systems is an ADA CERP Recognized Provider*

*Academy of General Dentistry, Approved PACE Program Provider  
FAGD/MAGD Credit 7/18/1990 to 12/31/2005*

This supplement to *The Compendium*® was supported by an unrestricted educational grant from the IMTEC® Corporation. To order additional copies call 800-926-7636, x180. D497